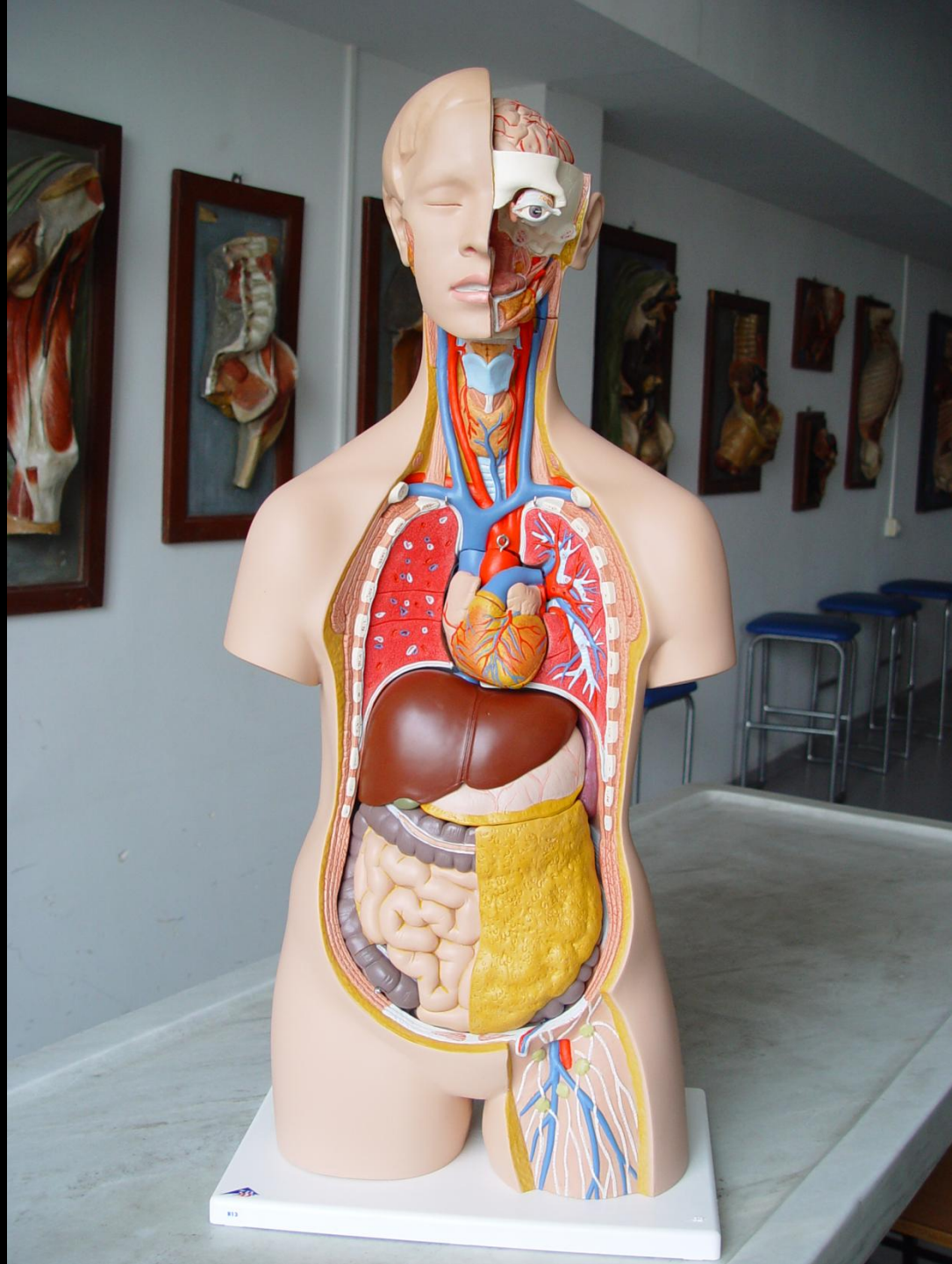

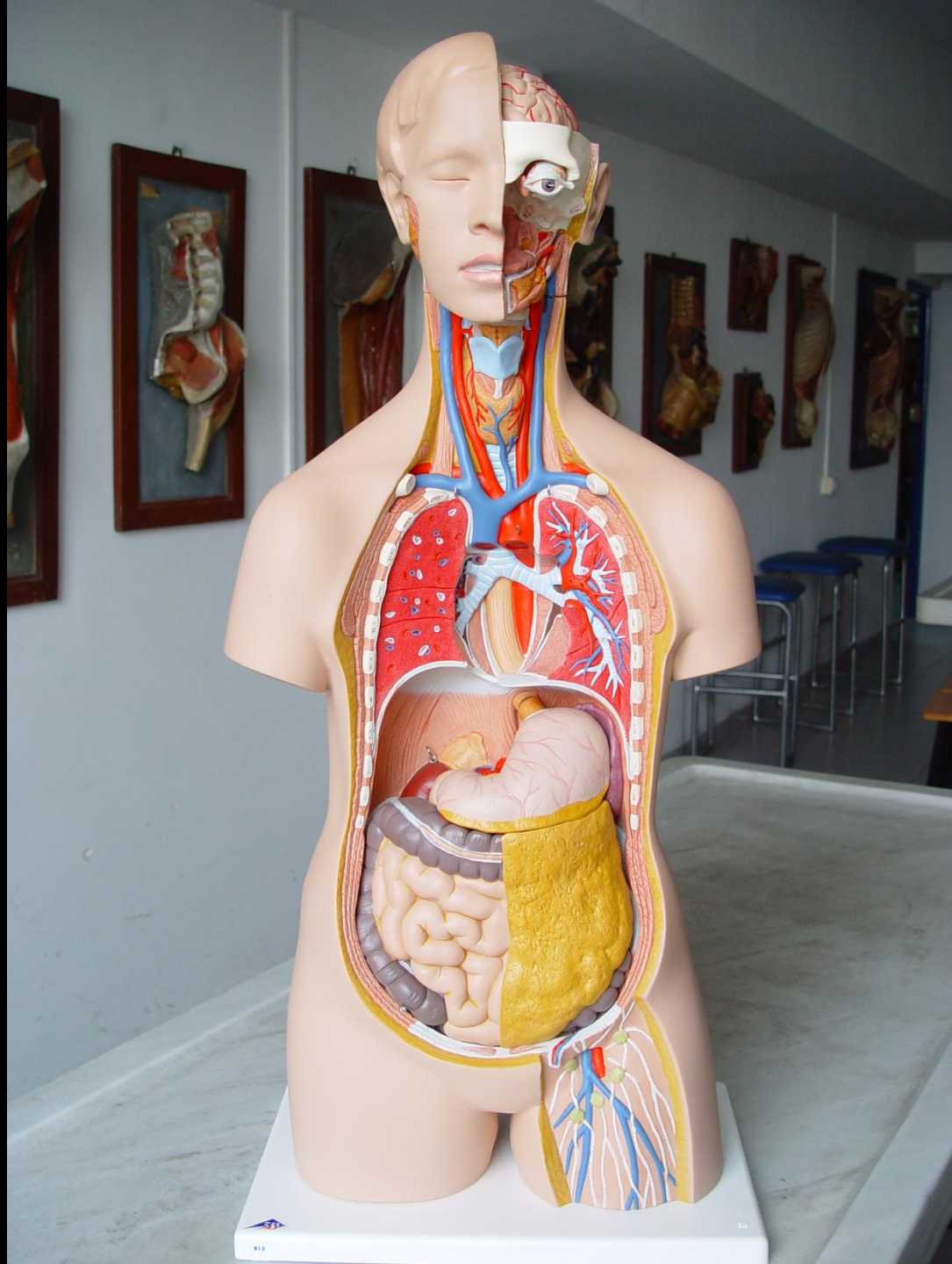
AD Pract 10 A

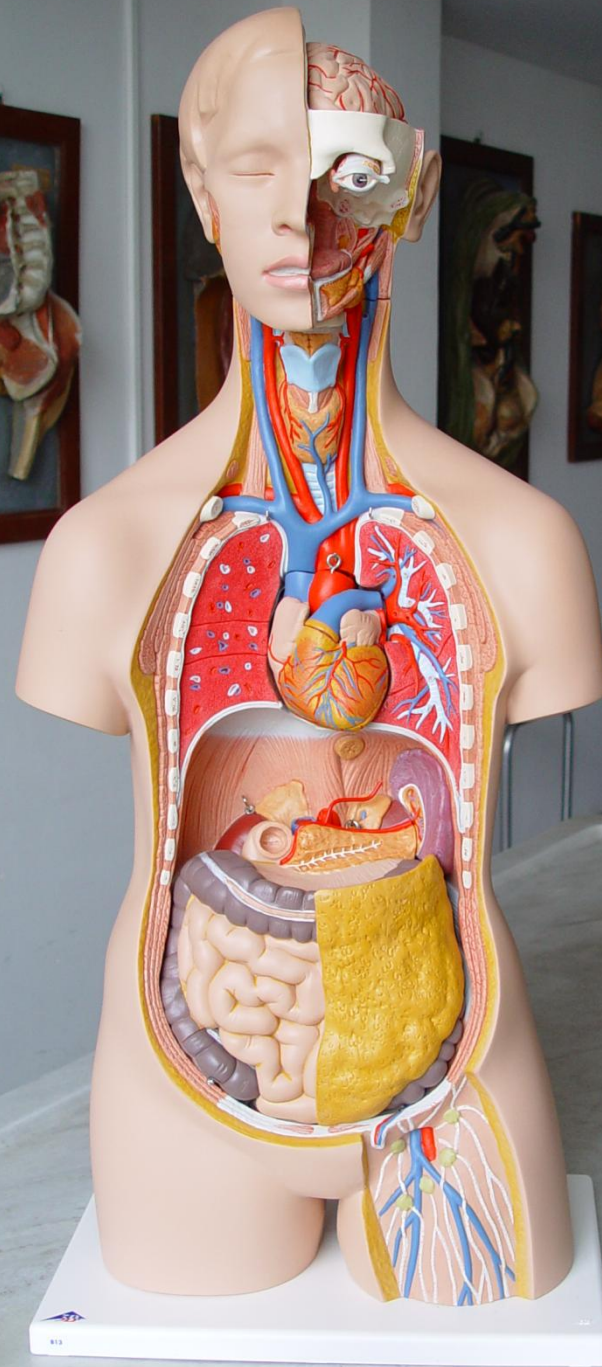
Retroperitoneo y vísceras pelvianas

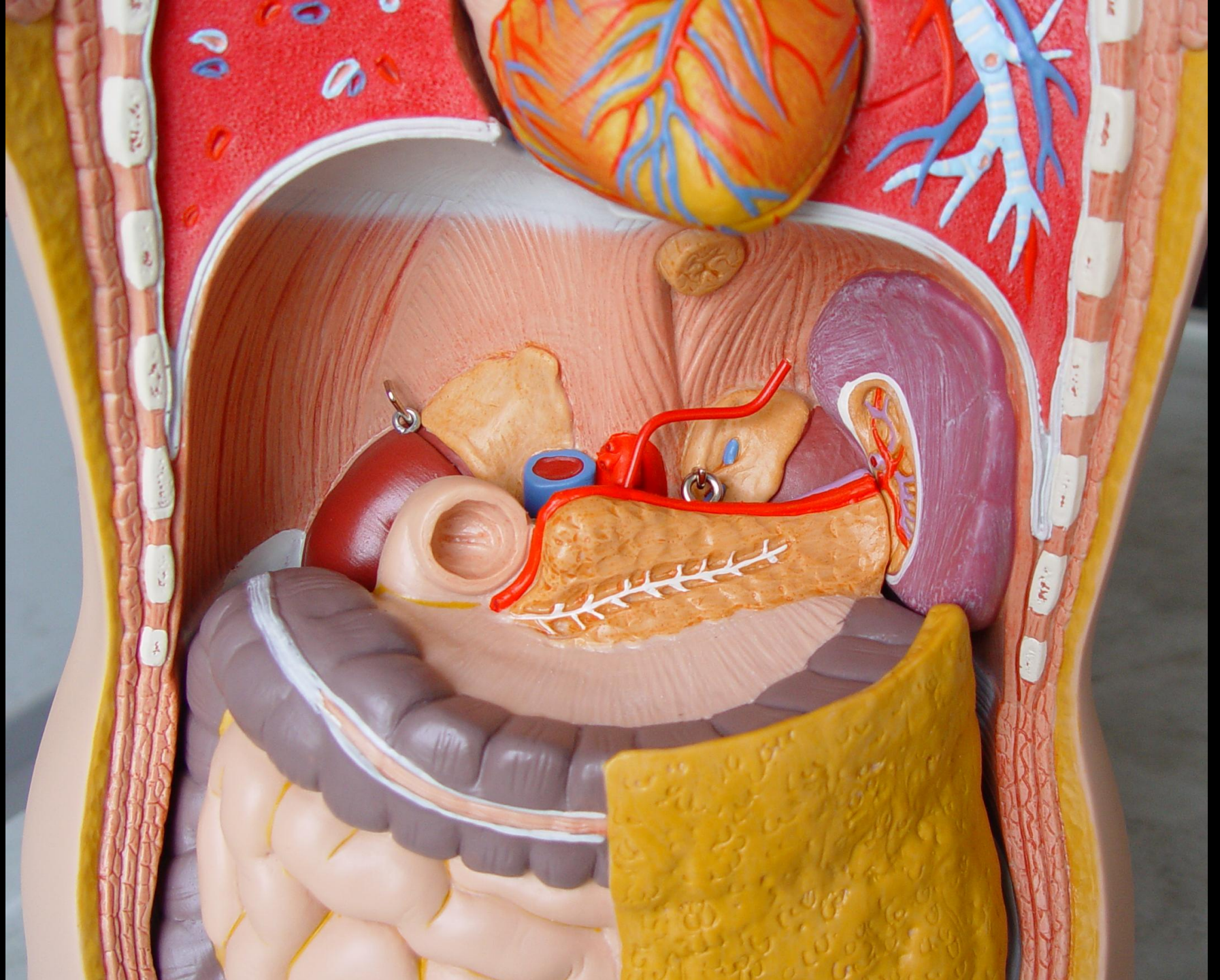
(I)

GRADO EN MEDICINA

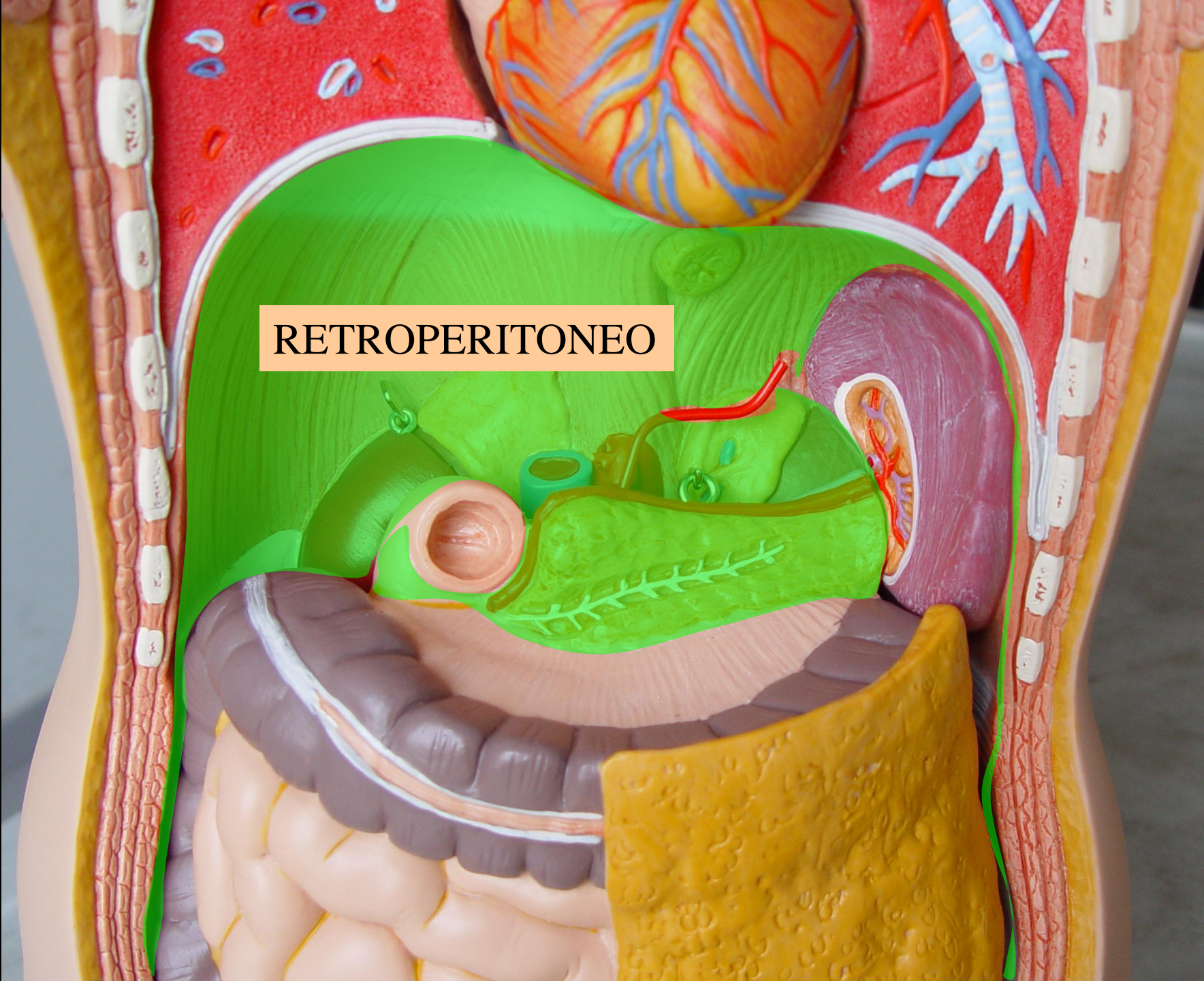


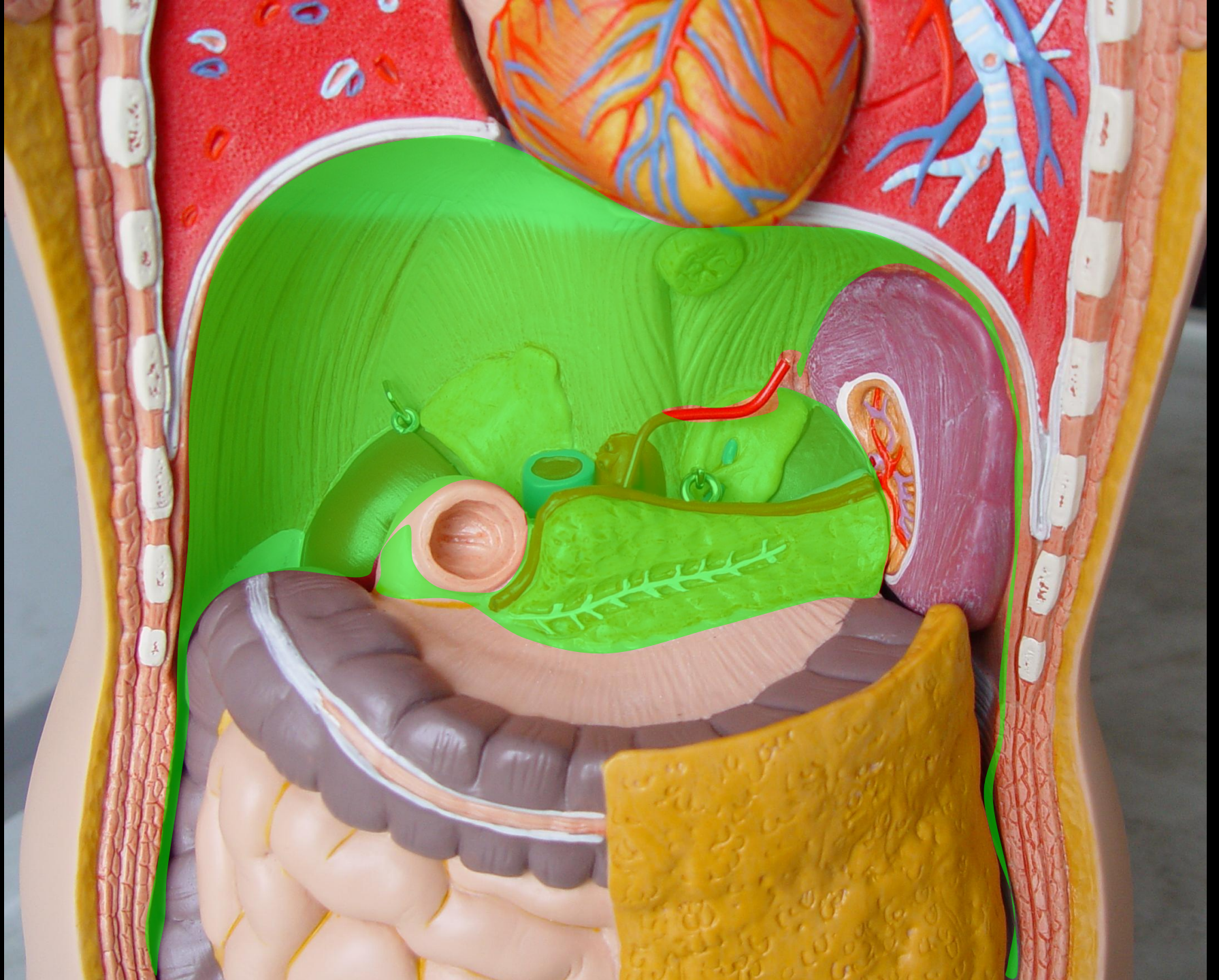






RETROPERITONEO







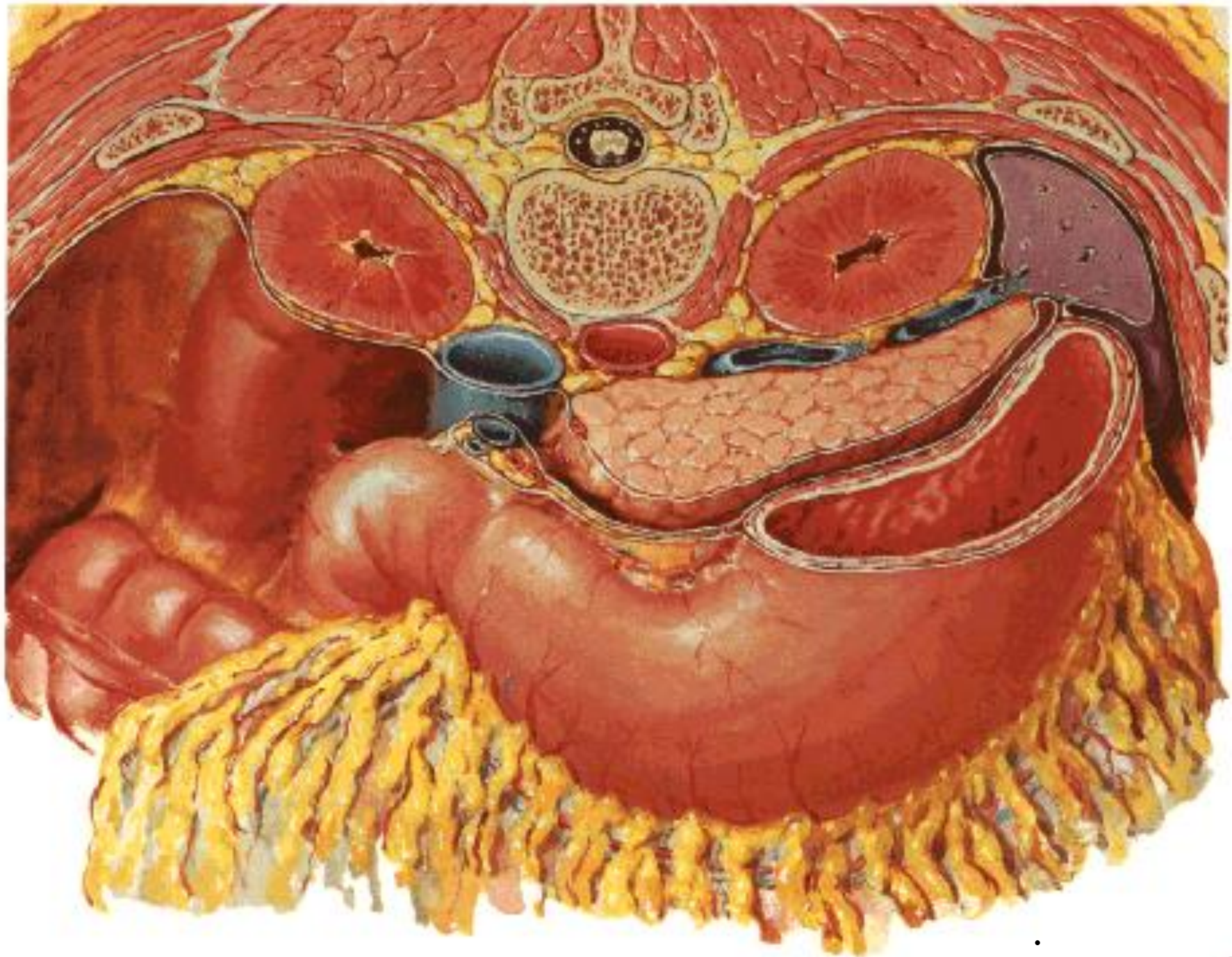Bazo

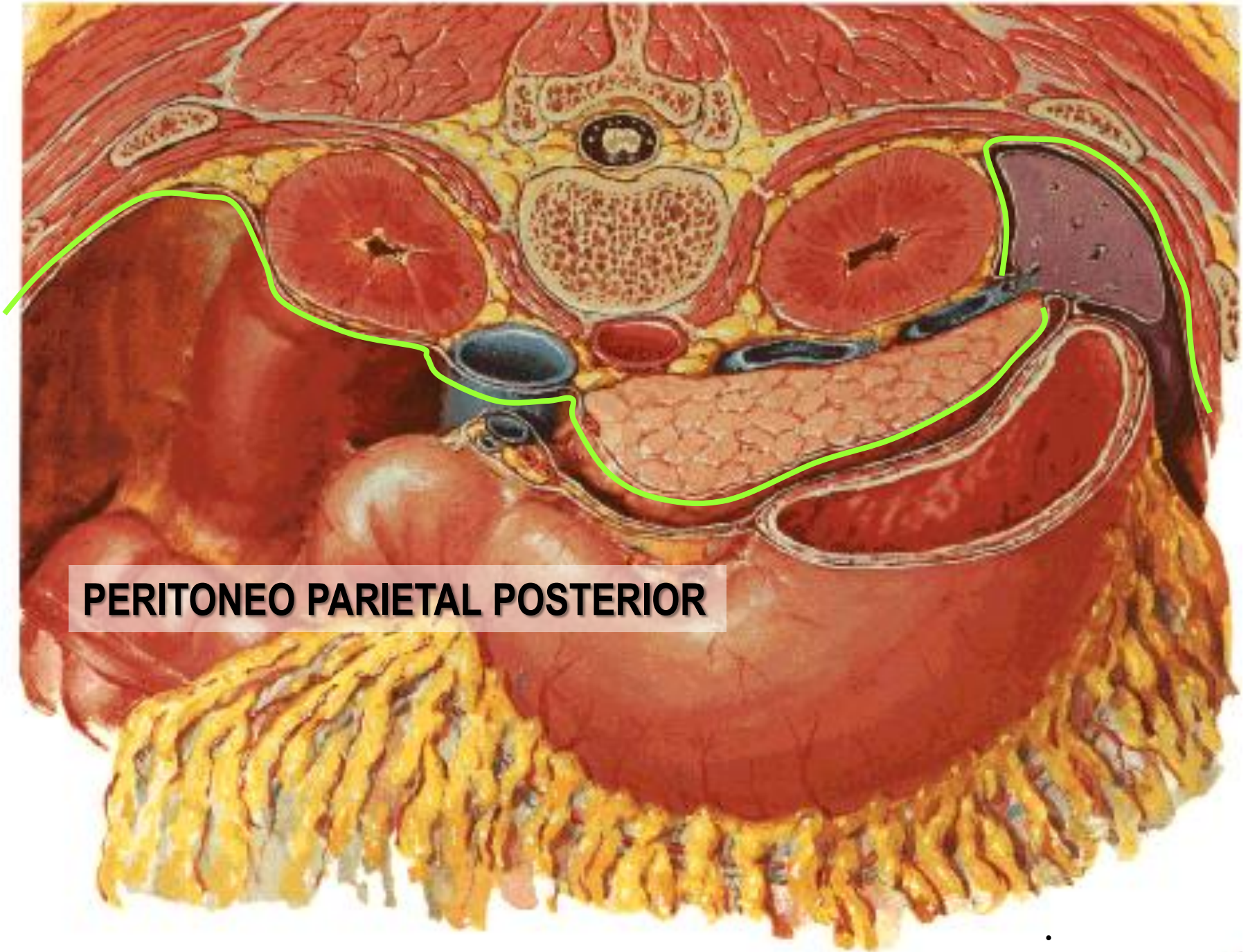
This anatomical model illustrates the internal organs of the human torso. The spleen, labeled 'Bazo', is highlighted in green and is located in the upper left quadrant of the abdomen. It is connected to the stomach by the splenic vessels, shown as red and blue tubes. The liver is visible on the right side, and the stomach is shown in the center. The lungs are visible at the top, and the intestines are shown at the bottom. The model is surrounded by a red outer layer representing the skin and muscle, and a yellow layer representing the peritoneum.



Bazo

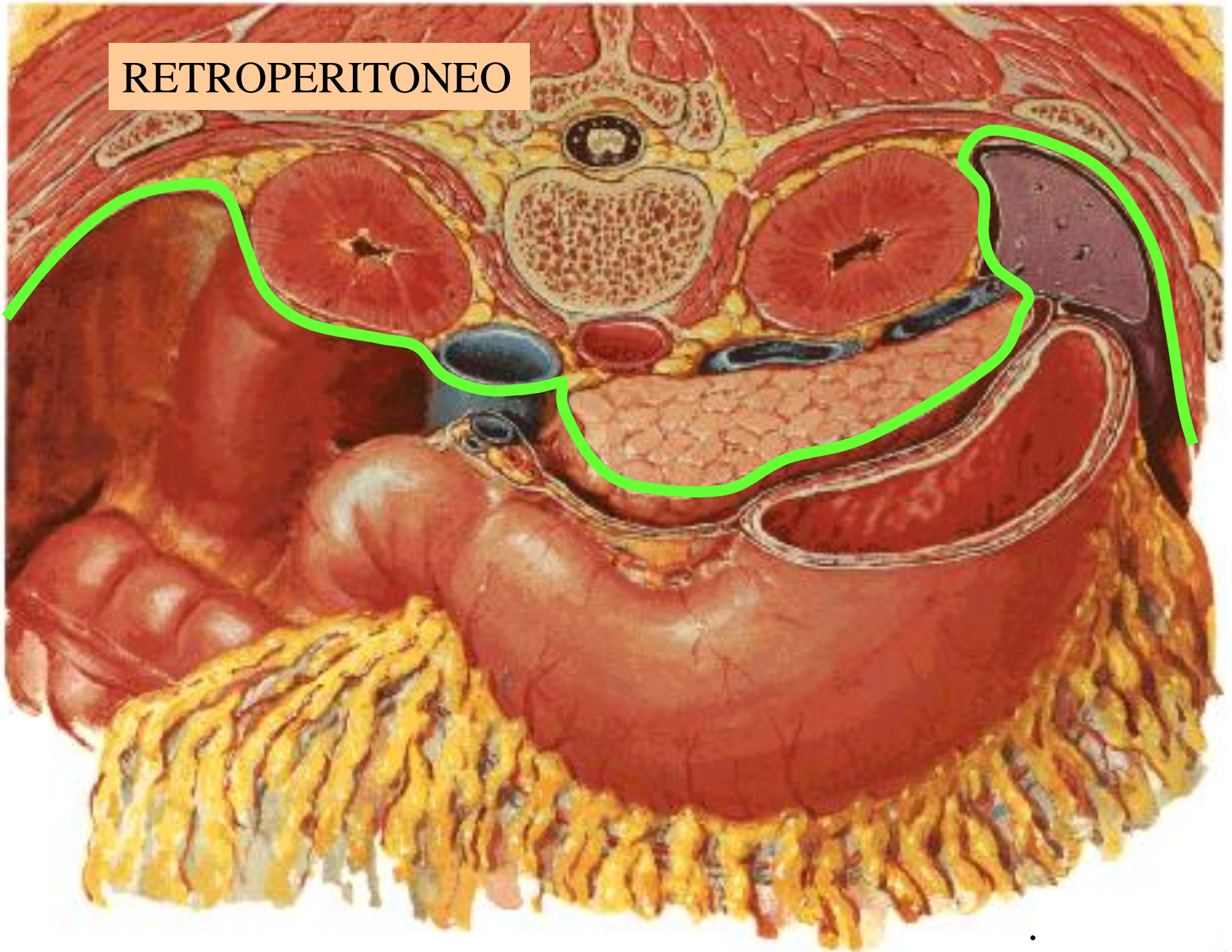
El bazo es un órgano intraperitoneal

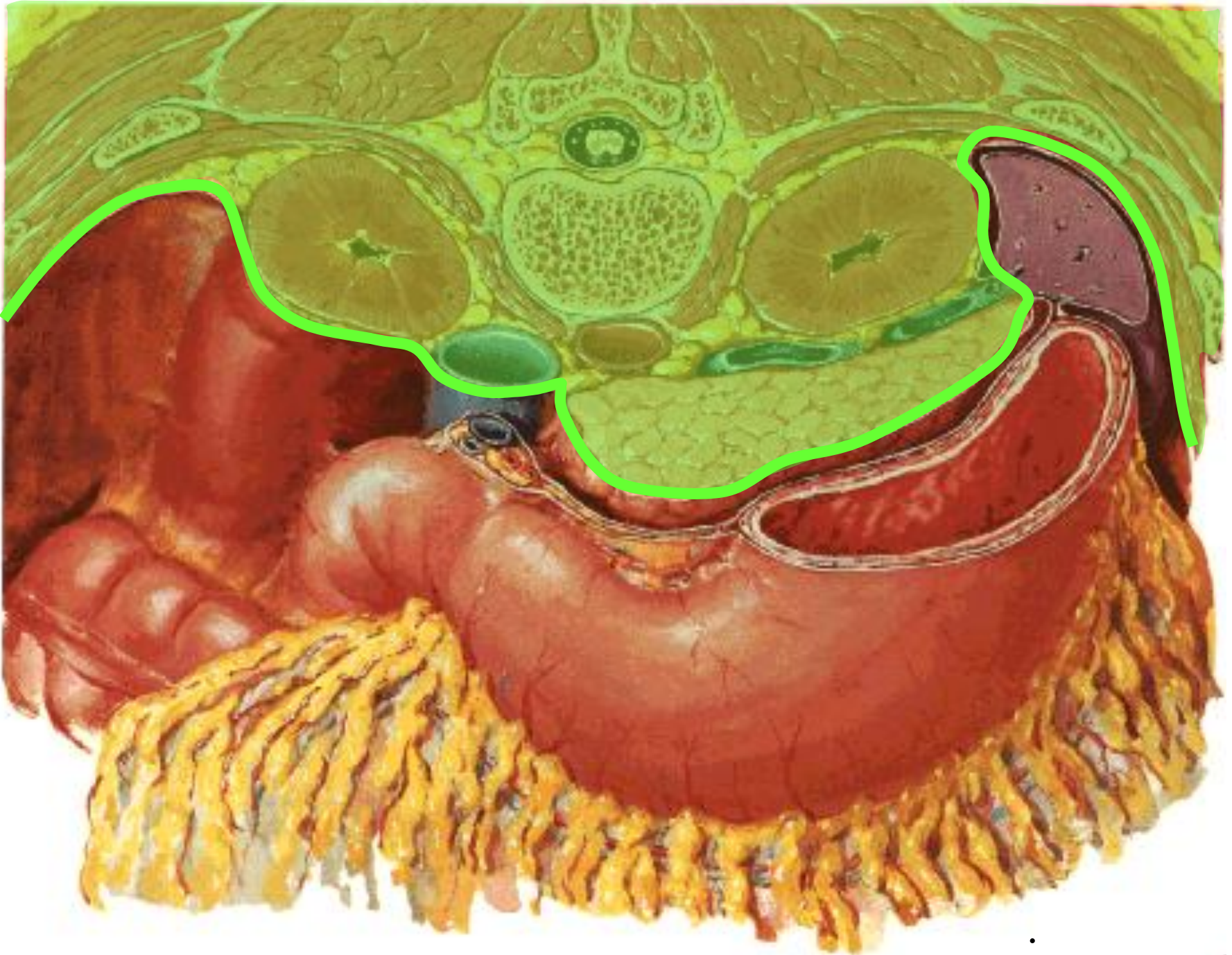




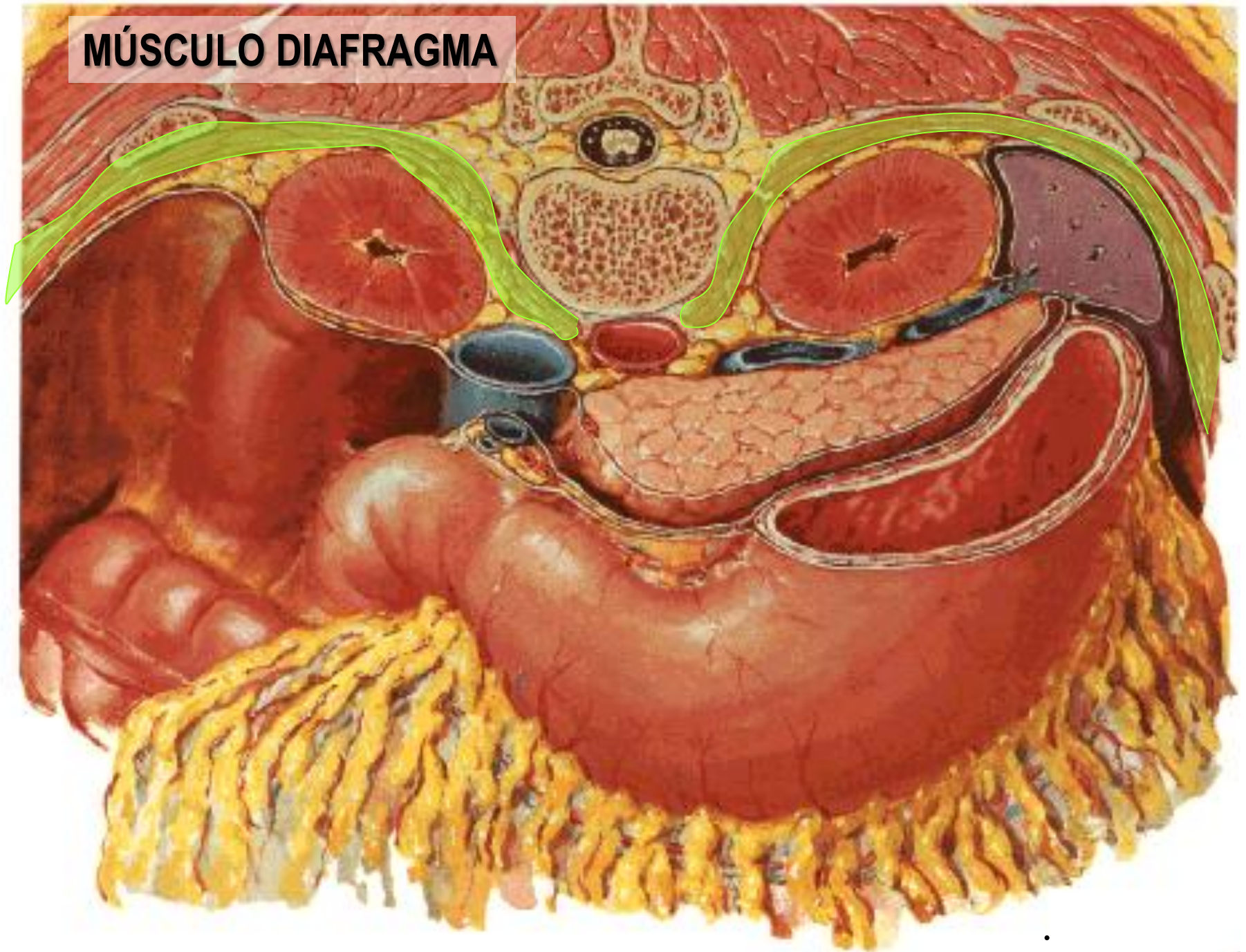PERITONEO PARIETAL POSTERIOR

RETROPERITONEO

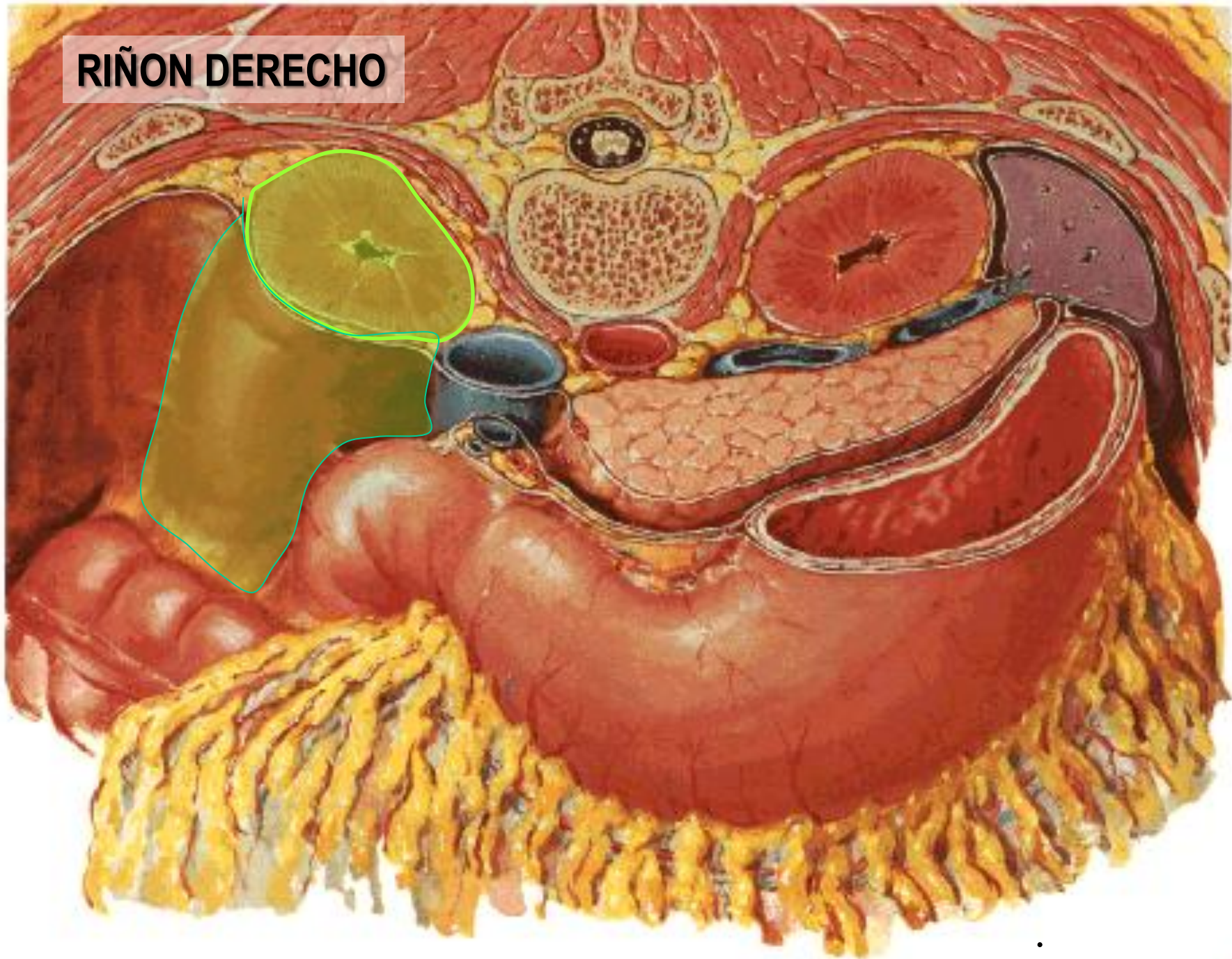




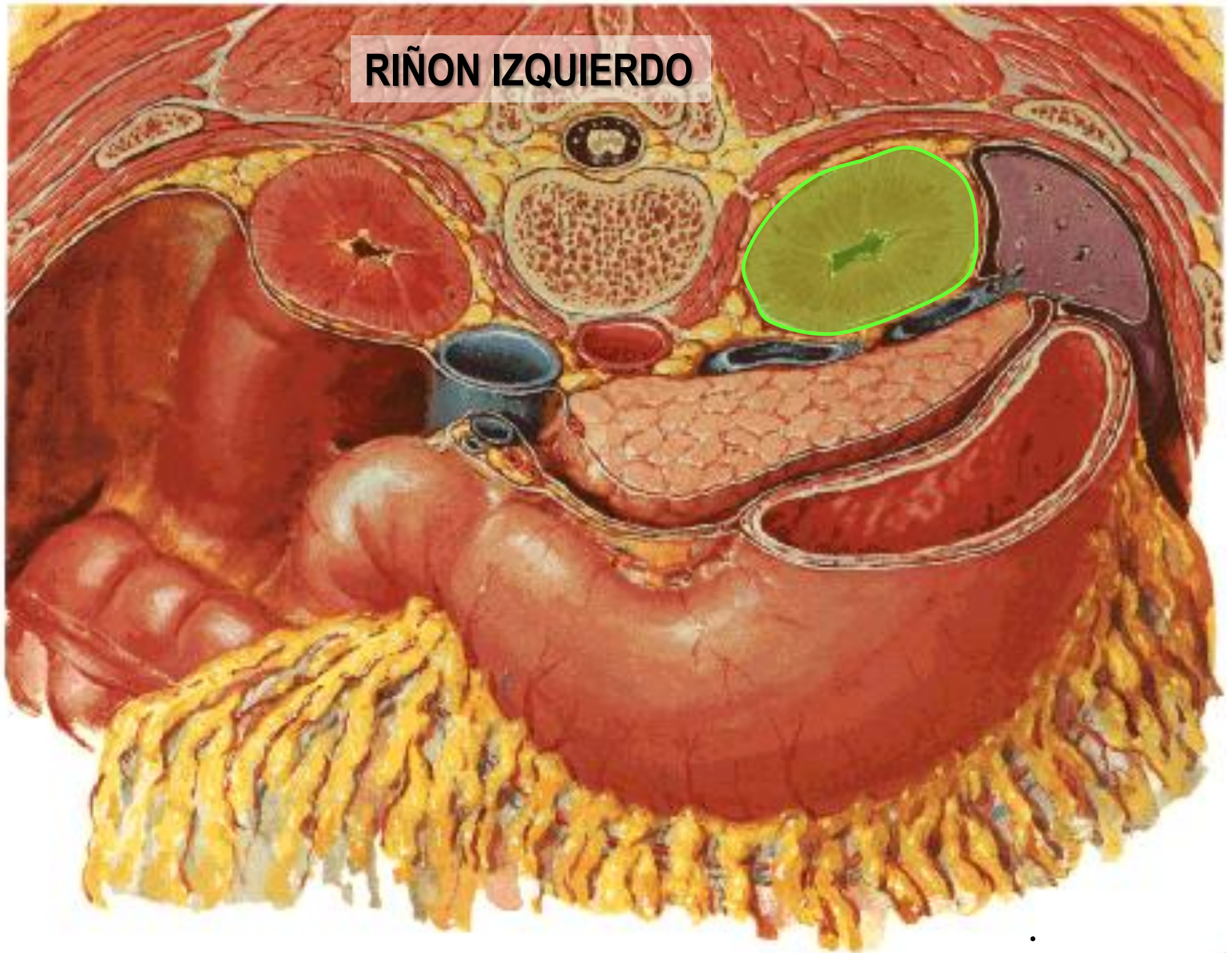
MÚSCULO DIAFRAGMA



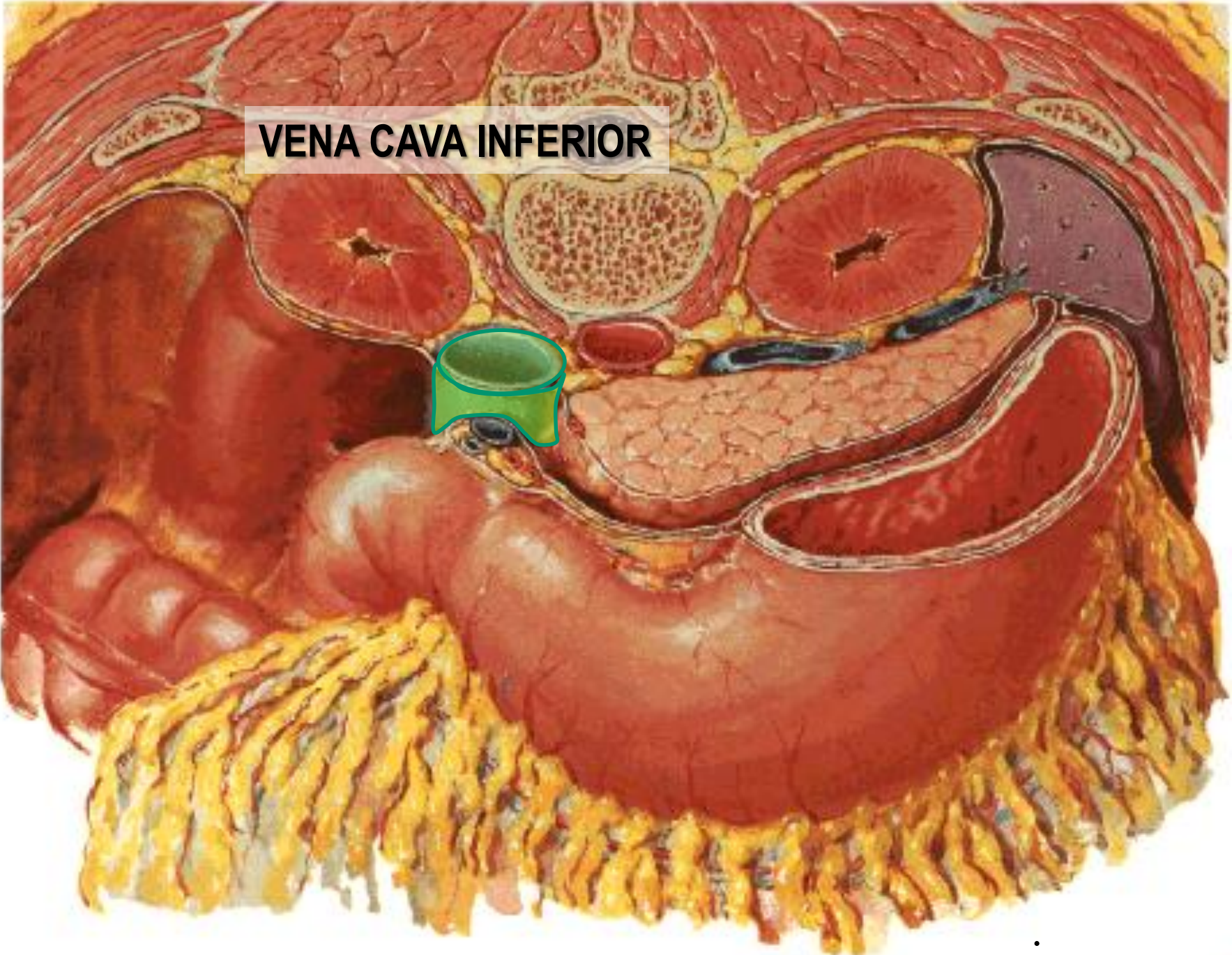
RIÑÓN DERECHO

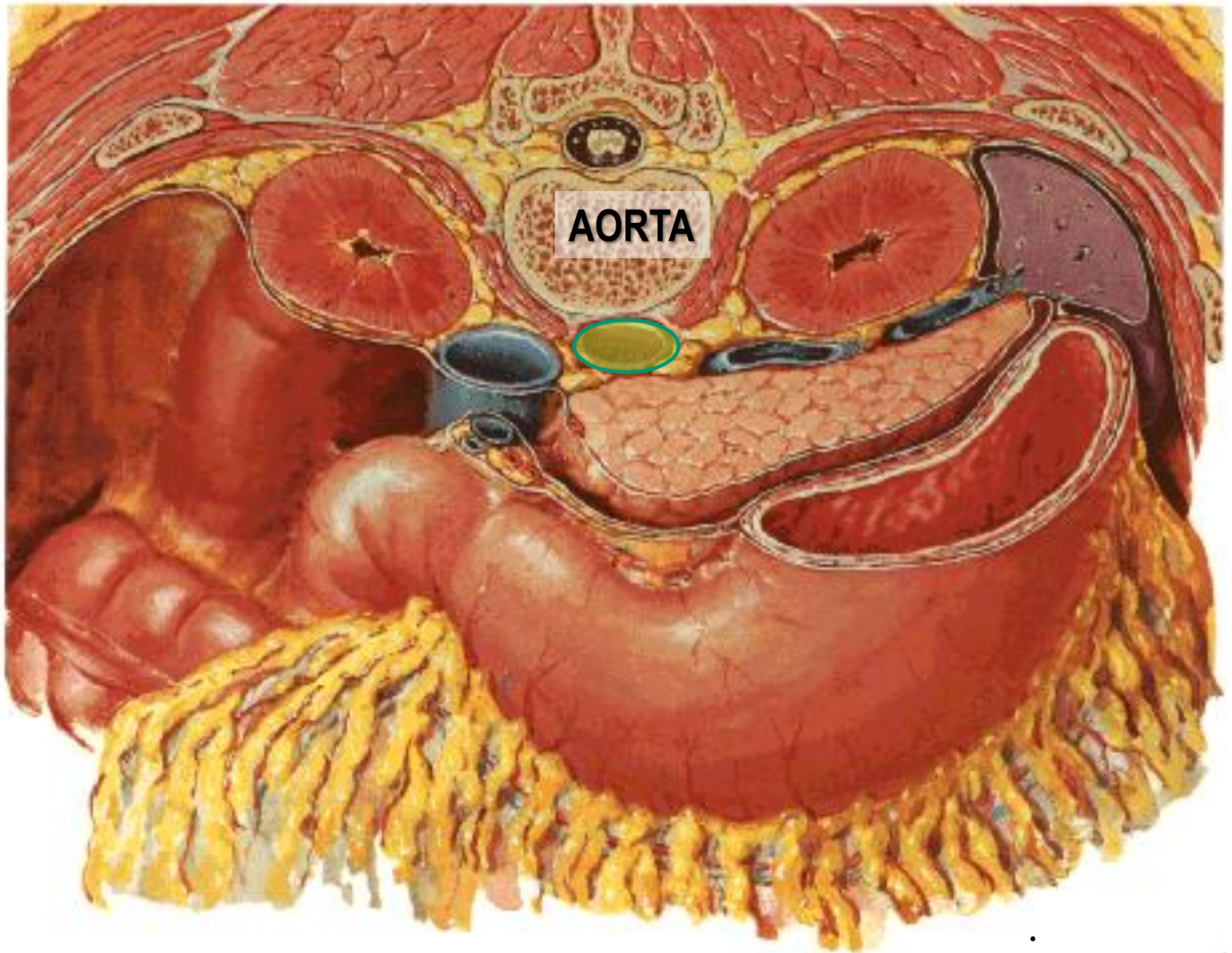


RIÑÓN IZQUIERDO



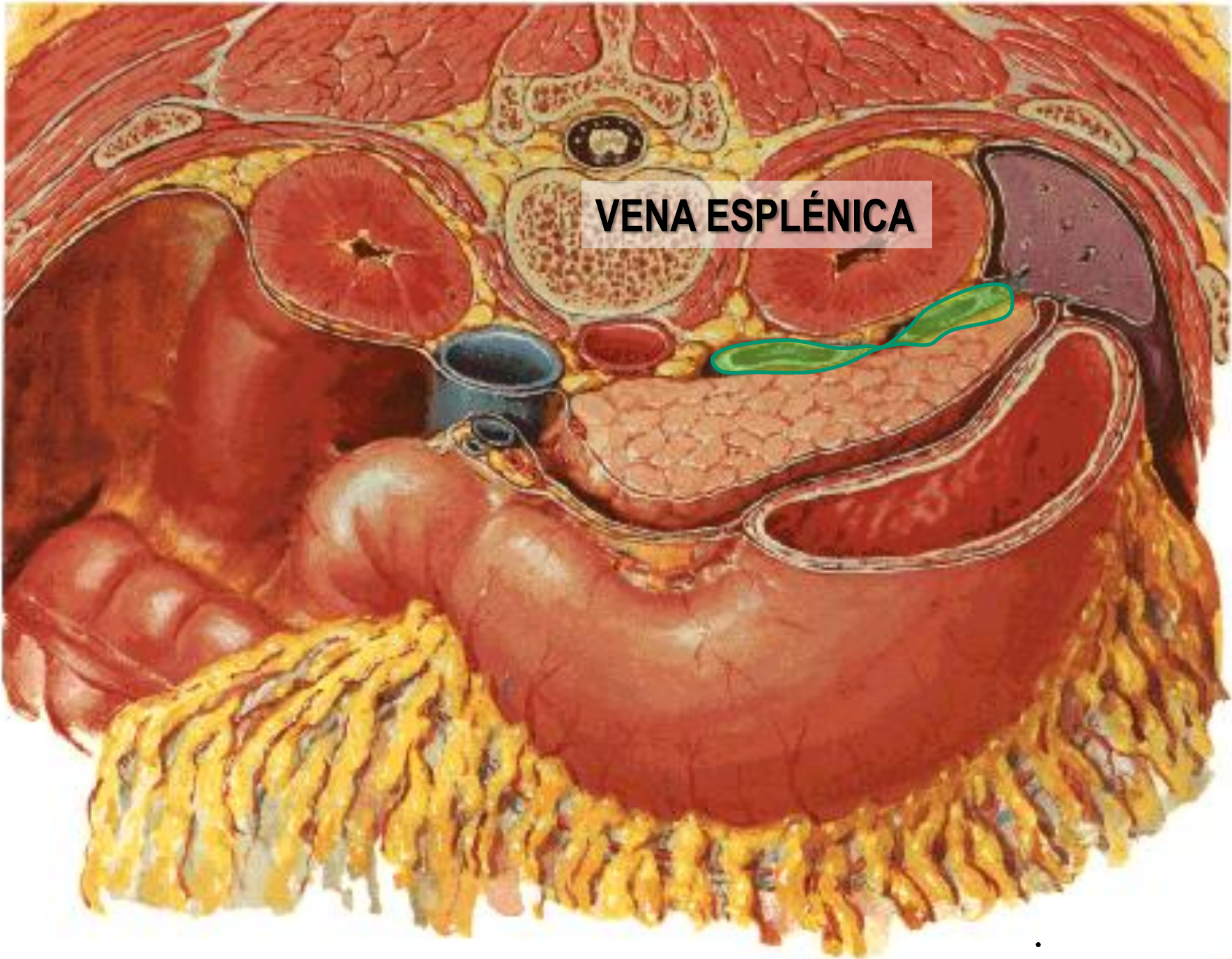
VENA CAVA INFERIOR

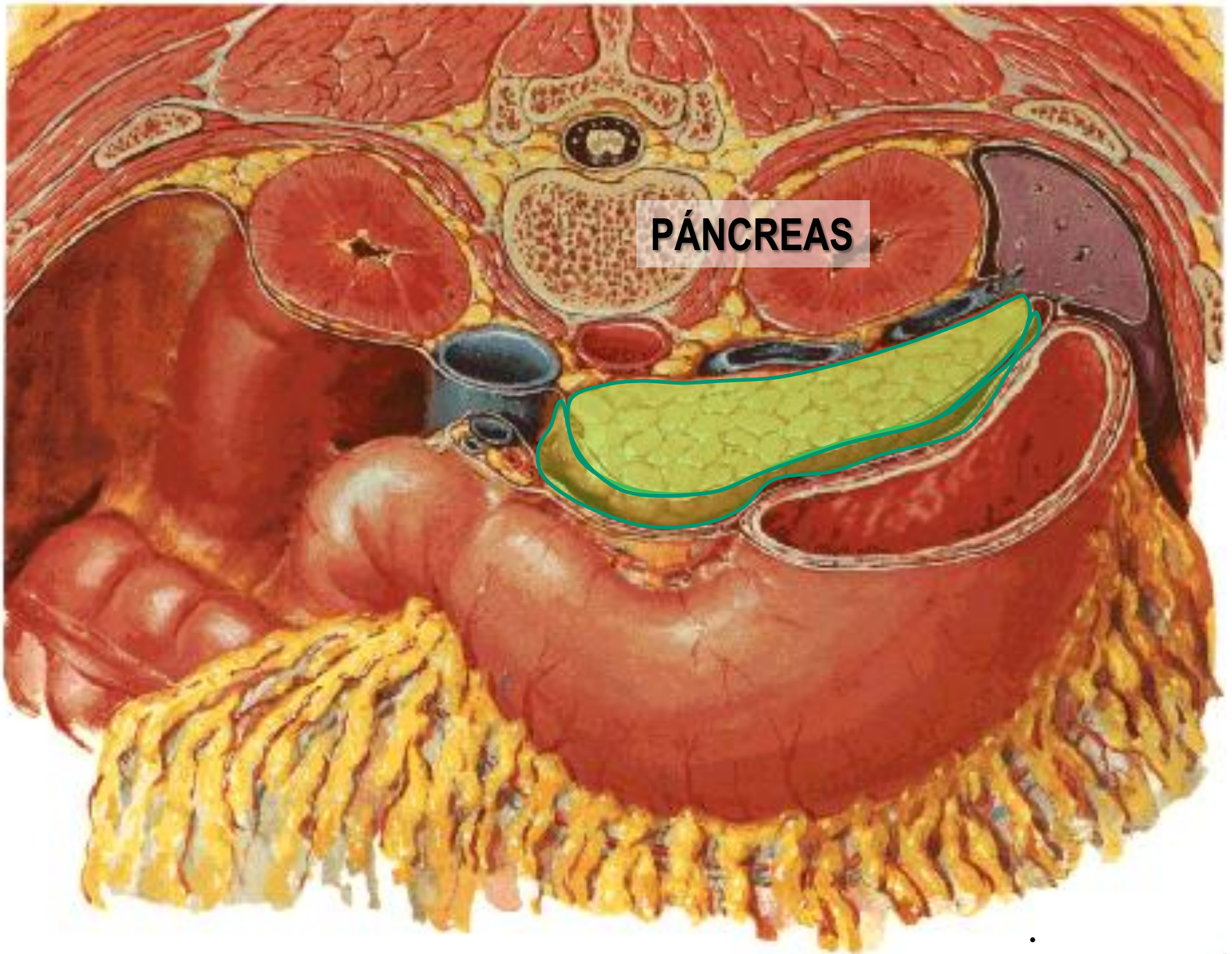




AORTA

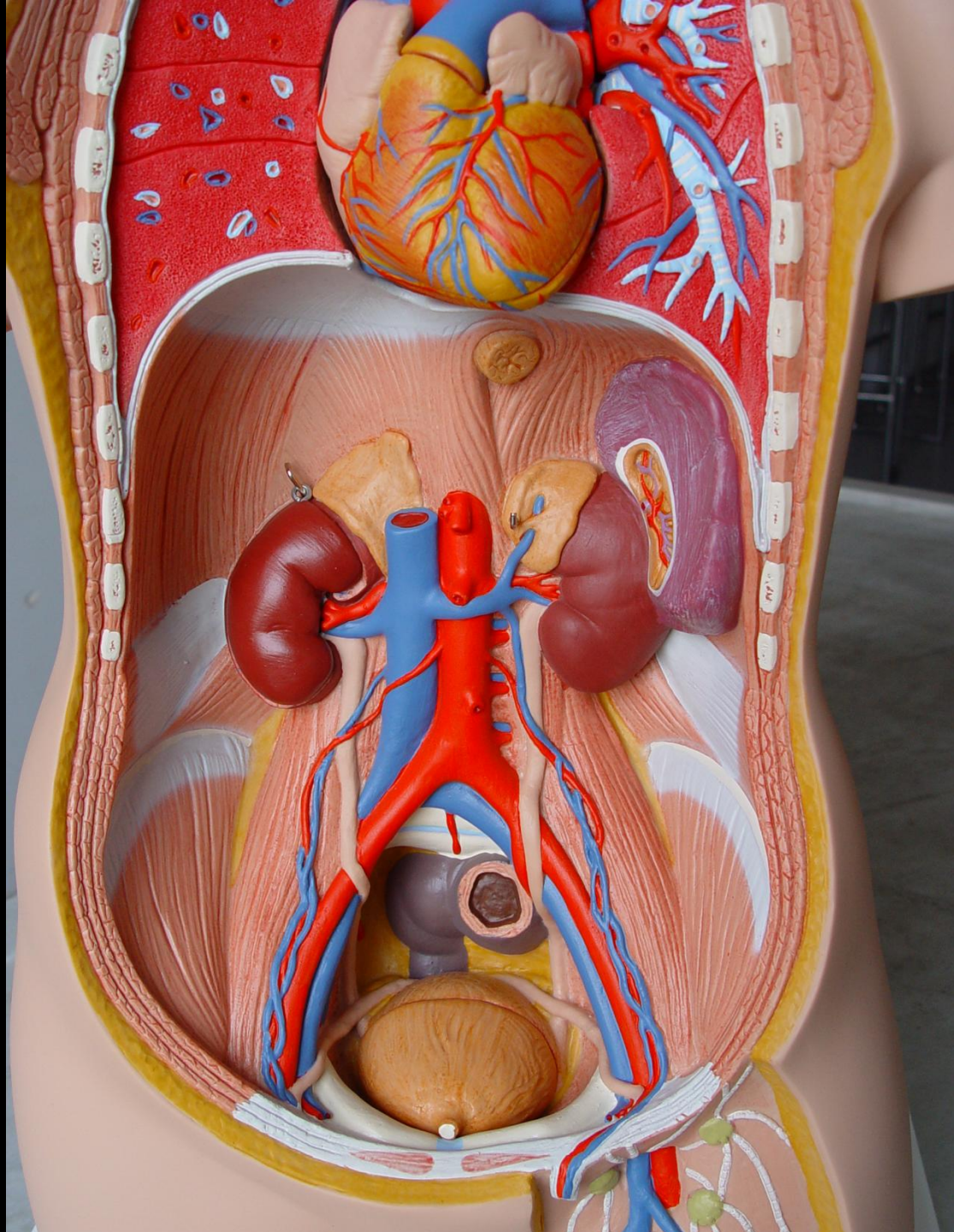
VENA ESPLÉNICA





PÁNCREAS



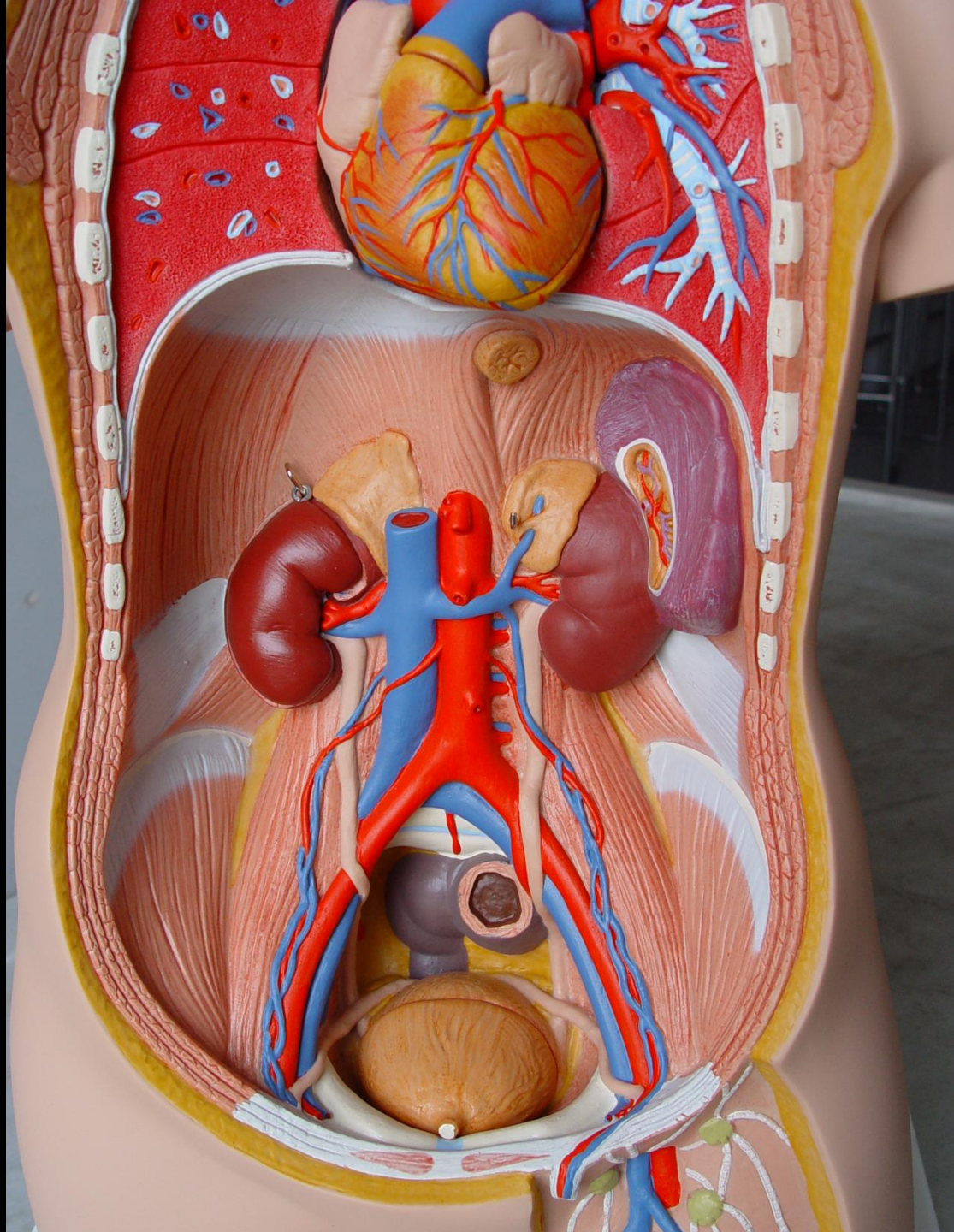


An anatomical model of the human torso, showing a cross-section of the abdominal cavity. The model is color-coded to distinguish between different organs and structures. The heart is shown in yellow and red, with its major blood vessels. The lungs are shown in red and blue. The stomach is shown in a reddish-brown color, and the spleen is shown in a dark purple color. The kidneys are shown in a dark red color. The liver is shown in a brownish-yellow color. The pancreas is shown in a light brown color. The spleen is shown in a dark purple color. The model also shows the abdominal wall, the diaphragm, and the pelvic region. The text "El bazo es un órgano intraperitoneal" is overlaid on the model, indicating that the spleen is an intraperitoneal organ.

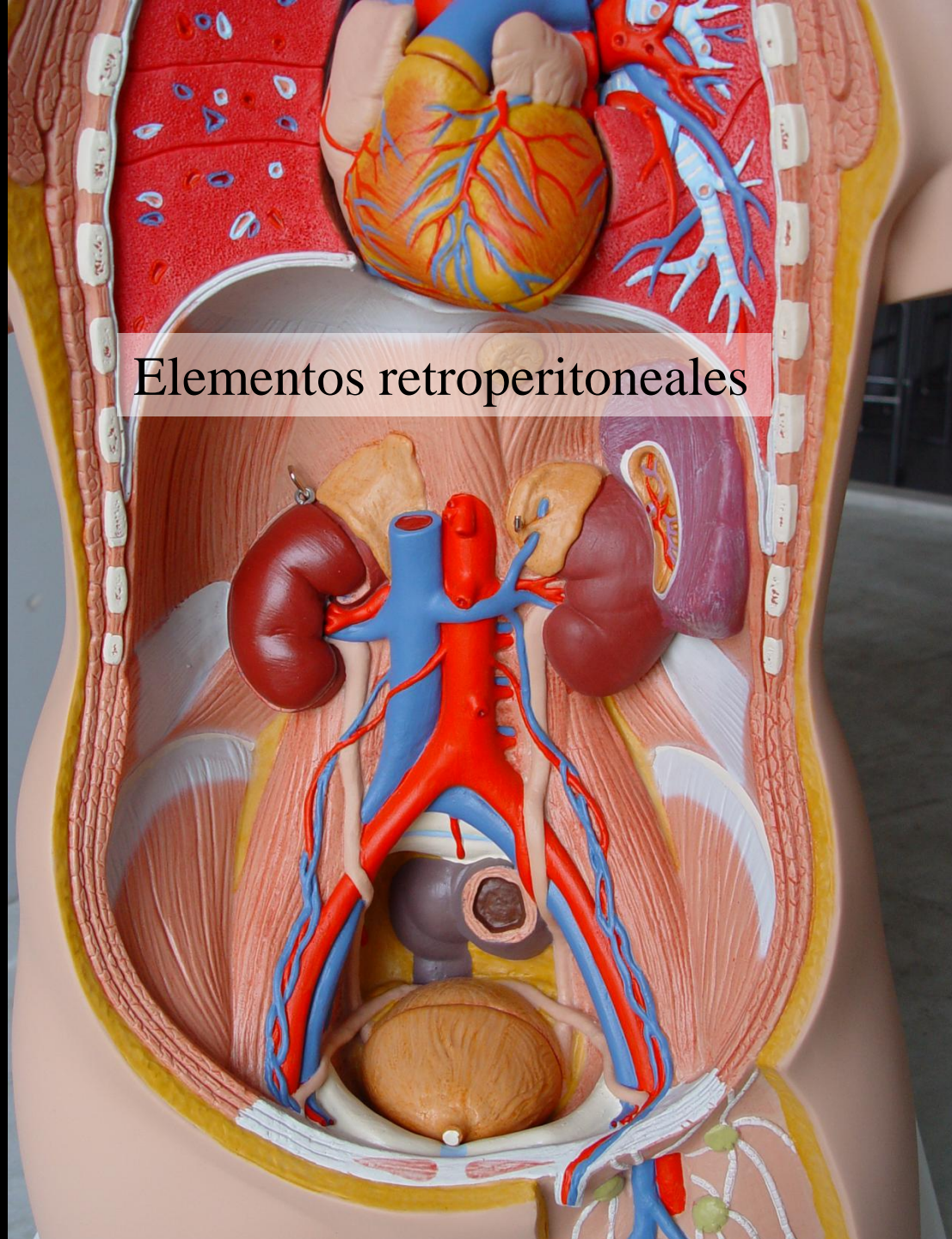
El bazo es un órgano intraperitoneal

An anatomical model of the human torso, showing the internal organs and the spleen highlighted in green. The model is a cutaway view of the human body, showing the internal organs and the spleen highlighted in green. The spleen is located in the upper left quadrant of the abdomen, behind the stomach. The model also shows the heart, lungs, kidneys, and other abdominal organs. The text "El bazo es un órgano intraperitoneal" is overlaid on the image.

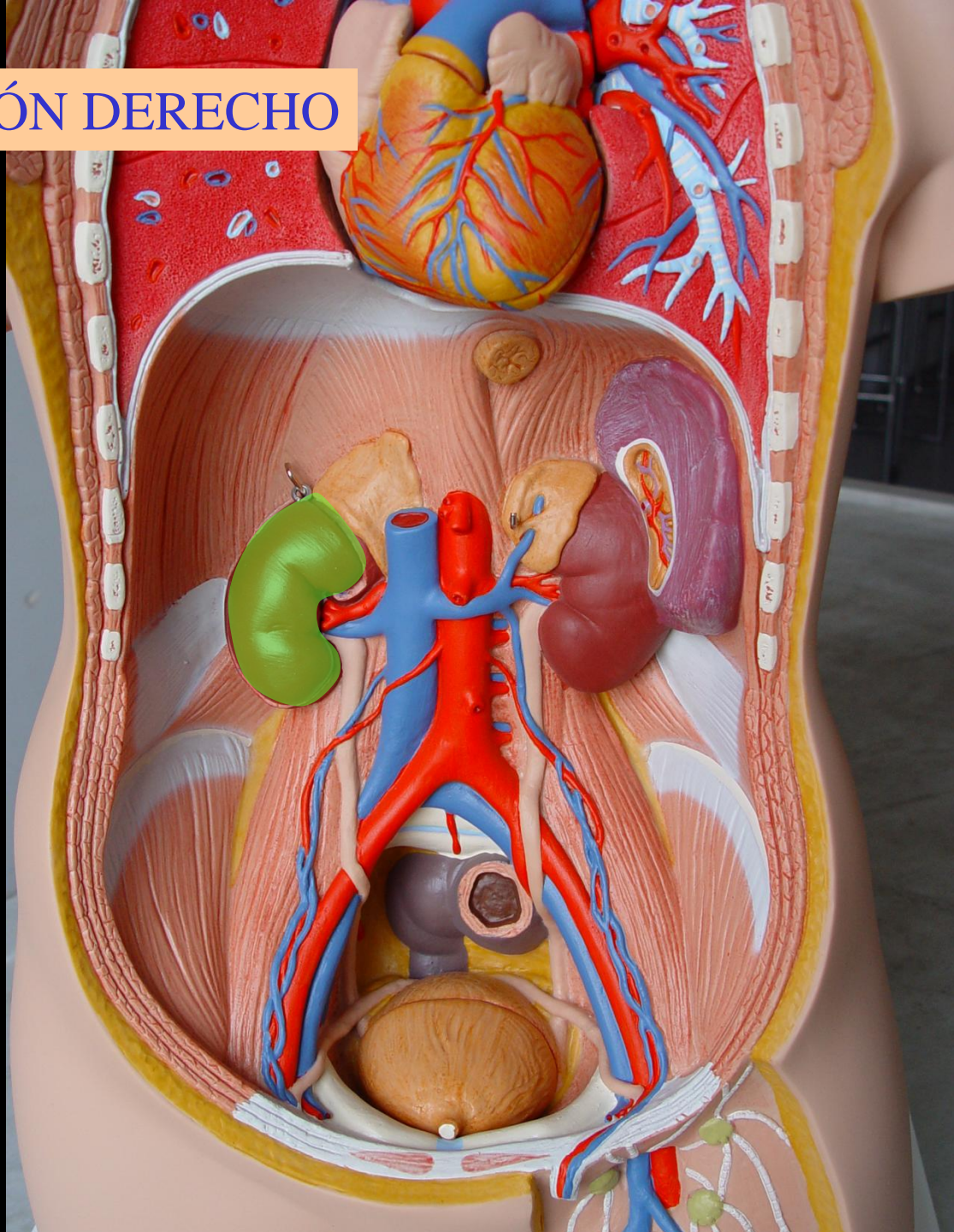
El bazo es un órgano intraperitoneal



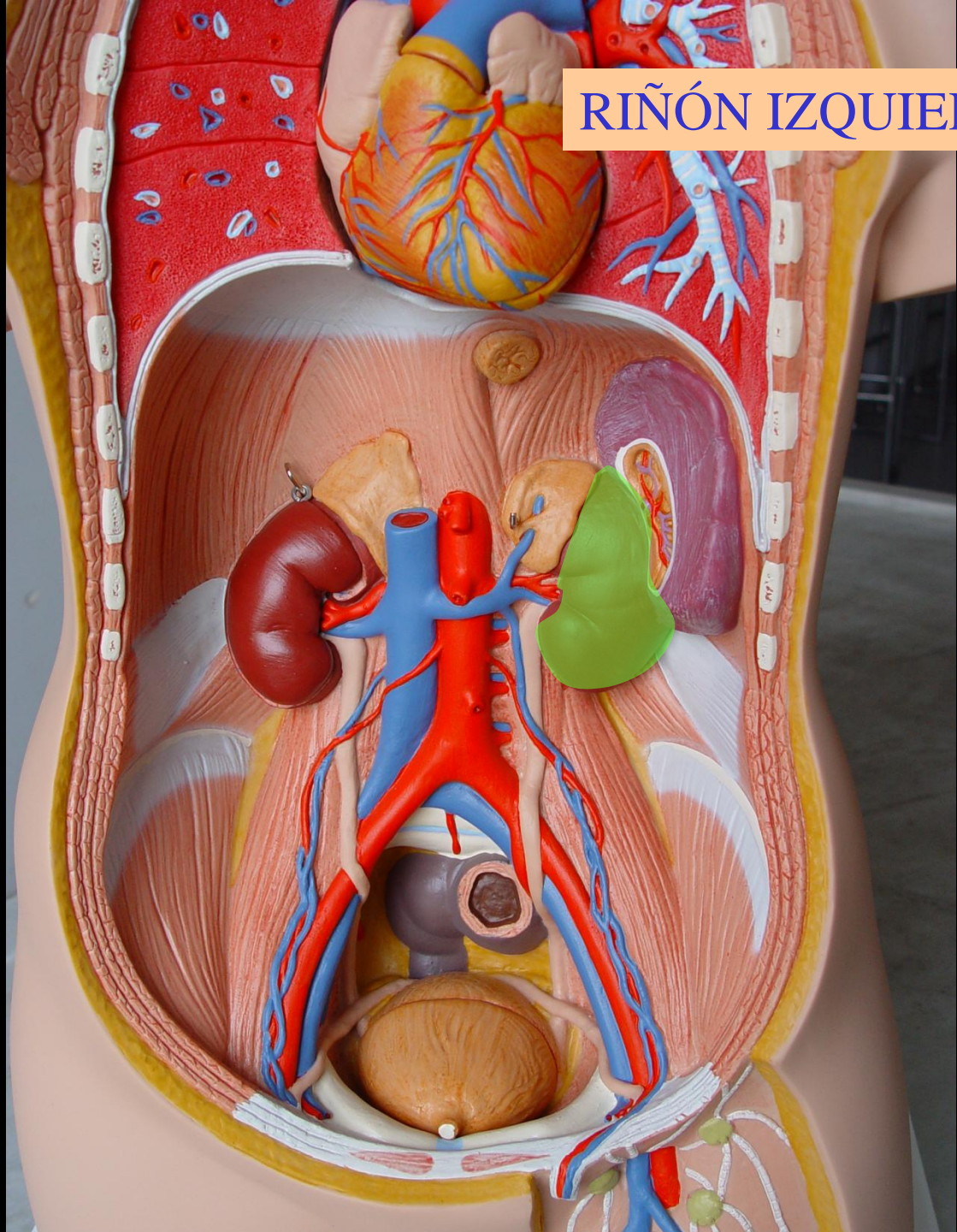
Elementos retroperitoneales

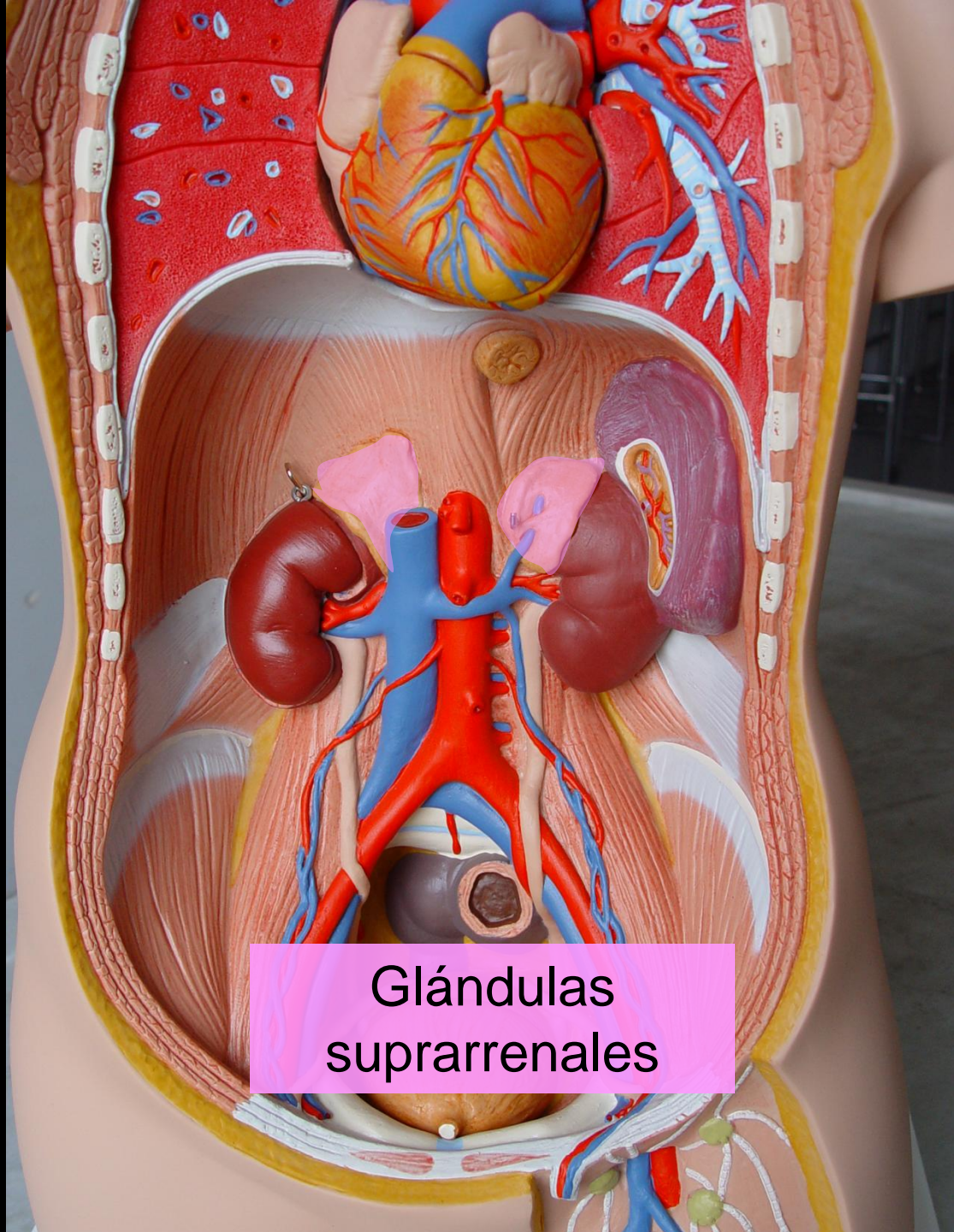


RIÑÓN DERECHO

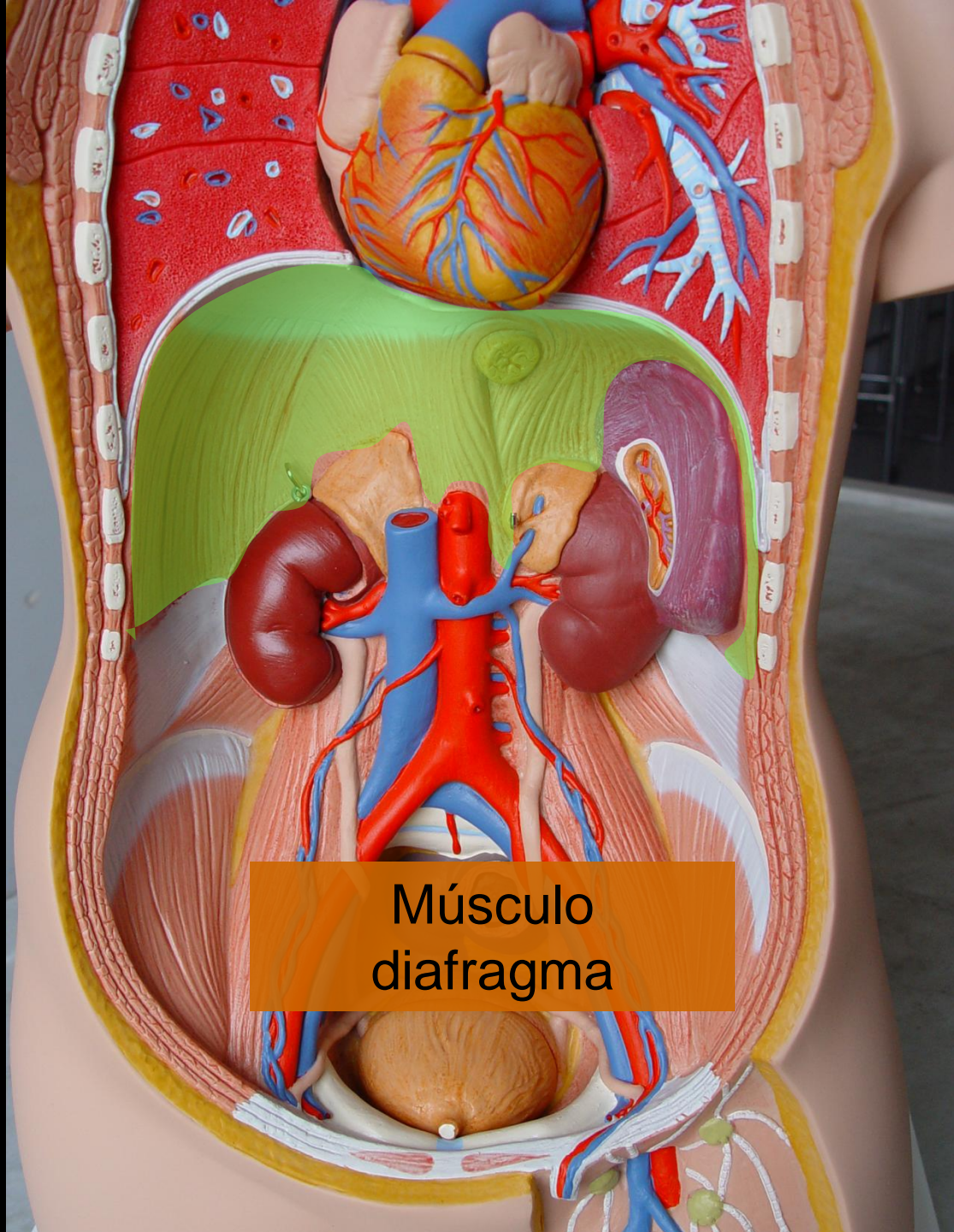


RIÑÓN IZQUIERDO



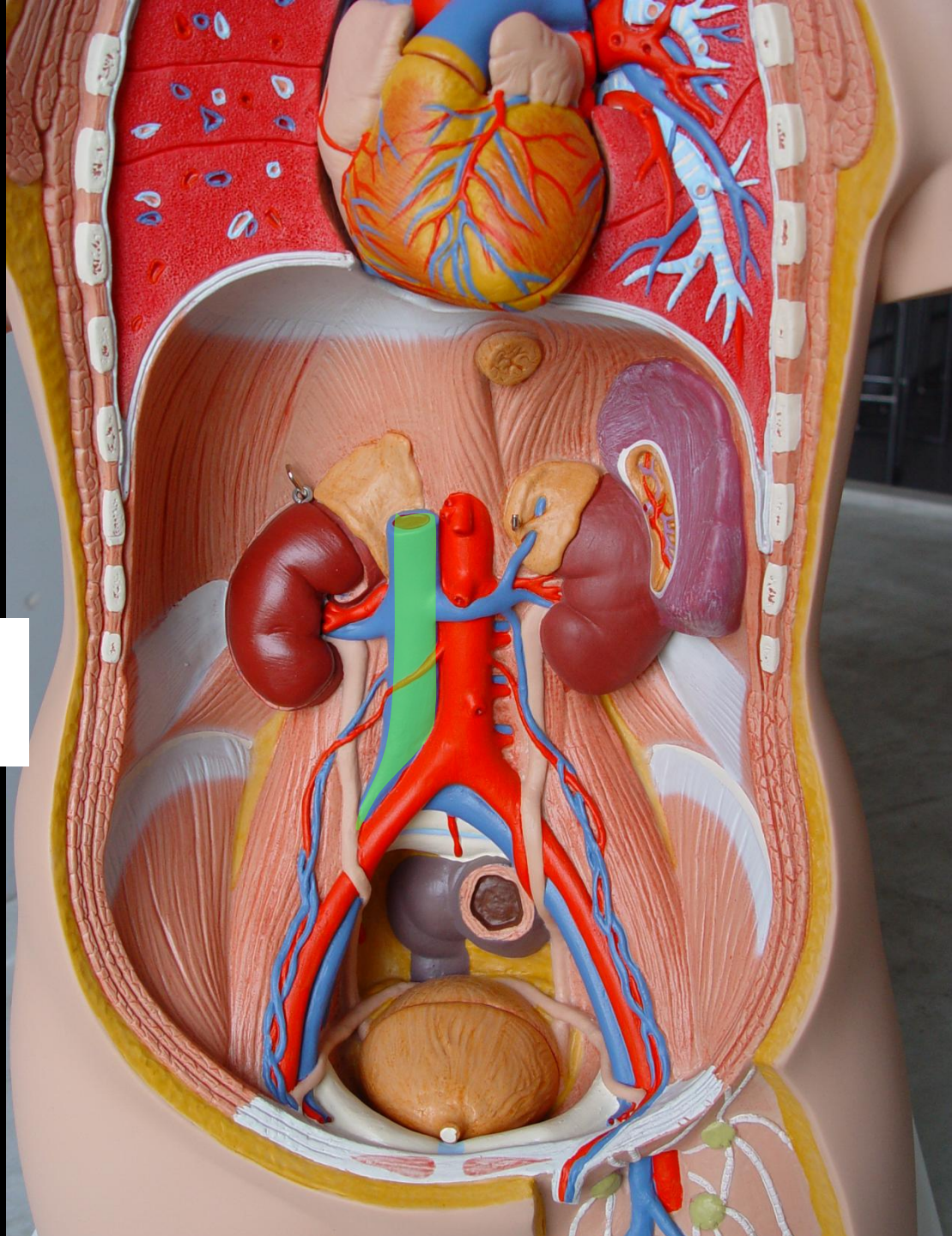


Glándulas
suprarrenales



Músculo
diafragma

CAVA
INFERIOR





Venas renales

CAVA
INFERIOR



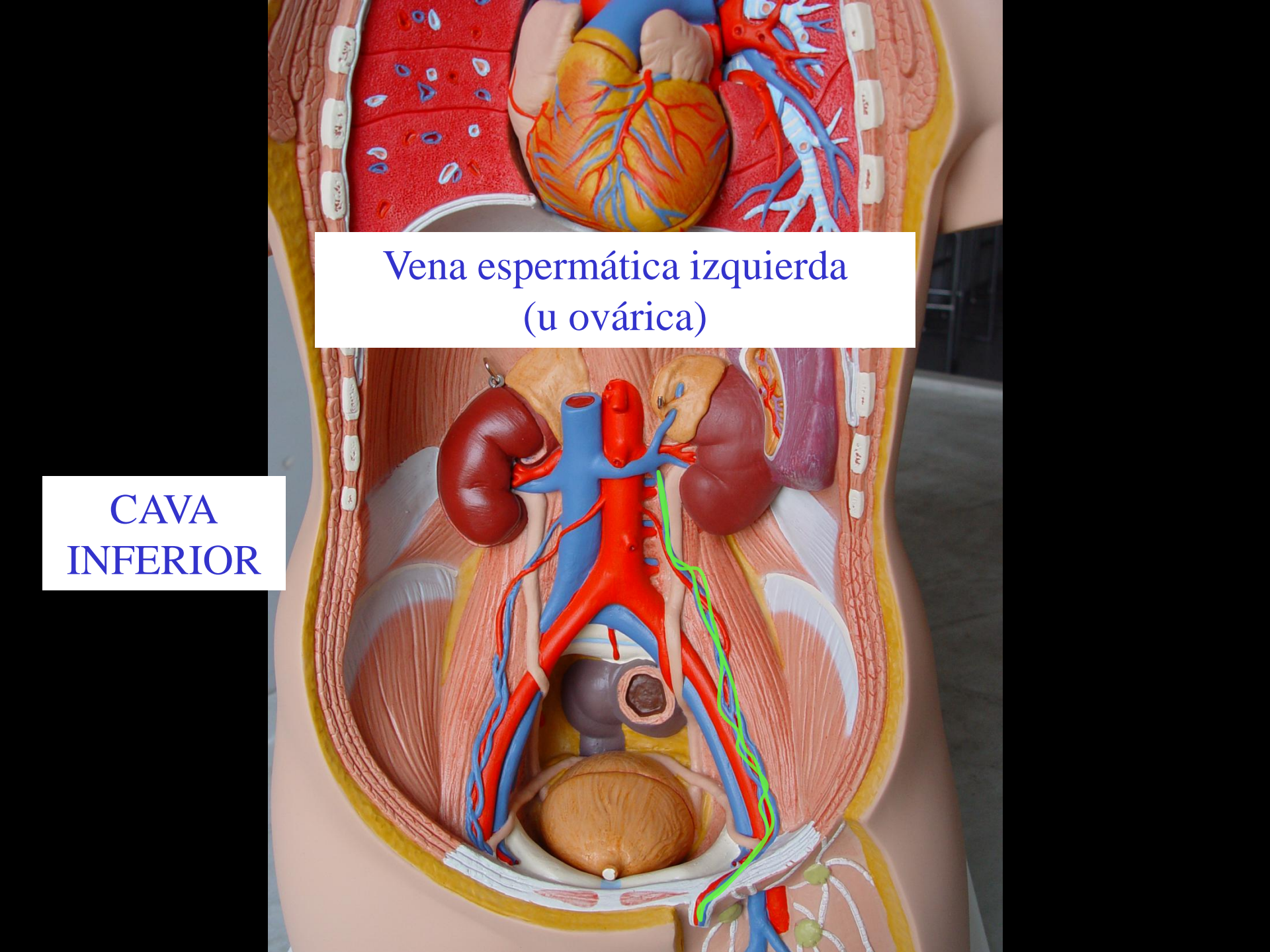
Vena cápsular central o
suprarrenal principal izquierda

CAVA
INFERIOR



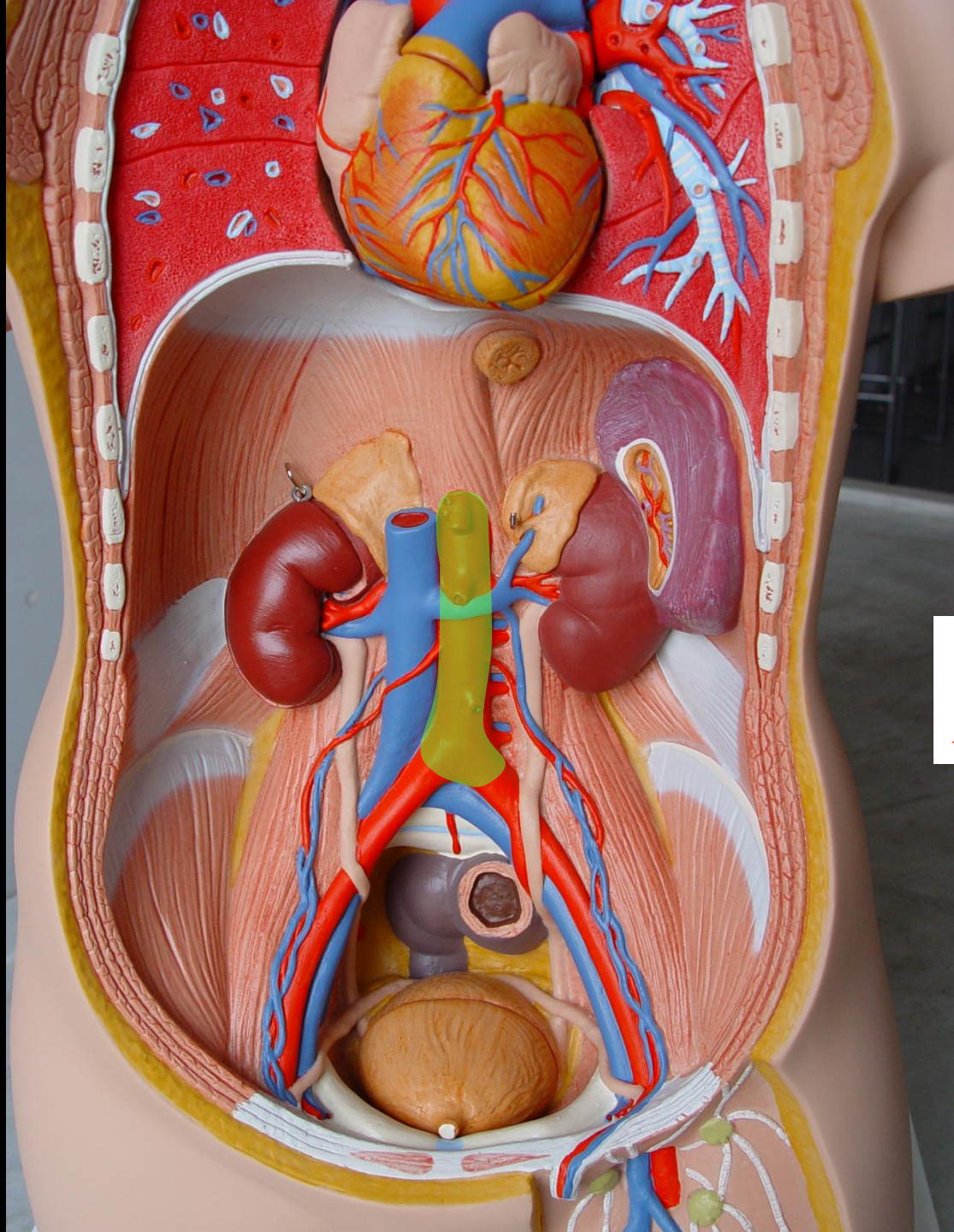
Vena espermática derecha
(u ovárica)

CAVA
INFERIOR



Vena espermática izquierda
(u ovárica)

CAVA
INFERIOR

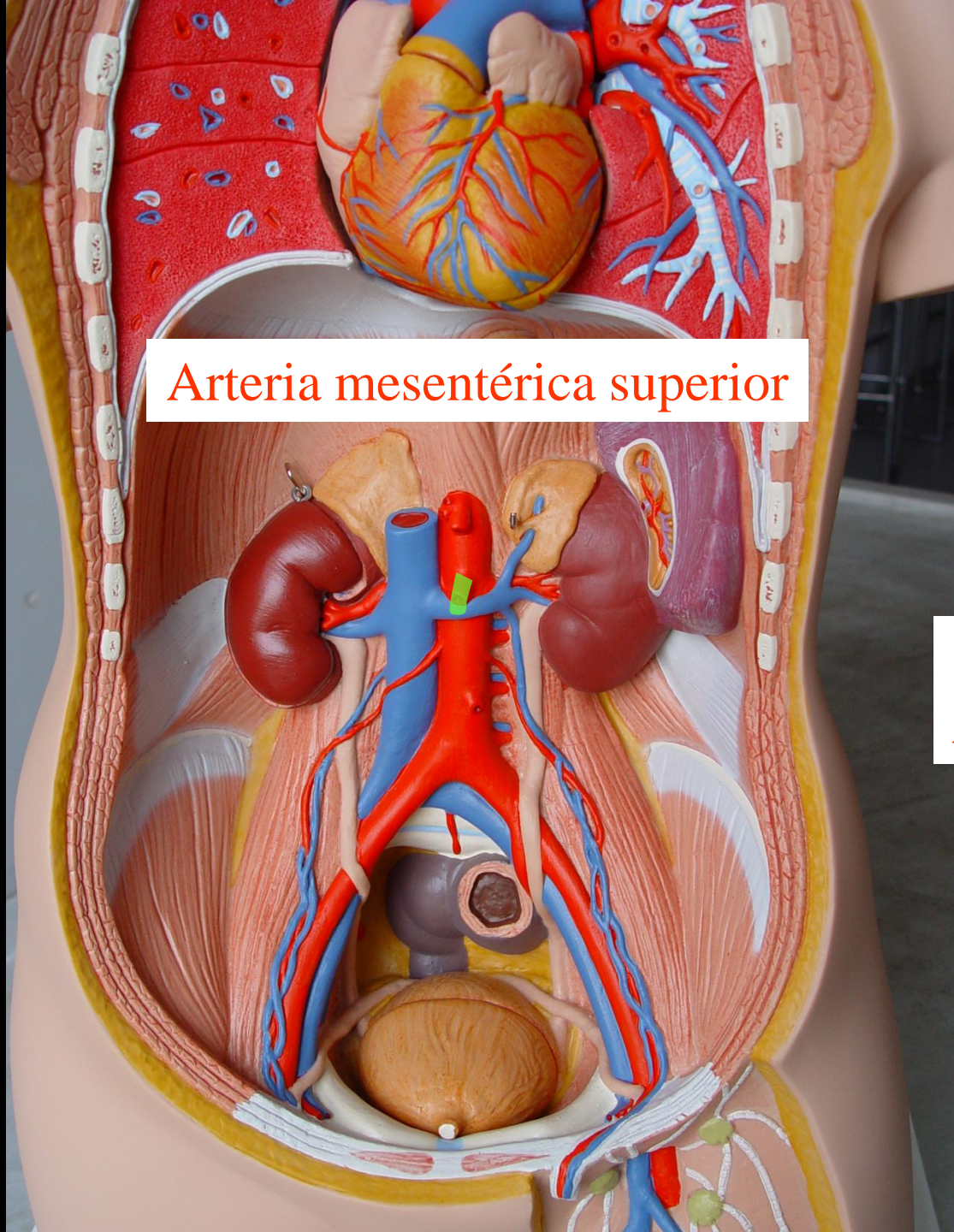


**AORTA
ABDOMINAL**

An anatomical model of the human torso, showing the abdominal cavity. The abdominal aorta is highlighted in red, branching into the celiac trunk and the superior mesenteric artery. The inferior vena cava is shown in blue. The kidneys are visible on either side of the aorta. The model is cut open to show internal organs and structures.

Tronco celiaco o
trípode de Haller

AORTA
ABDOMINAL



Arteria mesentérica superior

AORTA
ABDOMINAL

An anatomical model of the human torso, showing the abdominal cavity. The aorta is the central red vessel, branching into the superior mesenteric artery (top), the inferior mesenteric artery (middle), and the common iliac arteries (bottom). The inferior mesenteric artery is highlighted with a green dot. The kidneys are shown as reddish-brown structures on either side of the aorta. The liver and stomach are visible in the upper right. The model is cut open to show internal organs and vessels.

Arteria mesentérica inferior

AORTA
ABDOMINAL



Arterias renales

This anatomical model shows a cross-section of the human torso, focusing on the abdominal cavity. The abdominal aorta is the central red vessel, with two renal arteries branching off to the kidneys. The kidneys are shown as reddish-brown bean-shaped organs. The model also displays the lungs, heart, and various muscles and organs within the abdominal cavity. The text 'Arterias renales' is overlaid on the image, pointing to the renal arteries.

AORTA
ABDOMINAL



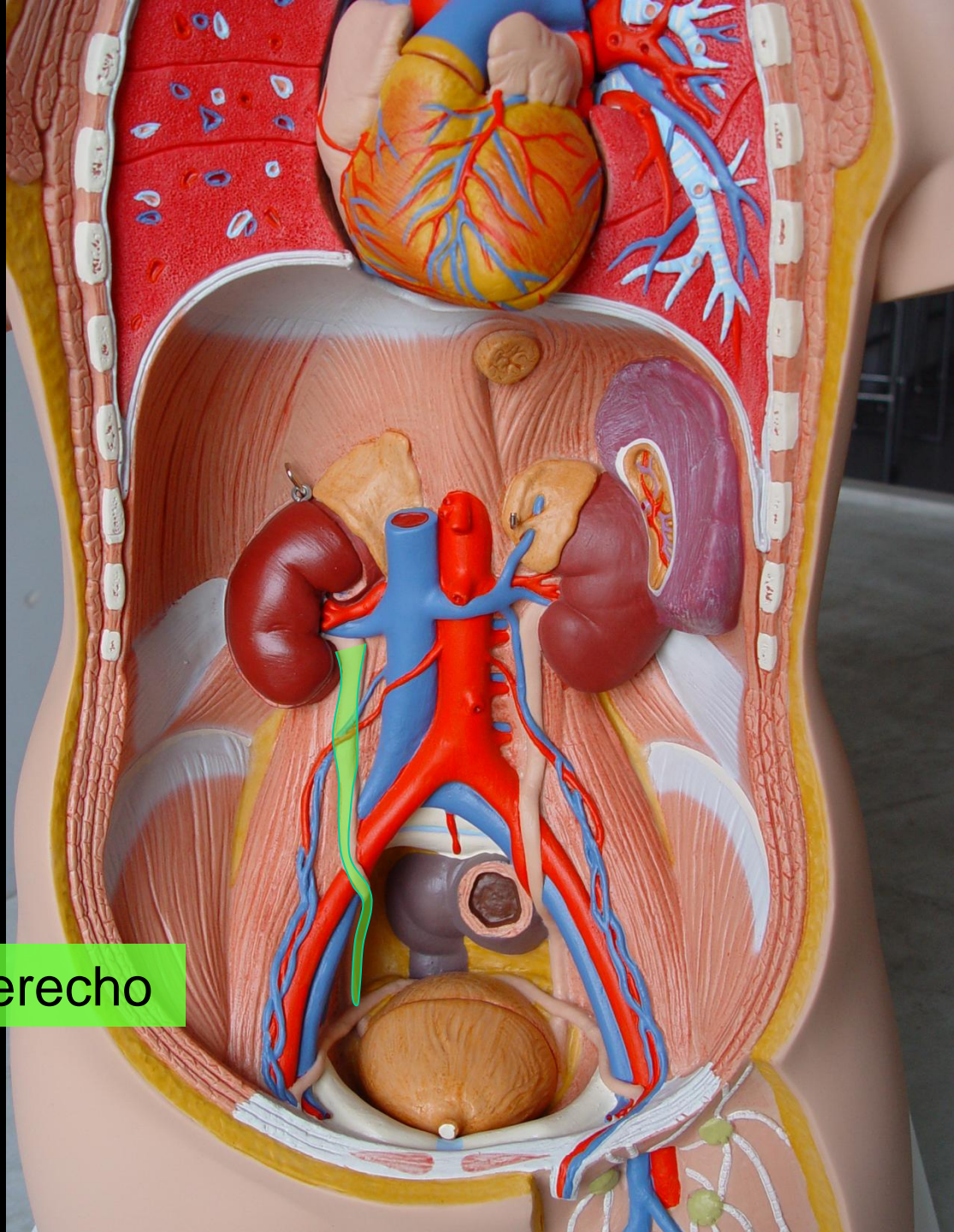
Arterias testiculares
(u ováricas)

AORTA
ABDOMINAL

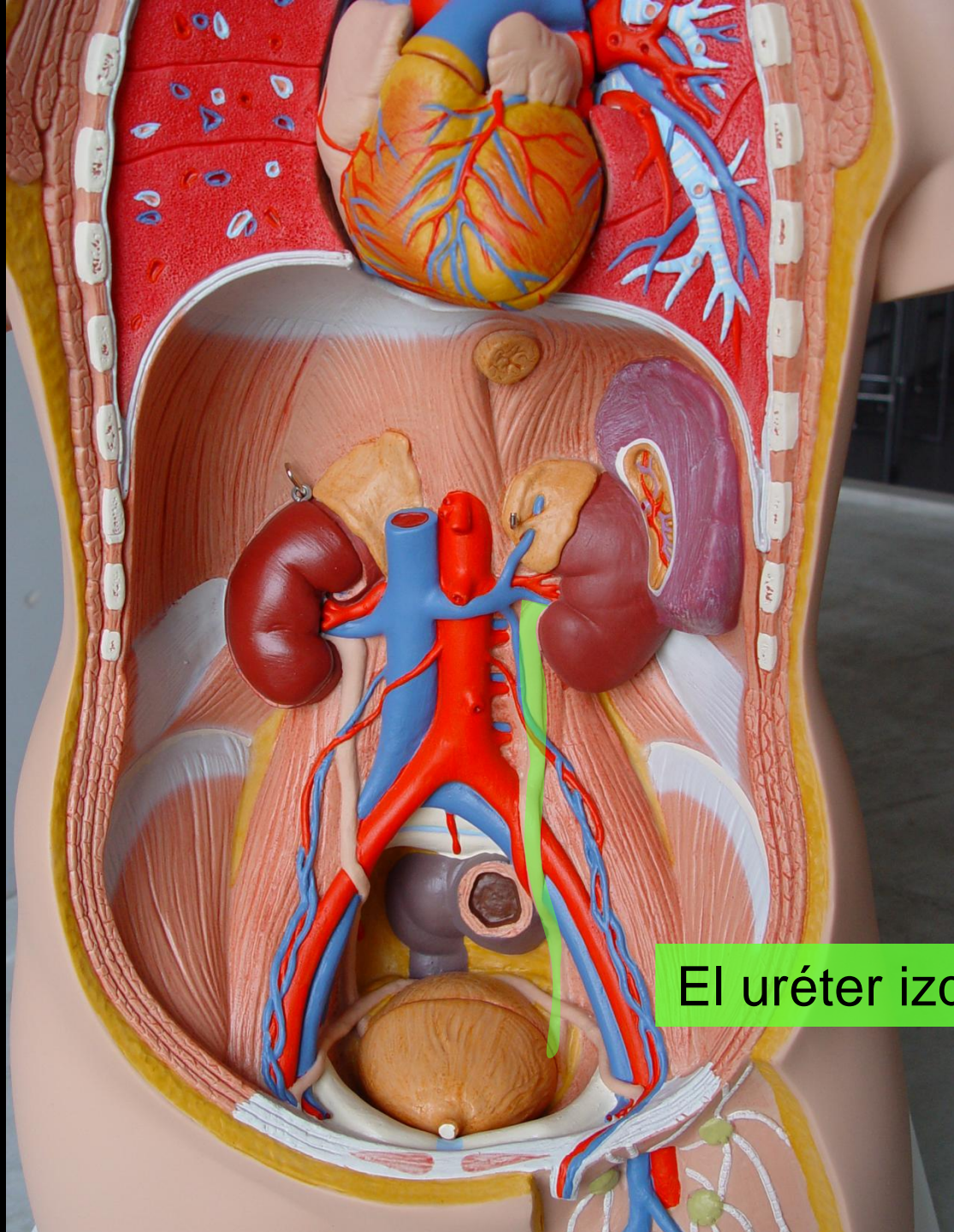
An anatomical model of the human torso, showing the abdominal cavity. The abdominal aorta is the central red vessel, branching into the common iliac arteries. The inferior vena cava is shown in blue. The kidneys are shown in brown, and the liver and spleen are shown in reddish-brown. The model is cut open to show internal organs and vessels.

Arteria sacra media

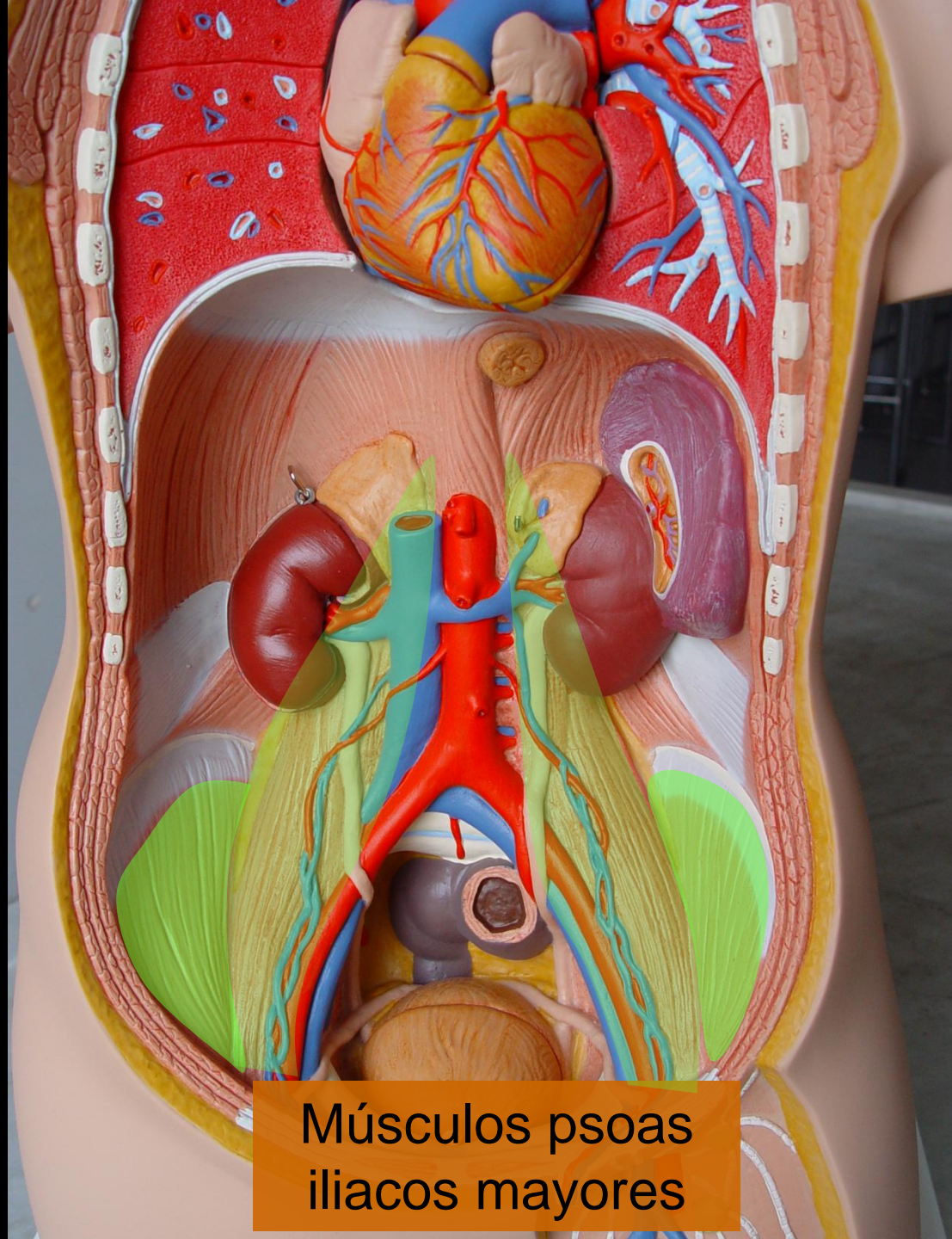
AORTA
ABDOMINAL



El uréter derecho

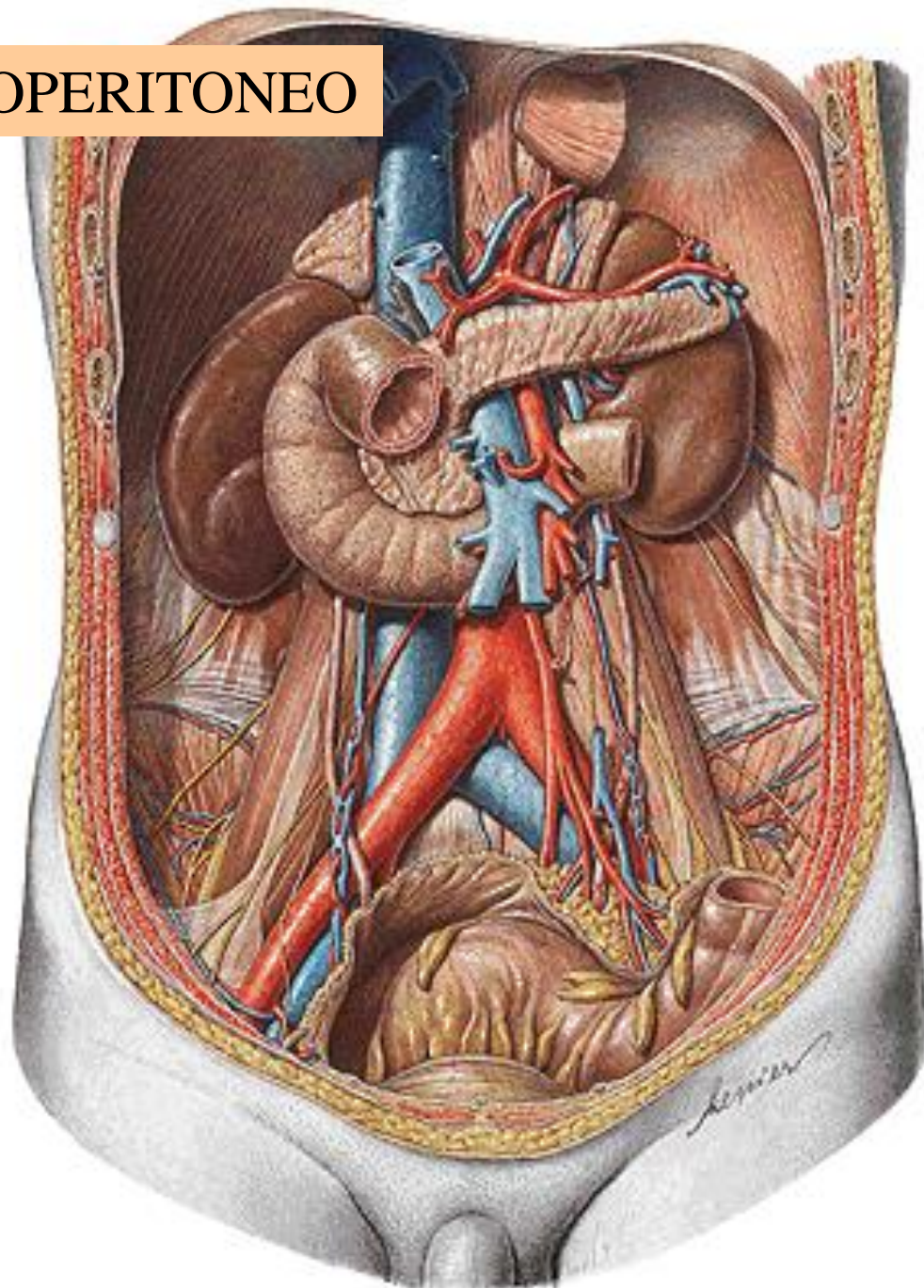


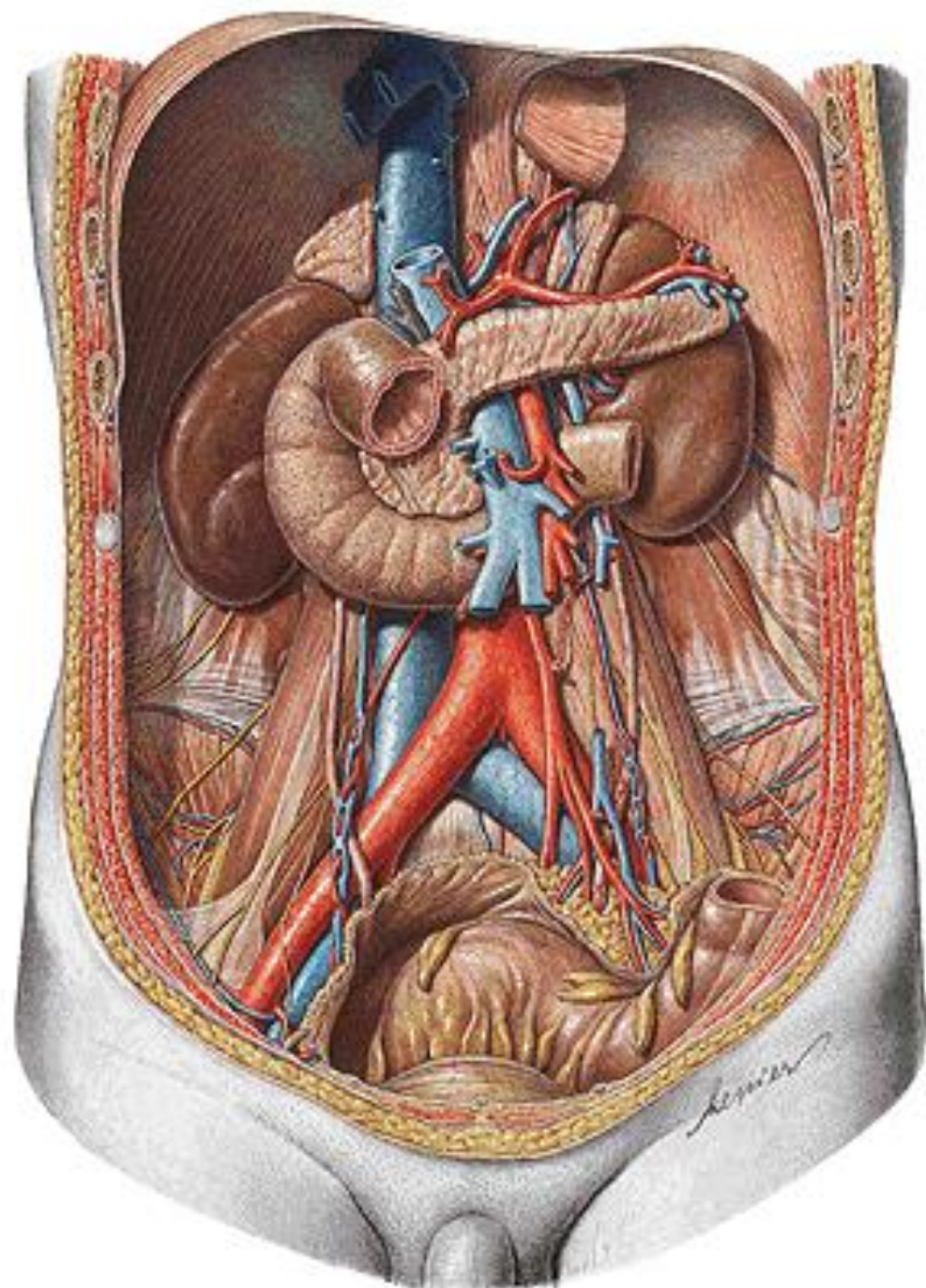
El uréter izquierdo



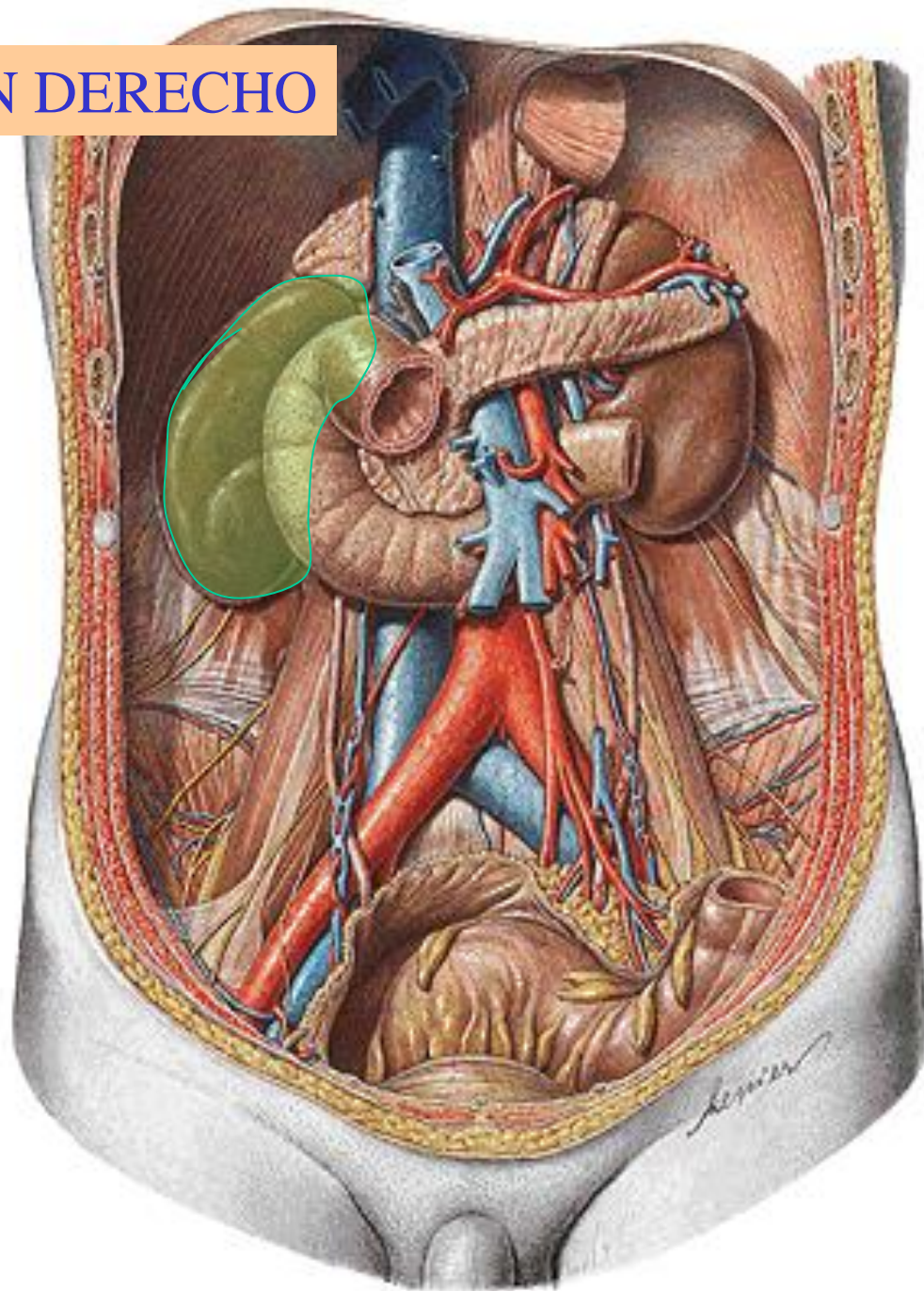
Músculos psoas
iliacos mayores

RETROPERITONEO

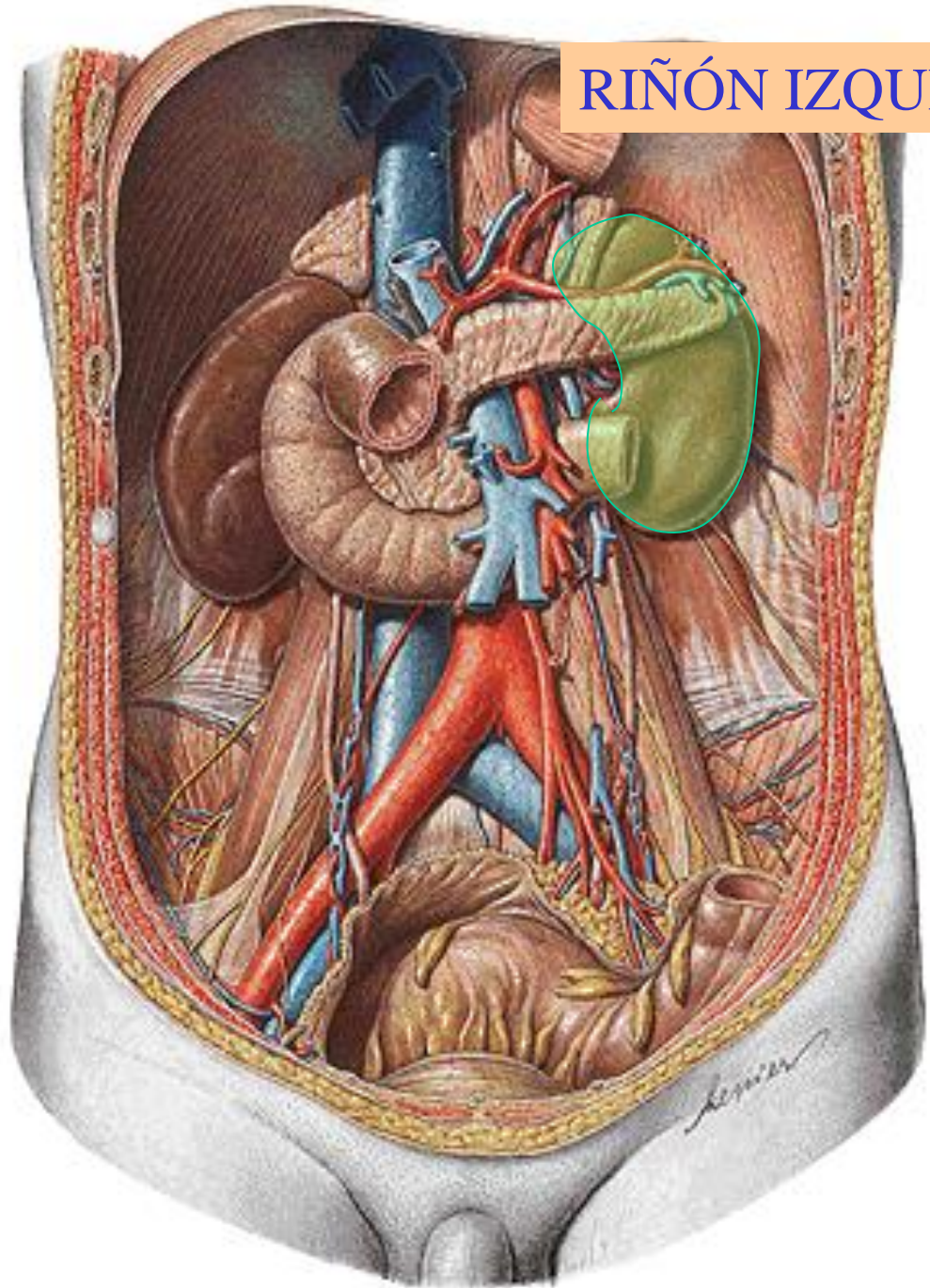




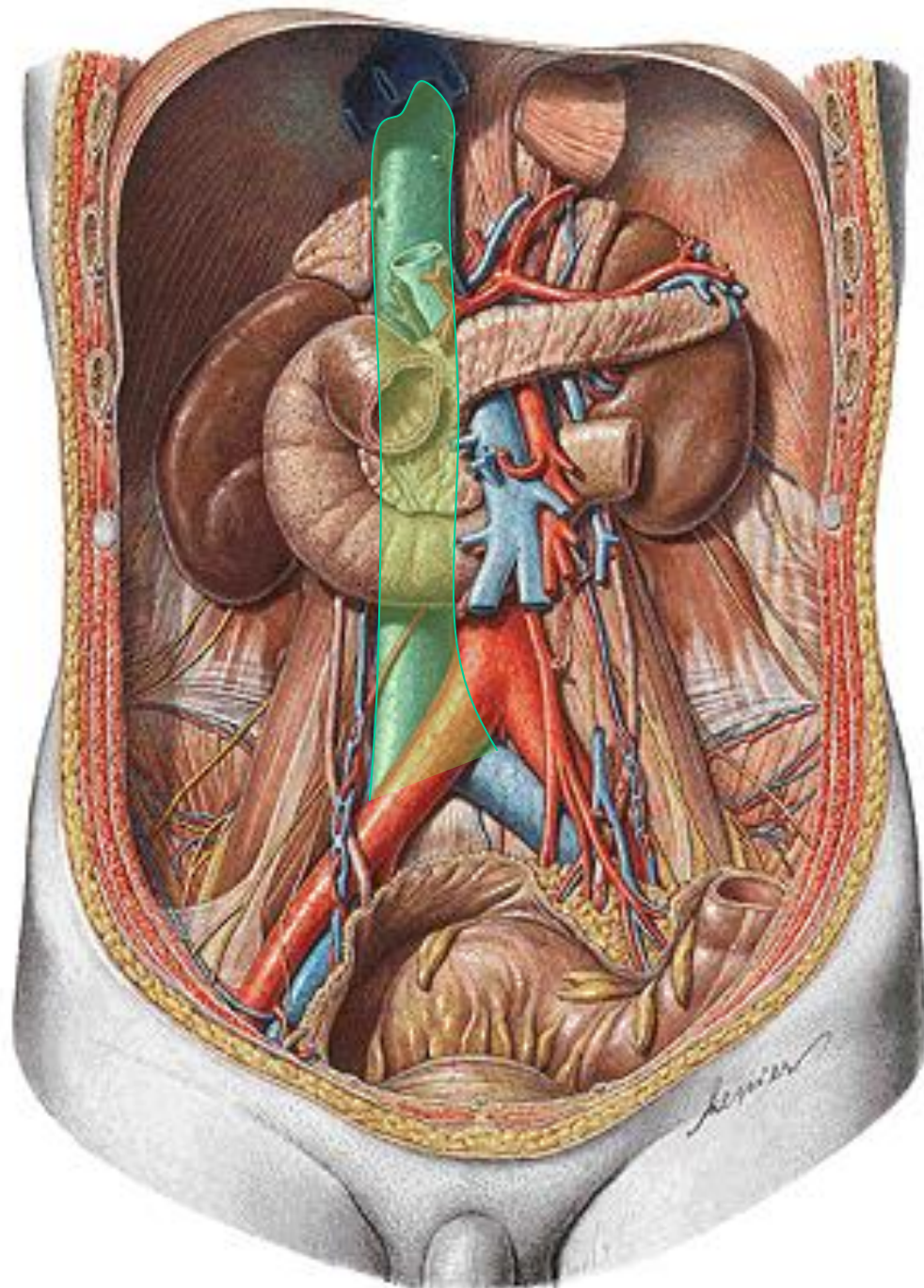
RIÑÓN DERECHO

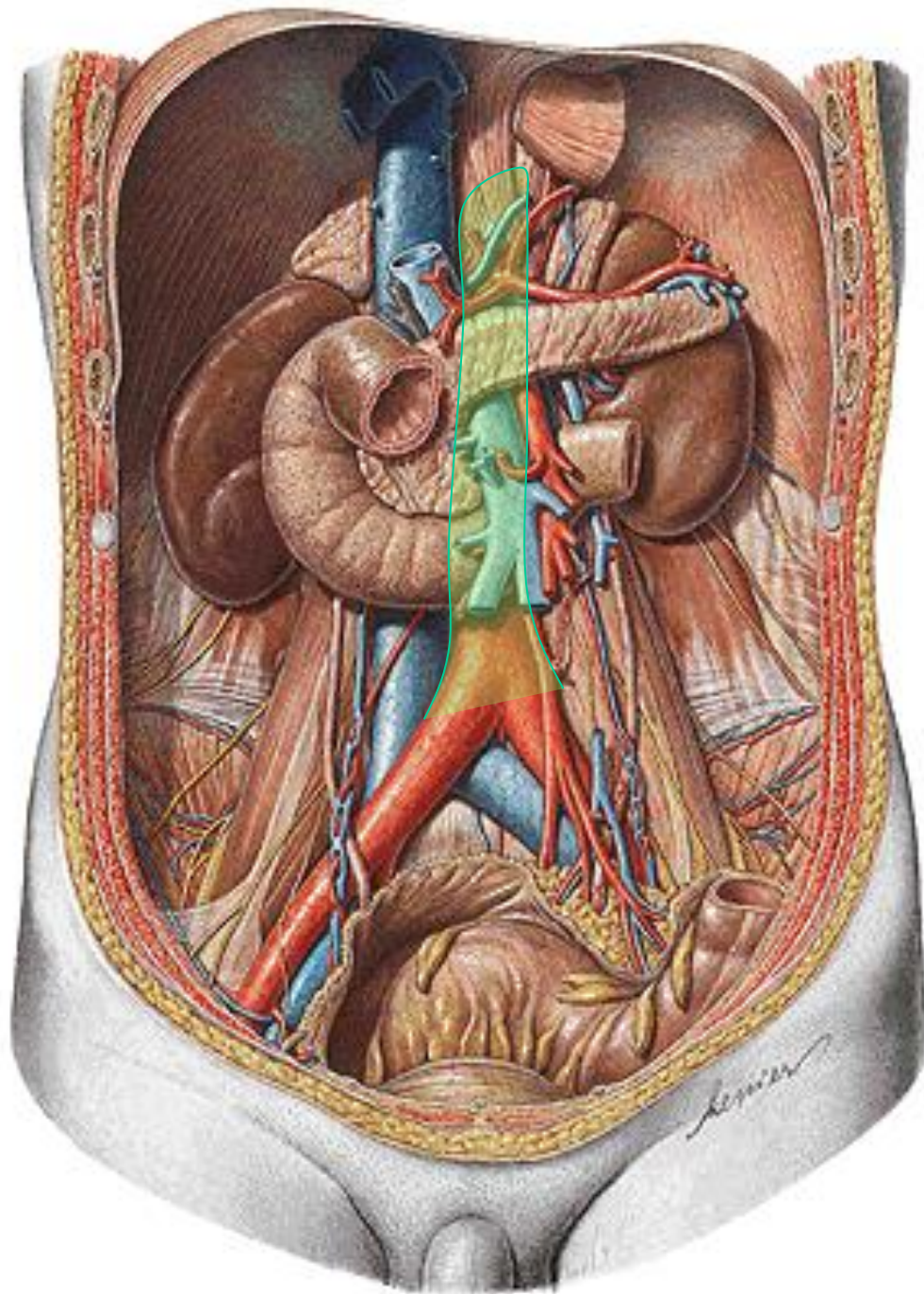


RIÑÓN IZQUIERDO

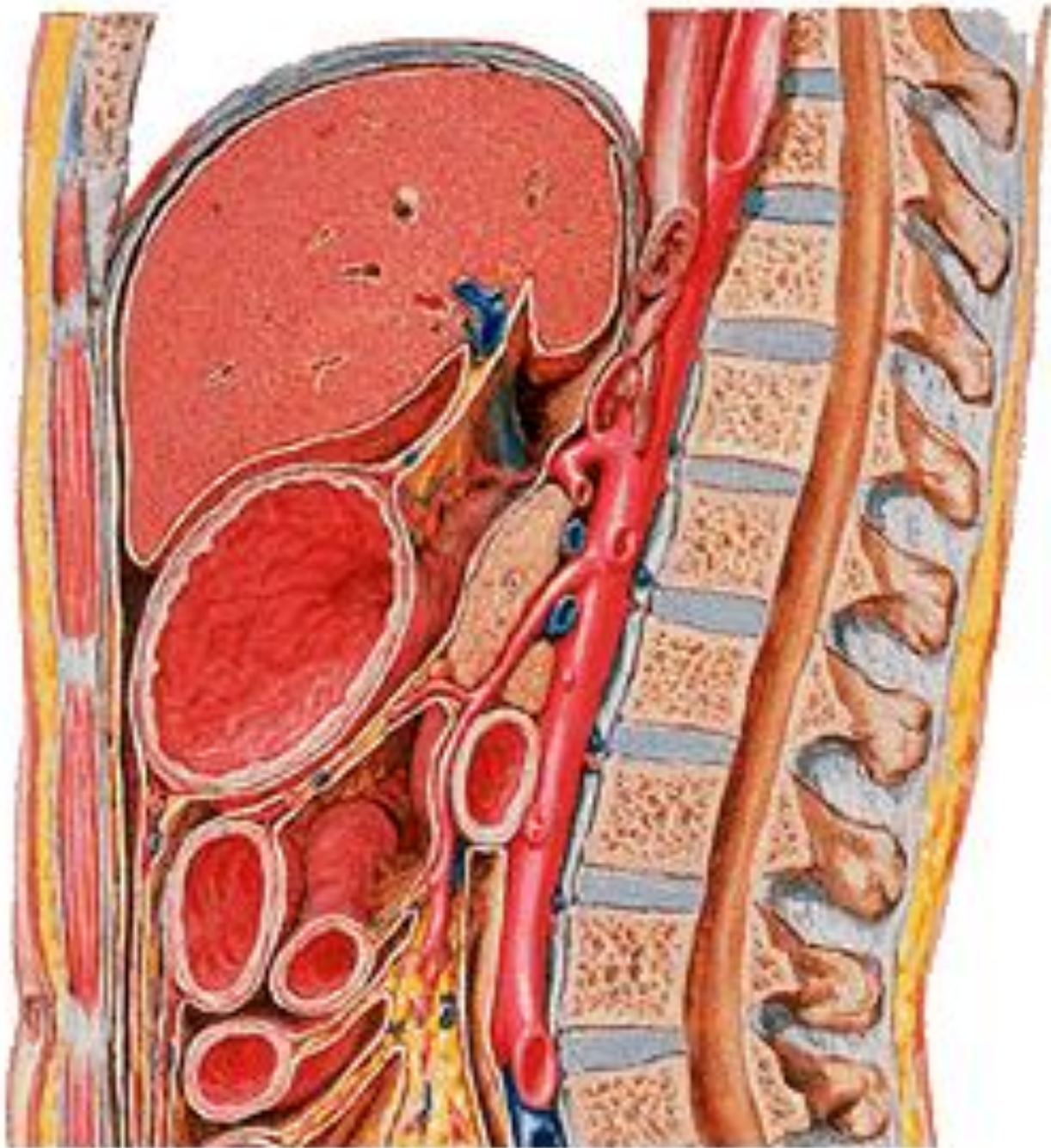


CAVA
INFERIOR

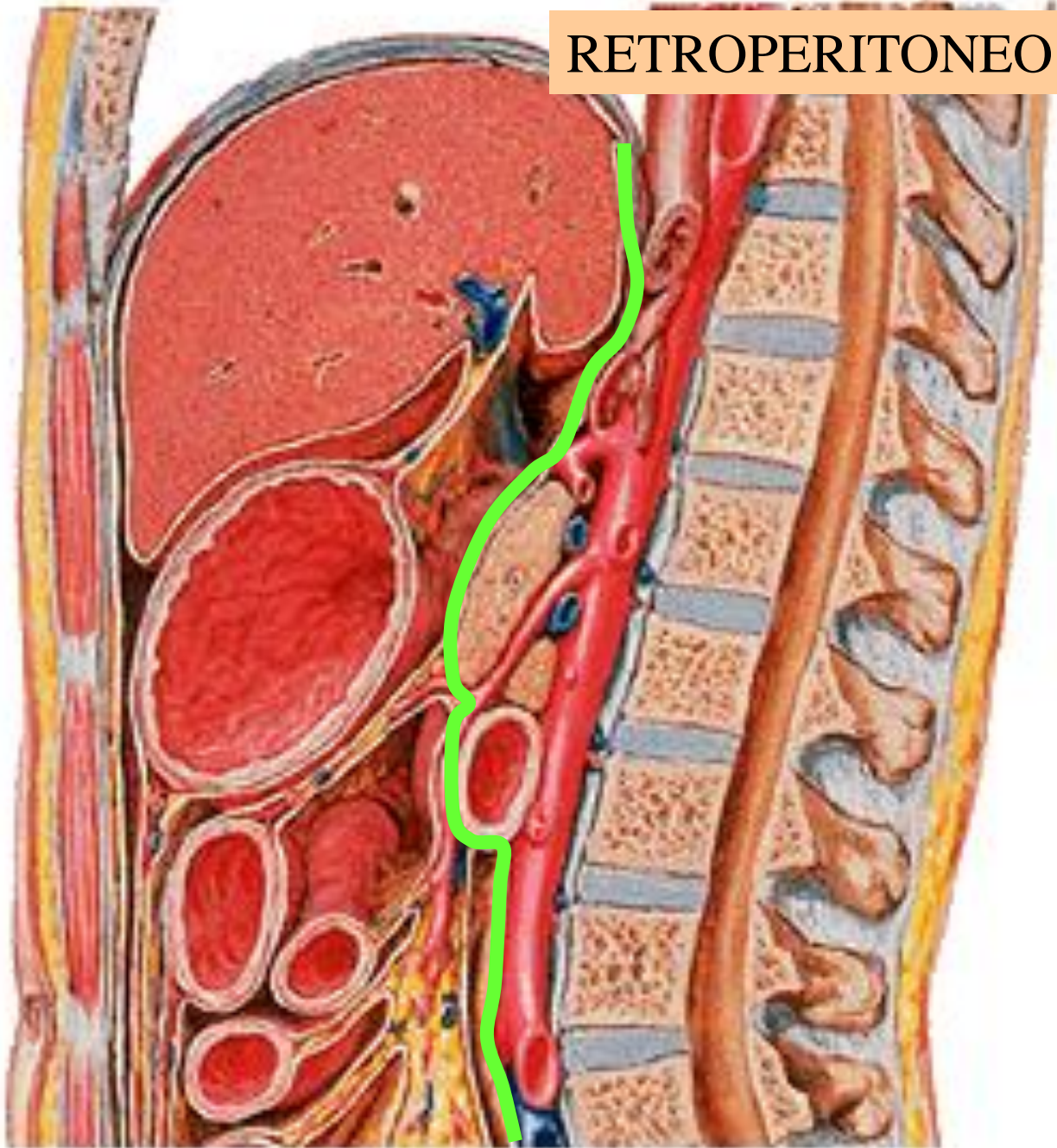


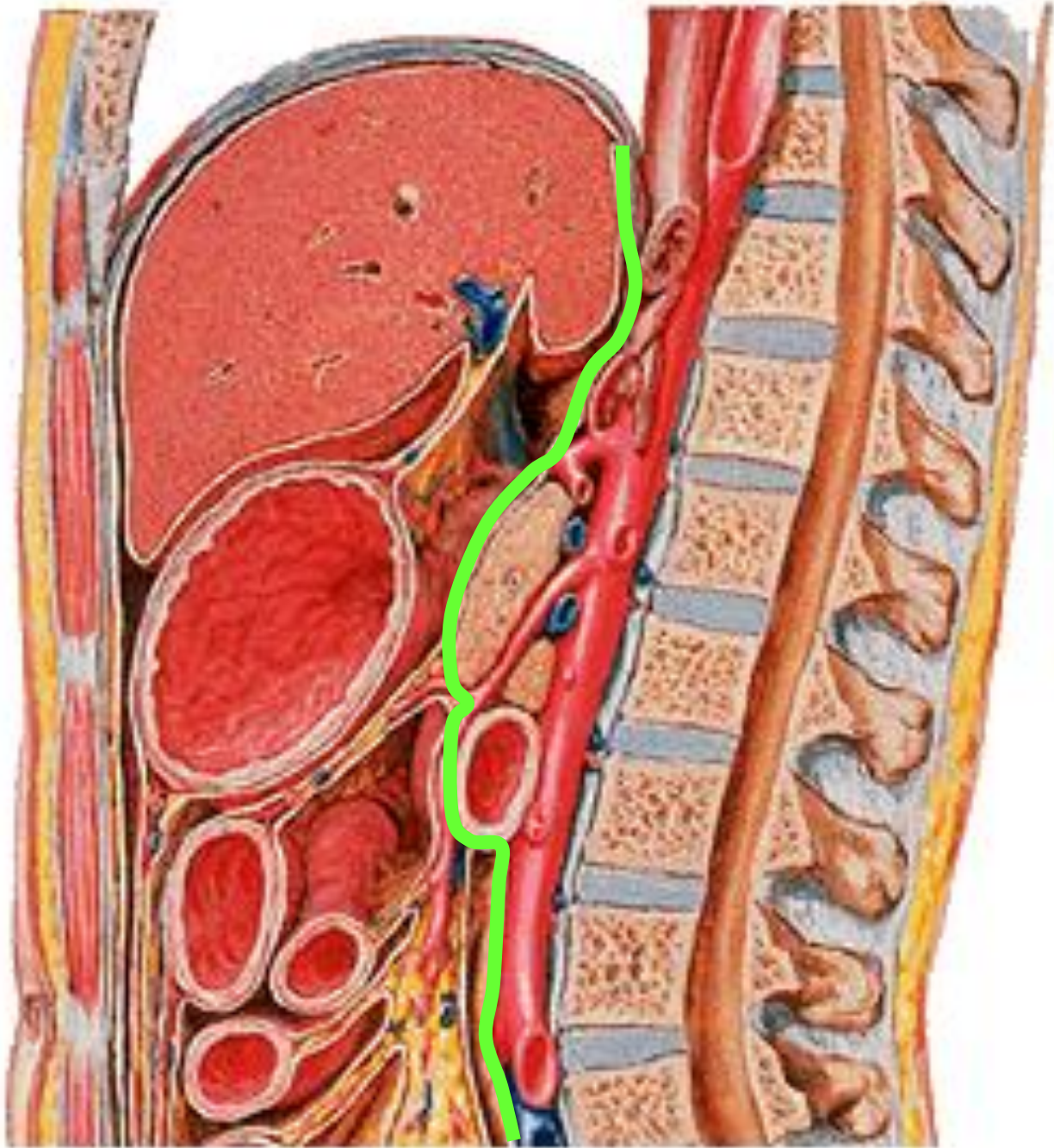


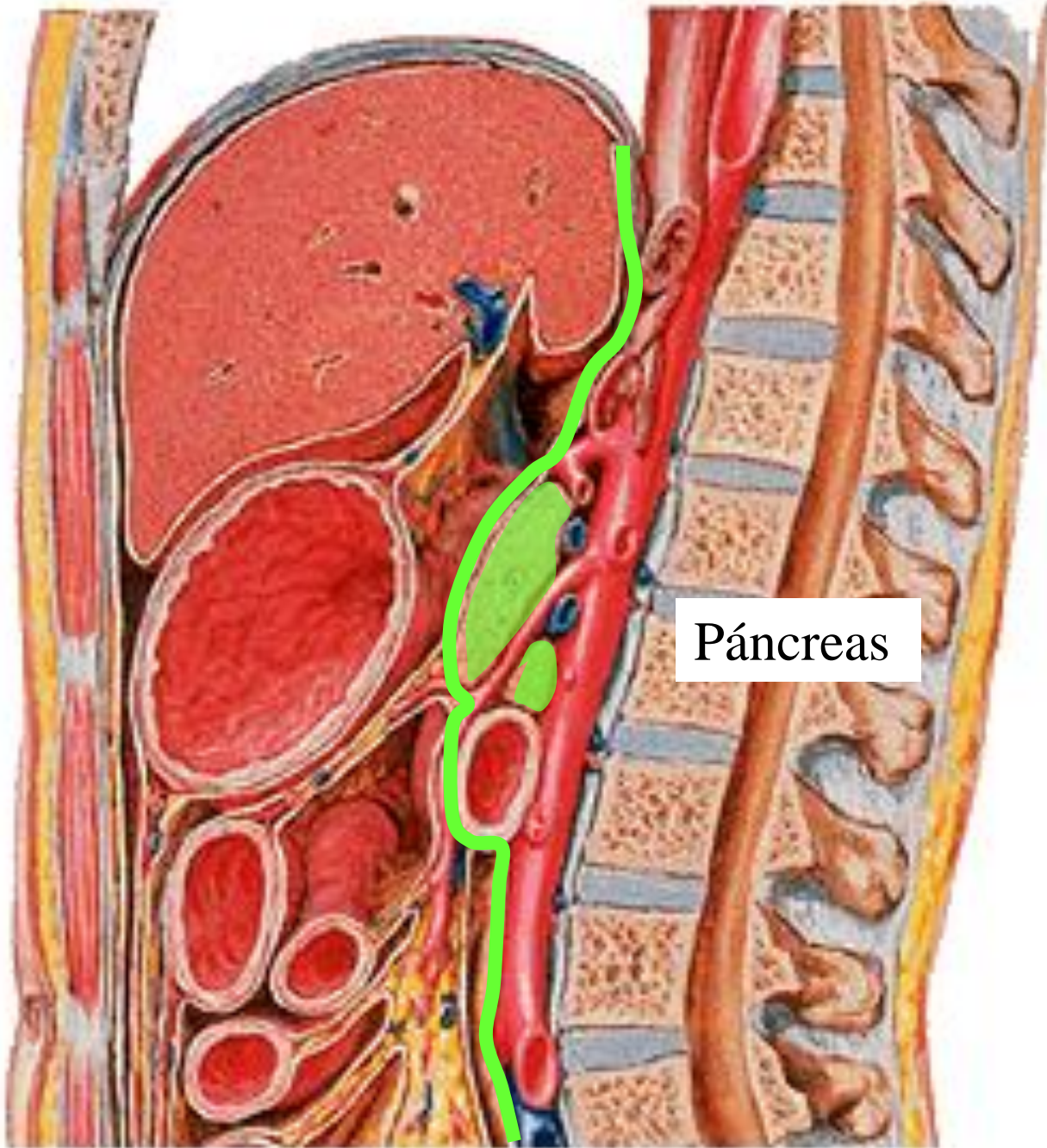
**AORTA
ABDOMINAL**



RETROPERITONEO

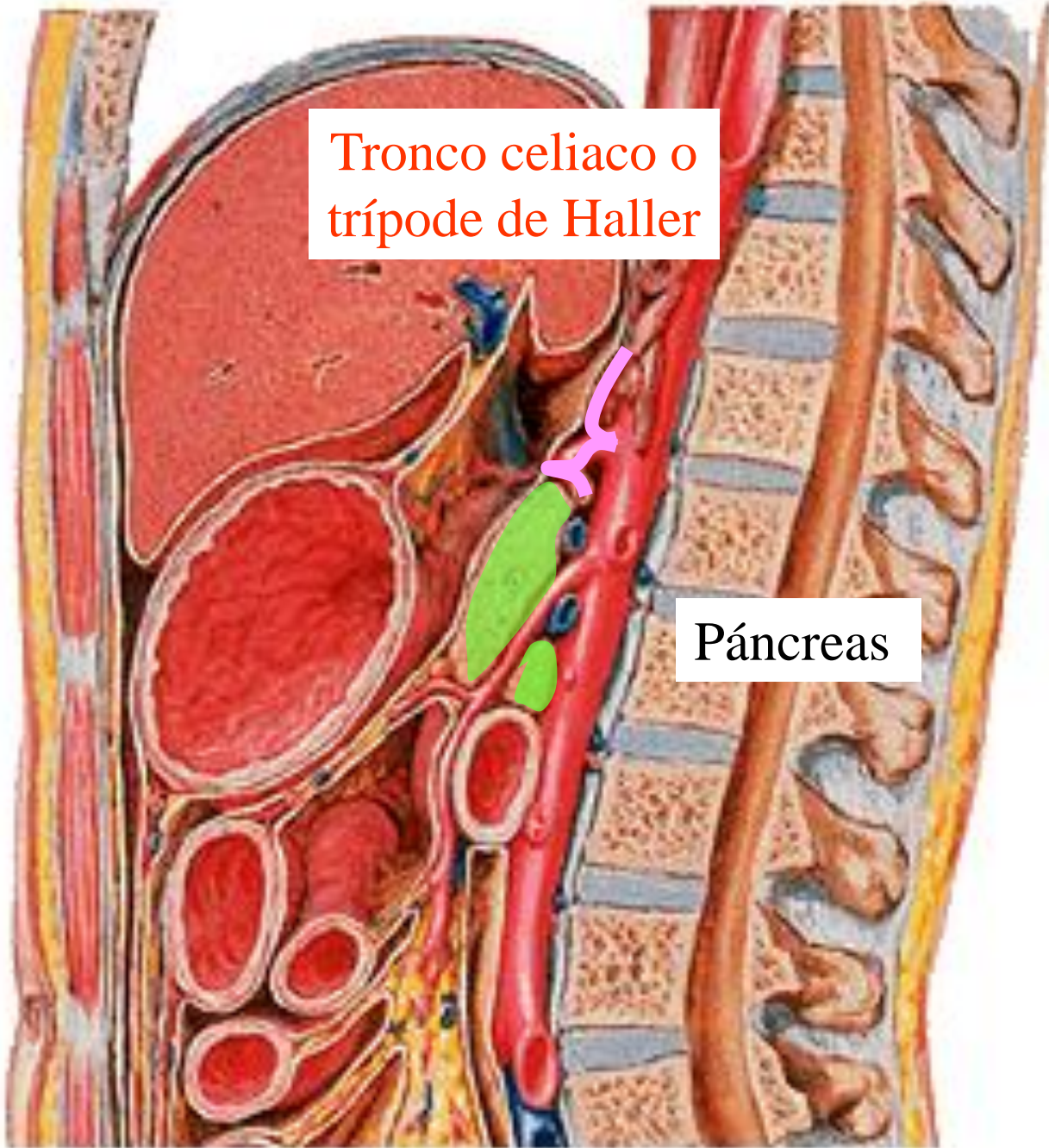




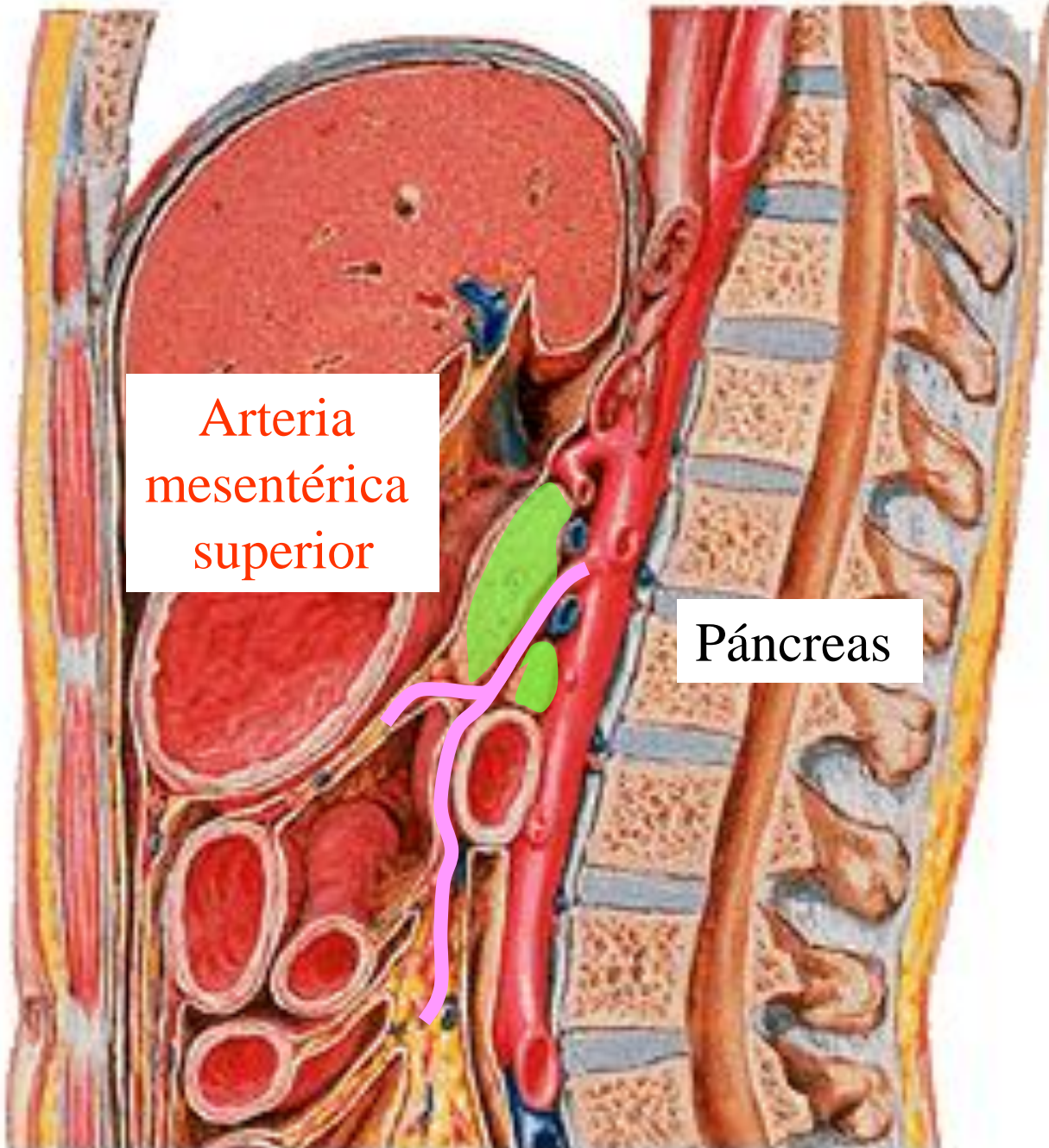


Páncreas

Tronco celiaco o
trípode de Haller

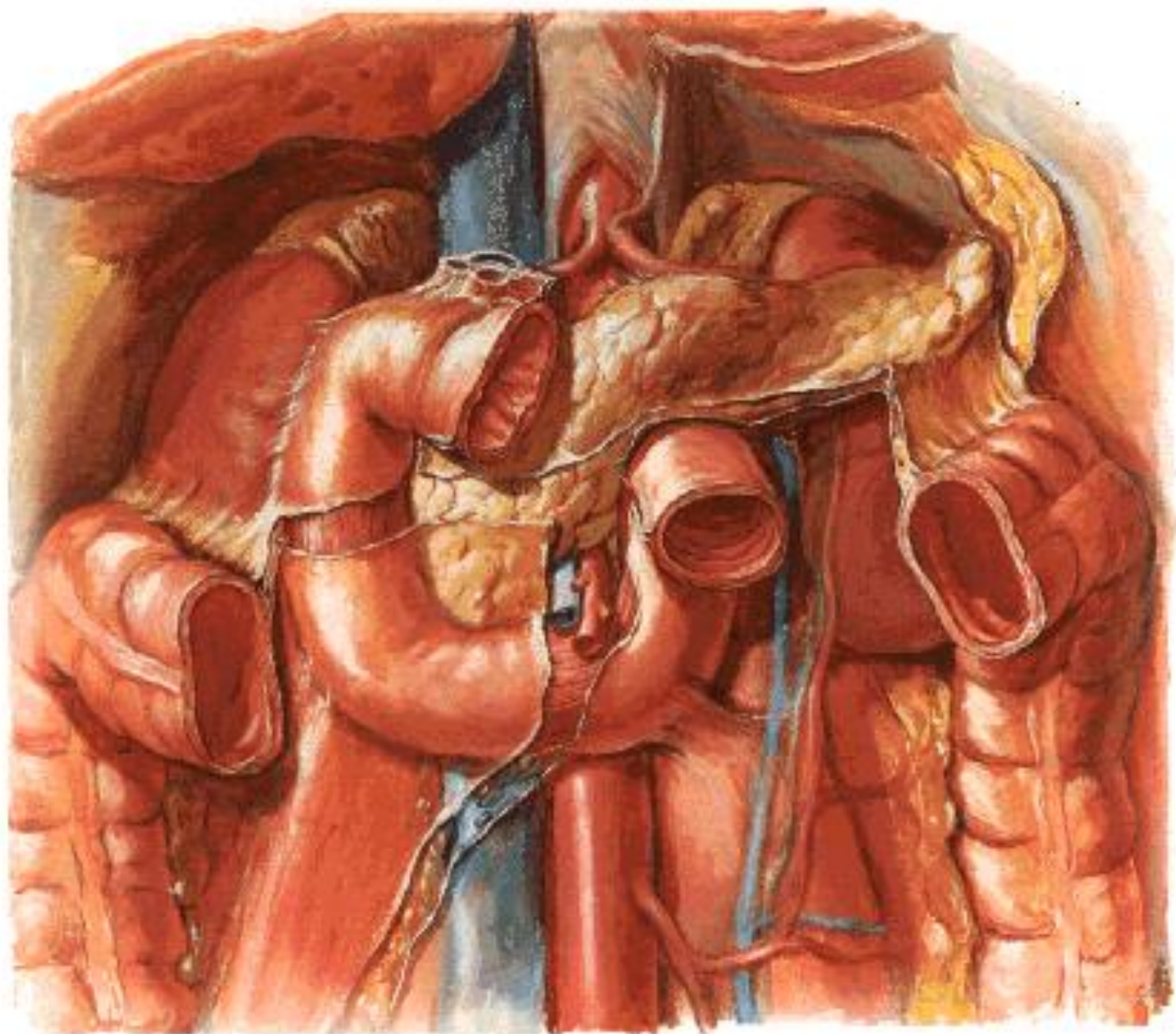


Páncreas

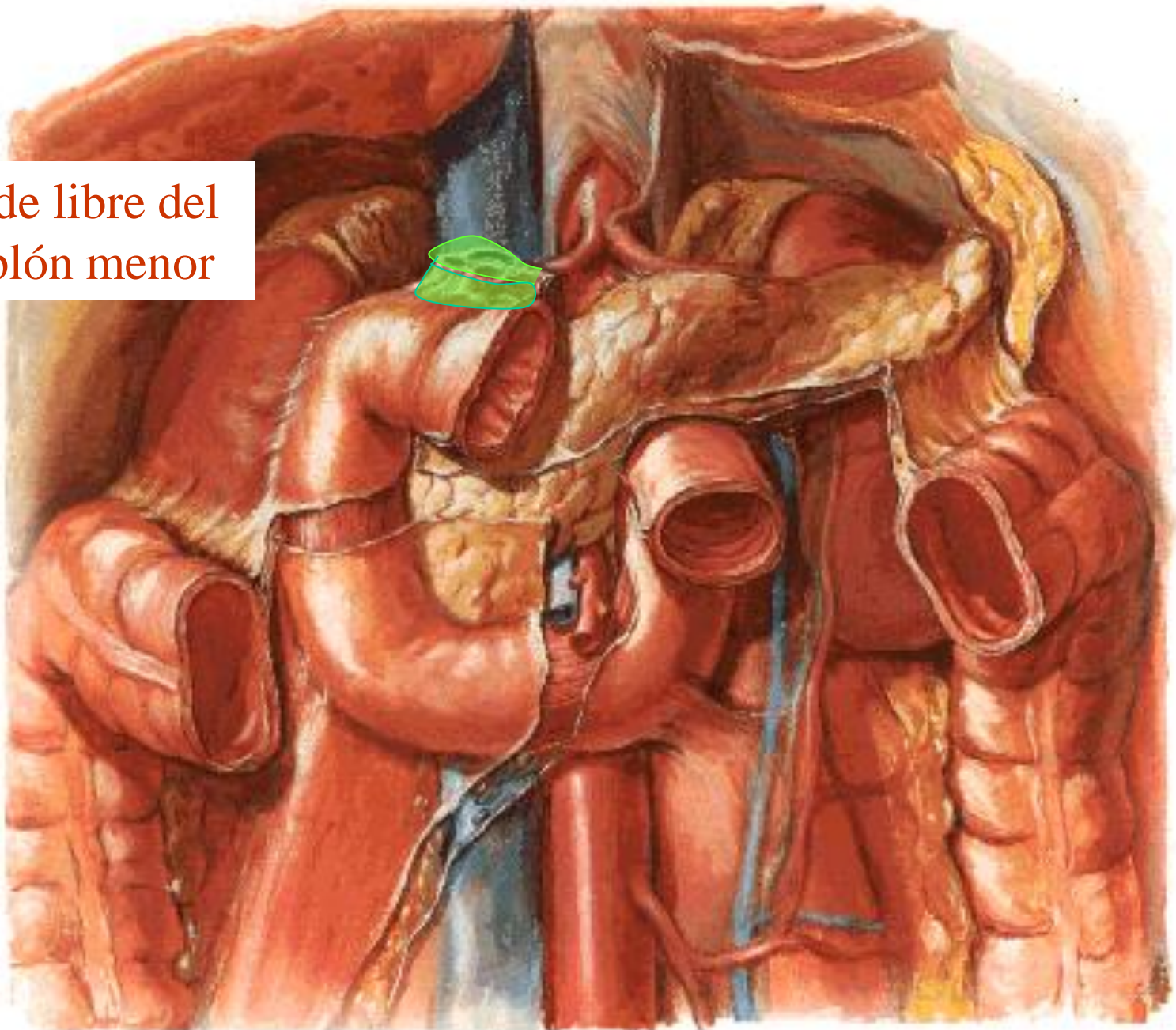


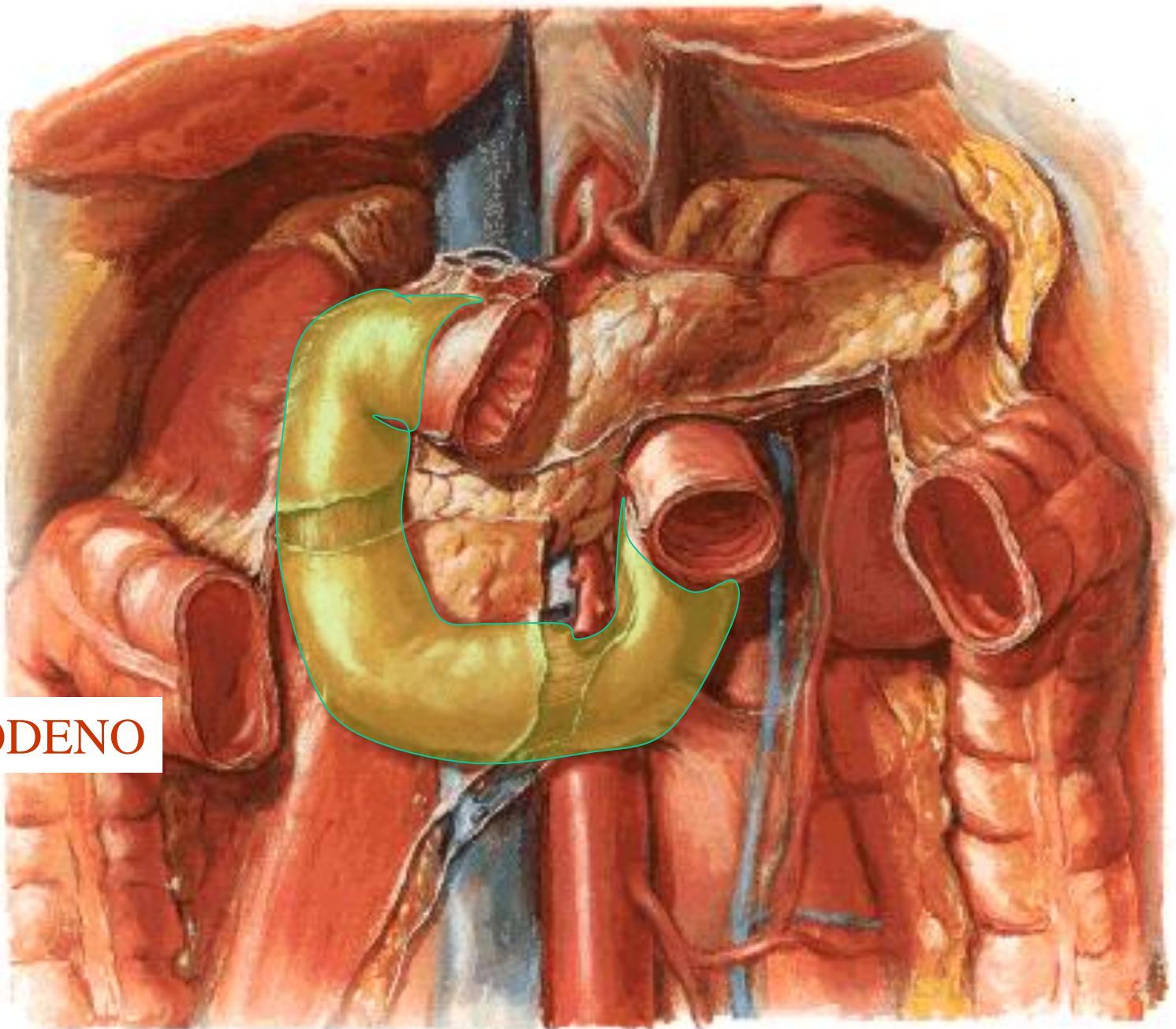
Arteria
mesentérica
superior

Páncreas

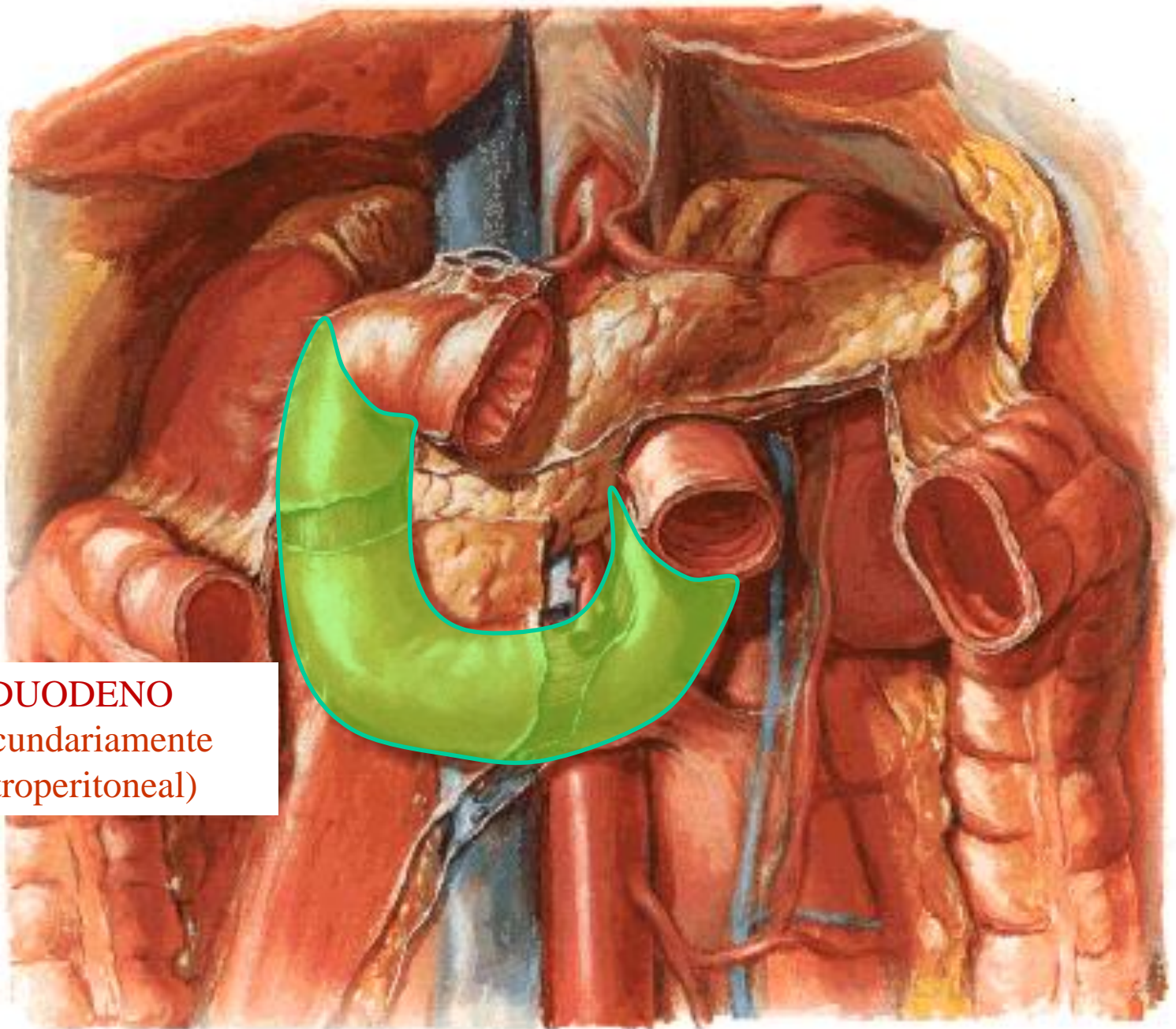


Borde libre del
epiplón menor

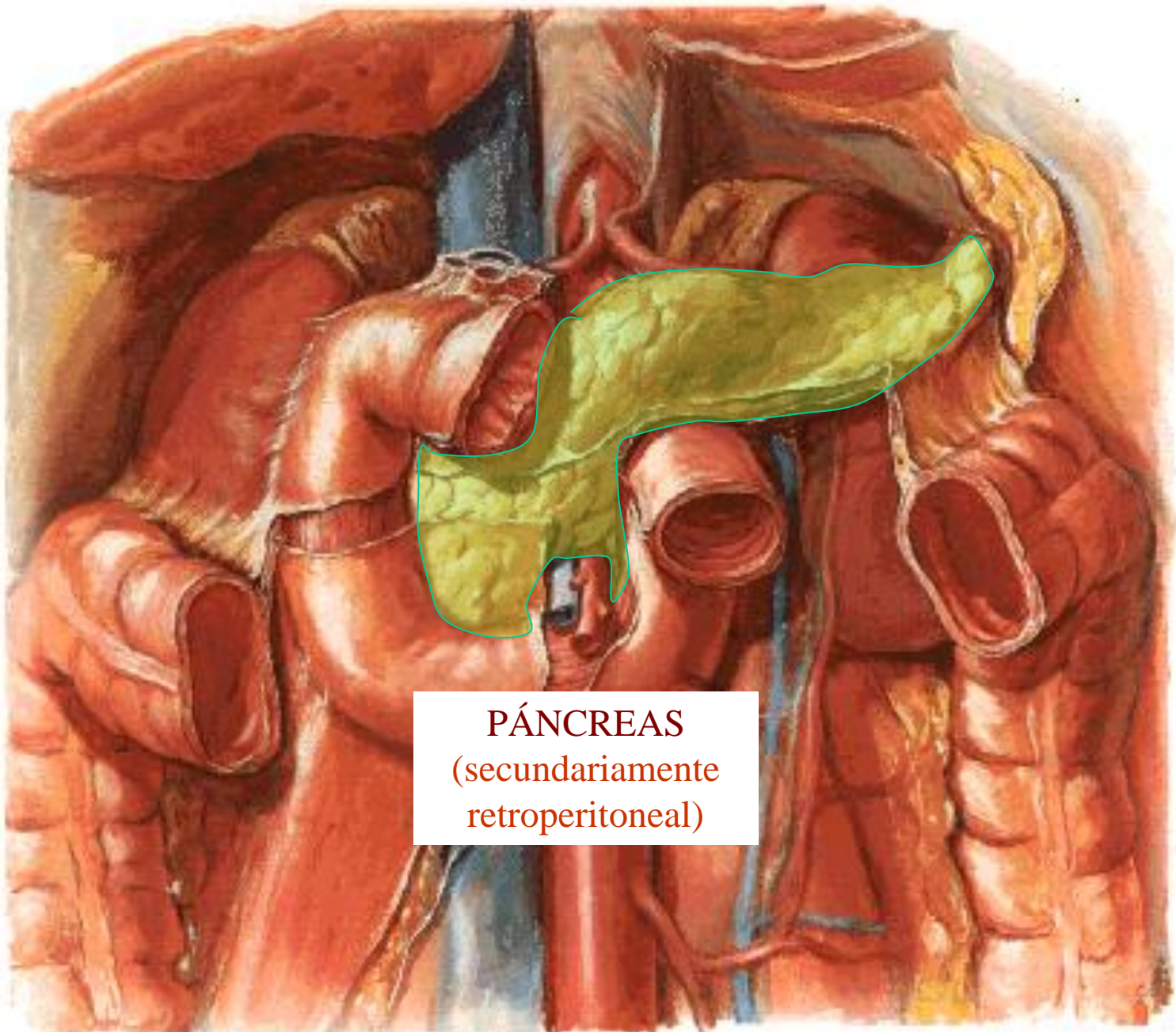




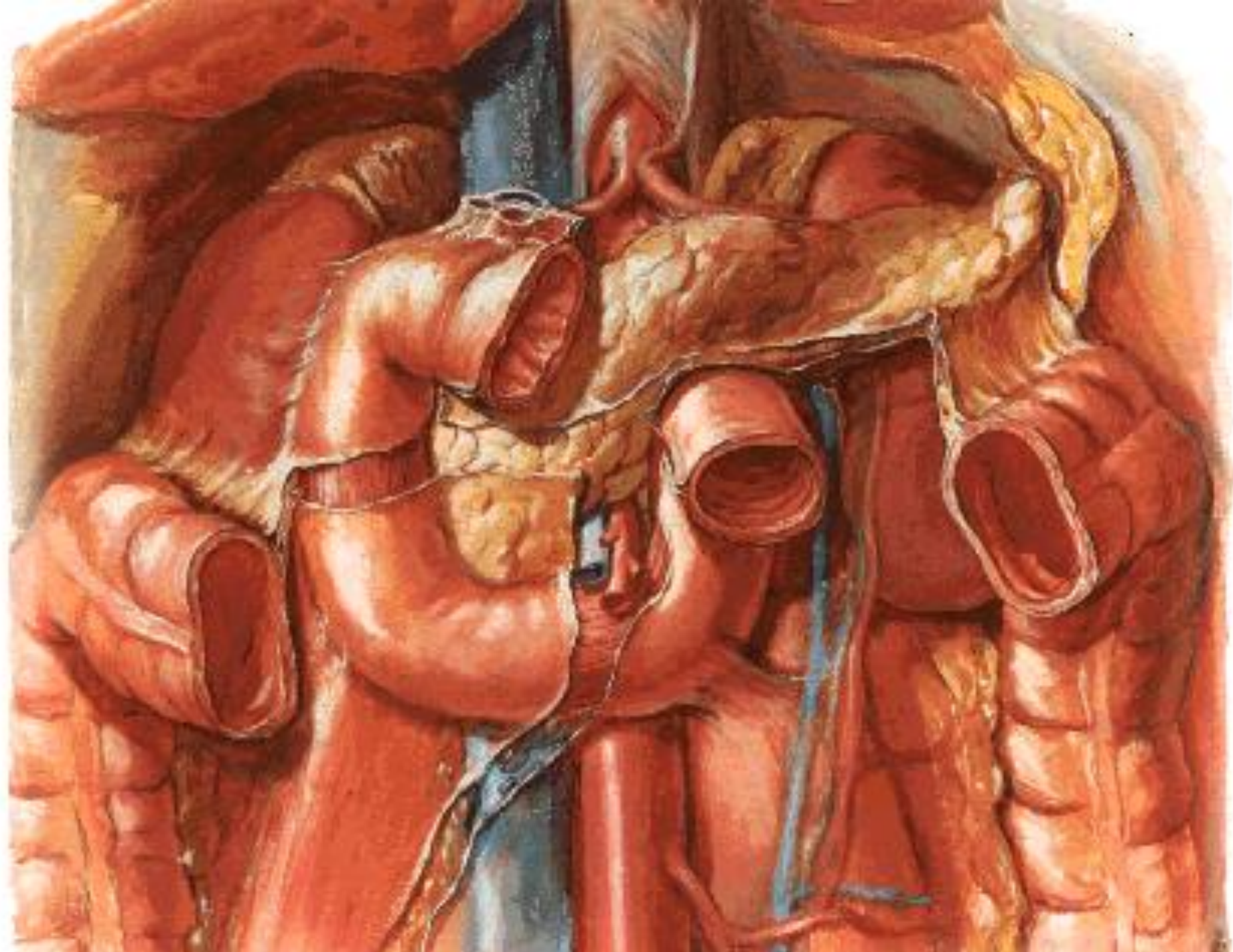
DUODENO

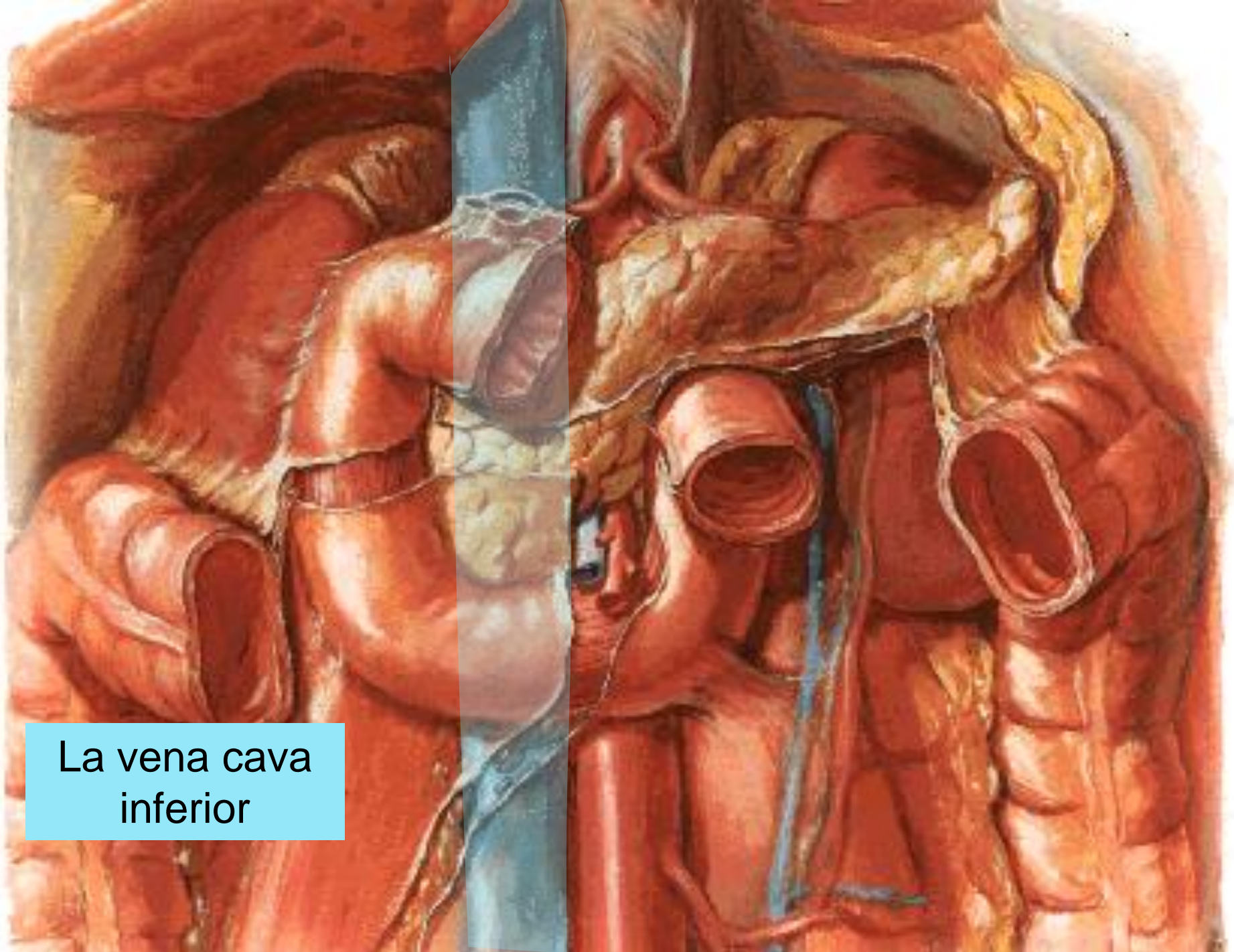


DUODENO
(secundariamente
retroperitoneal)

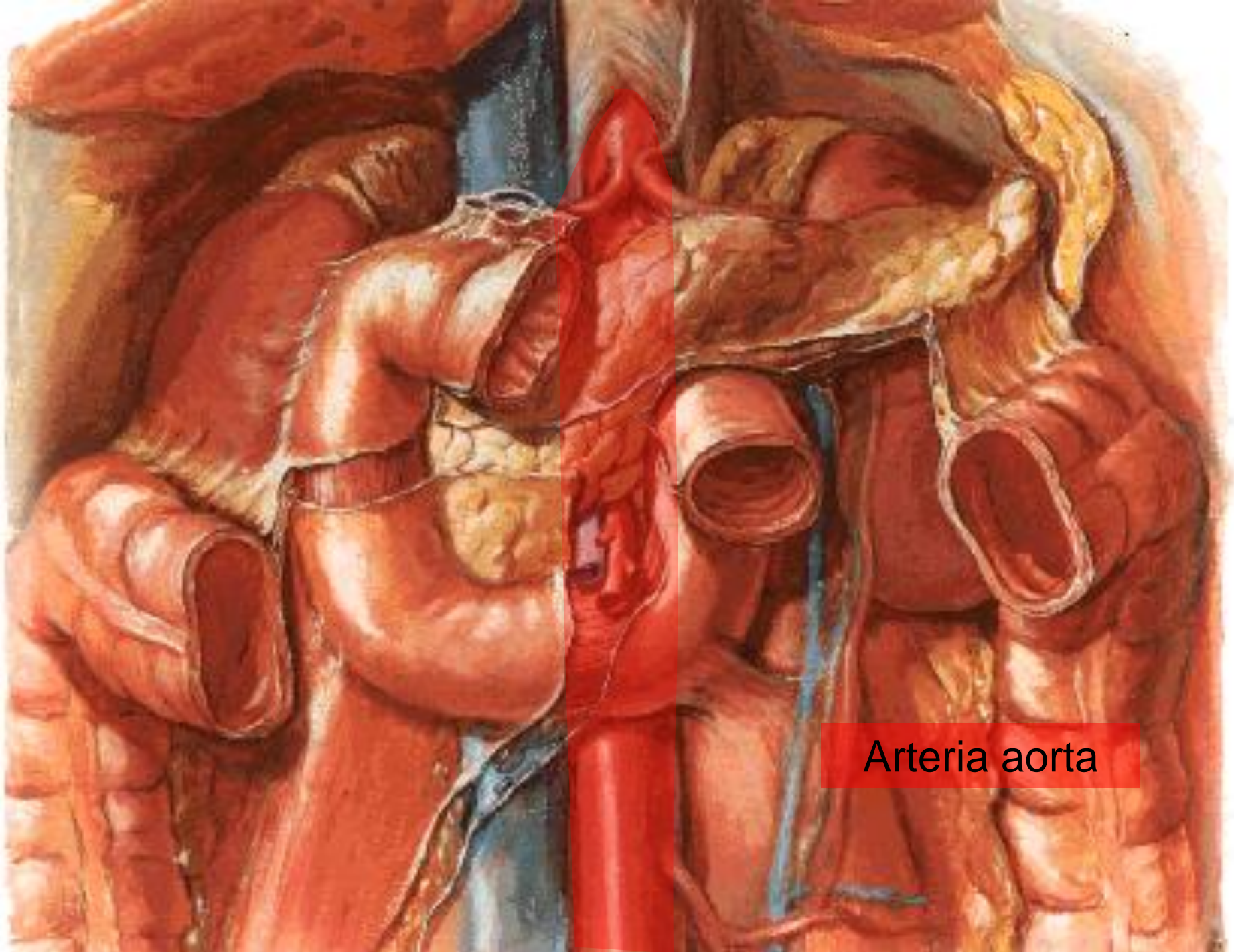


PÁNCREAS
(secundariamente
retroperitoneal)





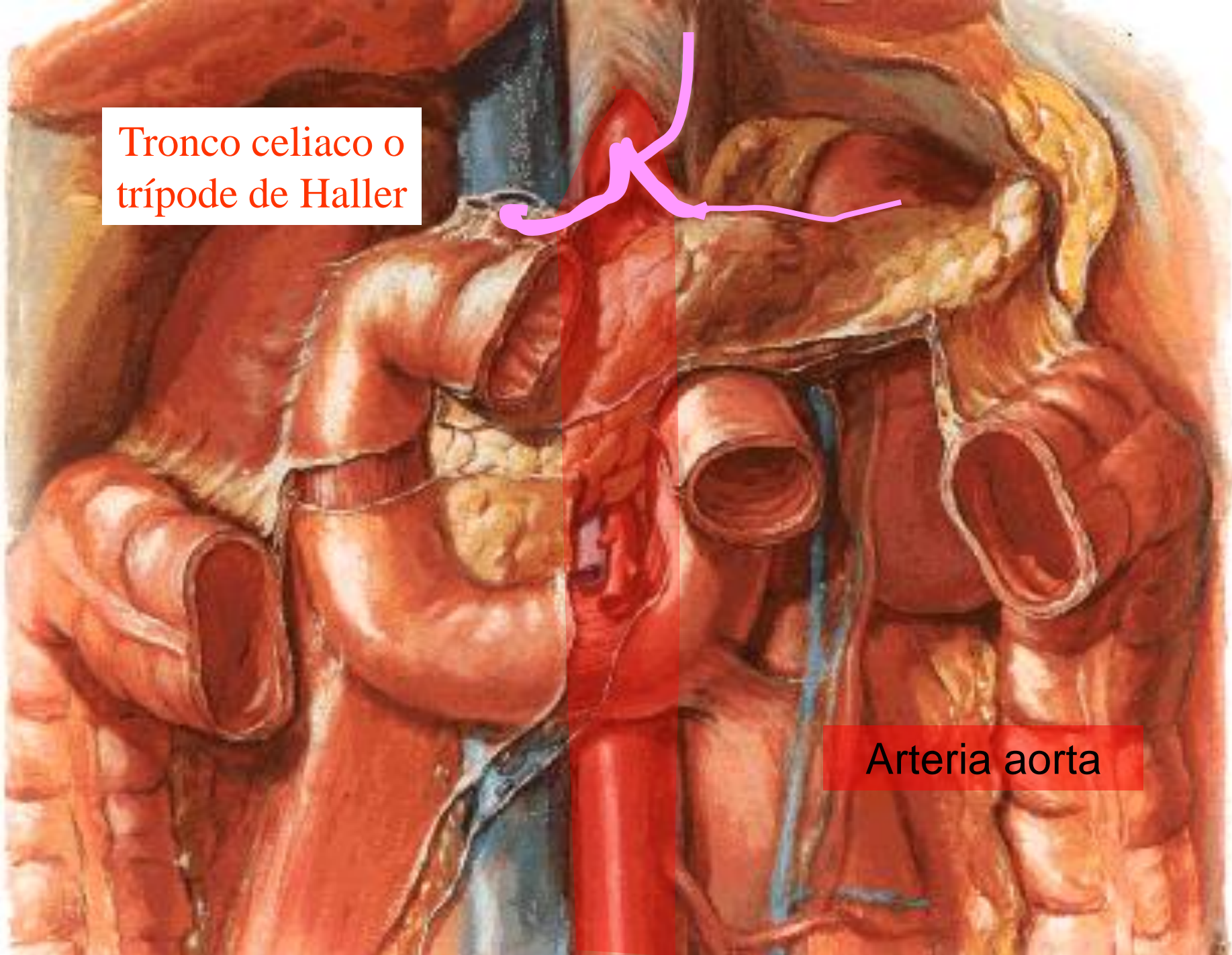
La vena cava inferior



Arteria aorta

Tronco celiaco o
trípode de Haller

Arteria aorta

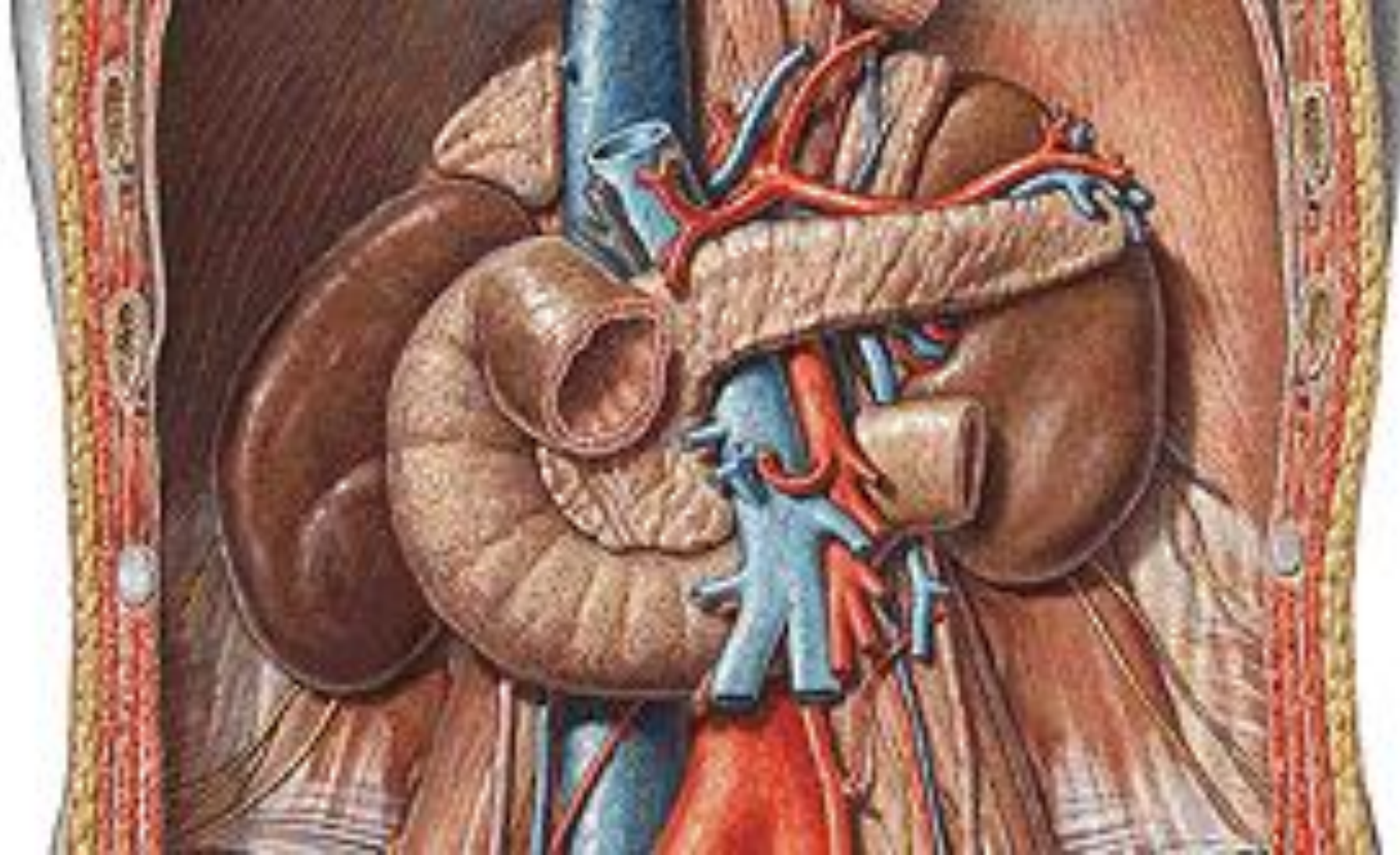


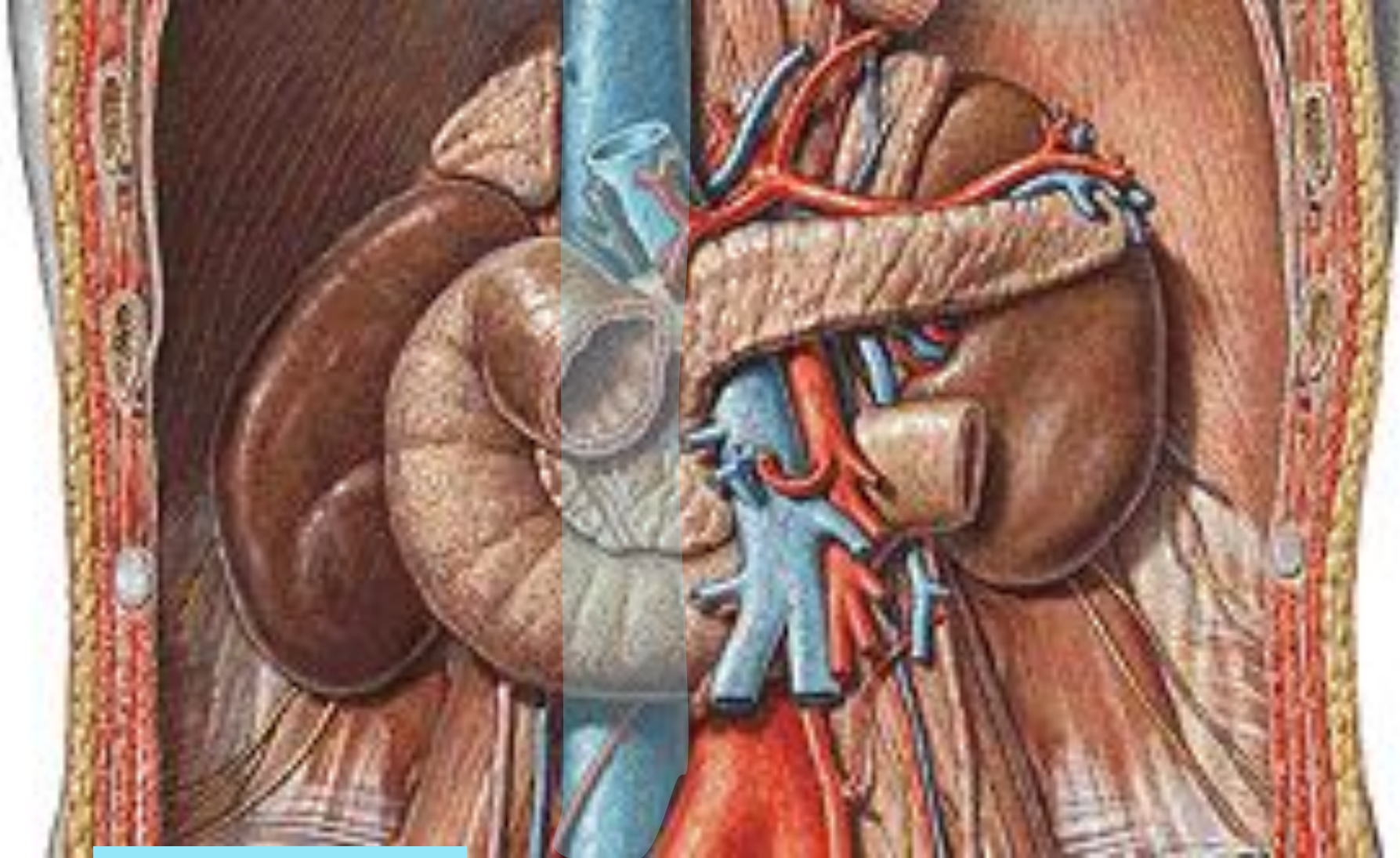


Arteria
mesentérica
superior

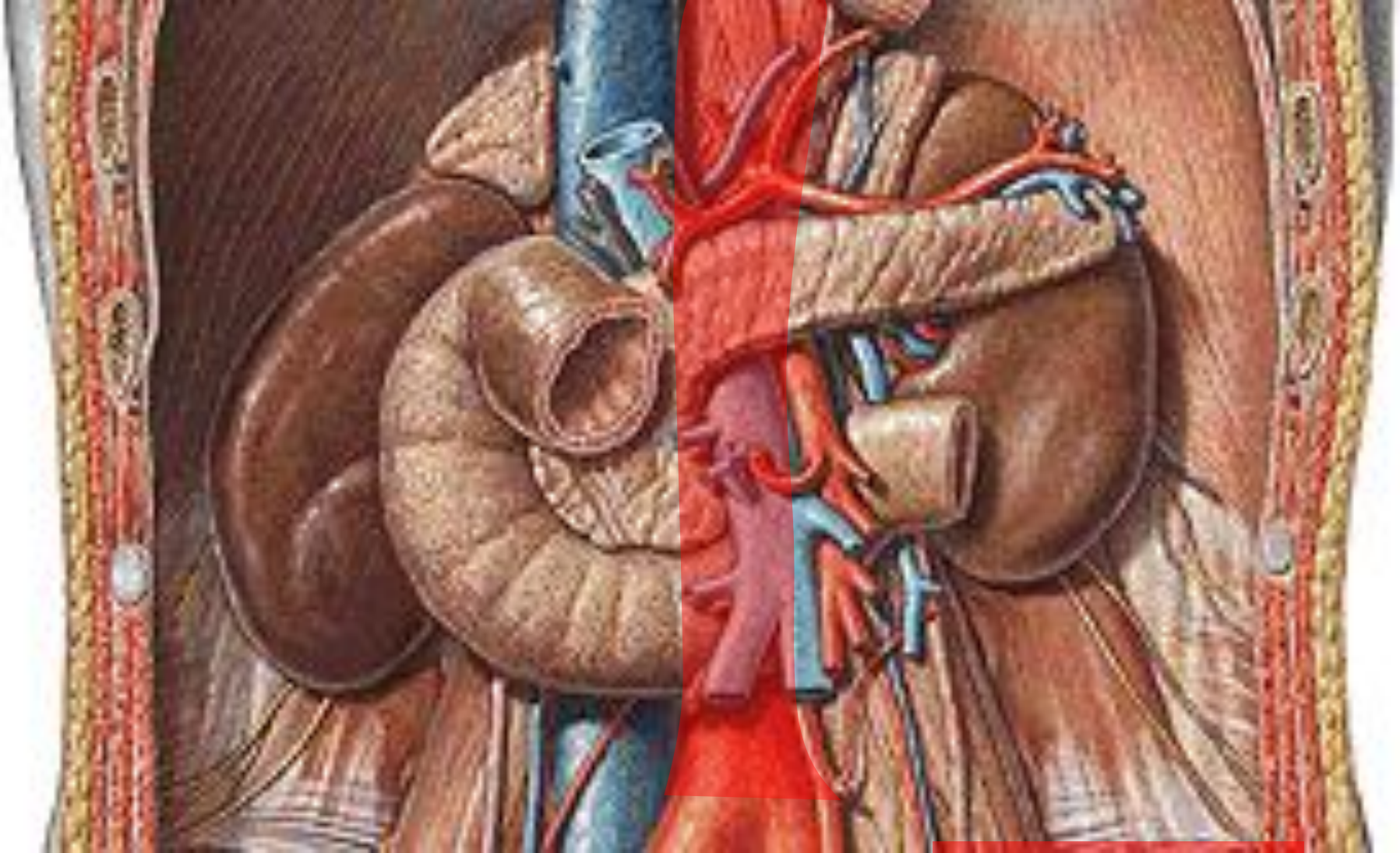


Arteria aorta

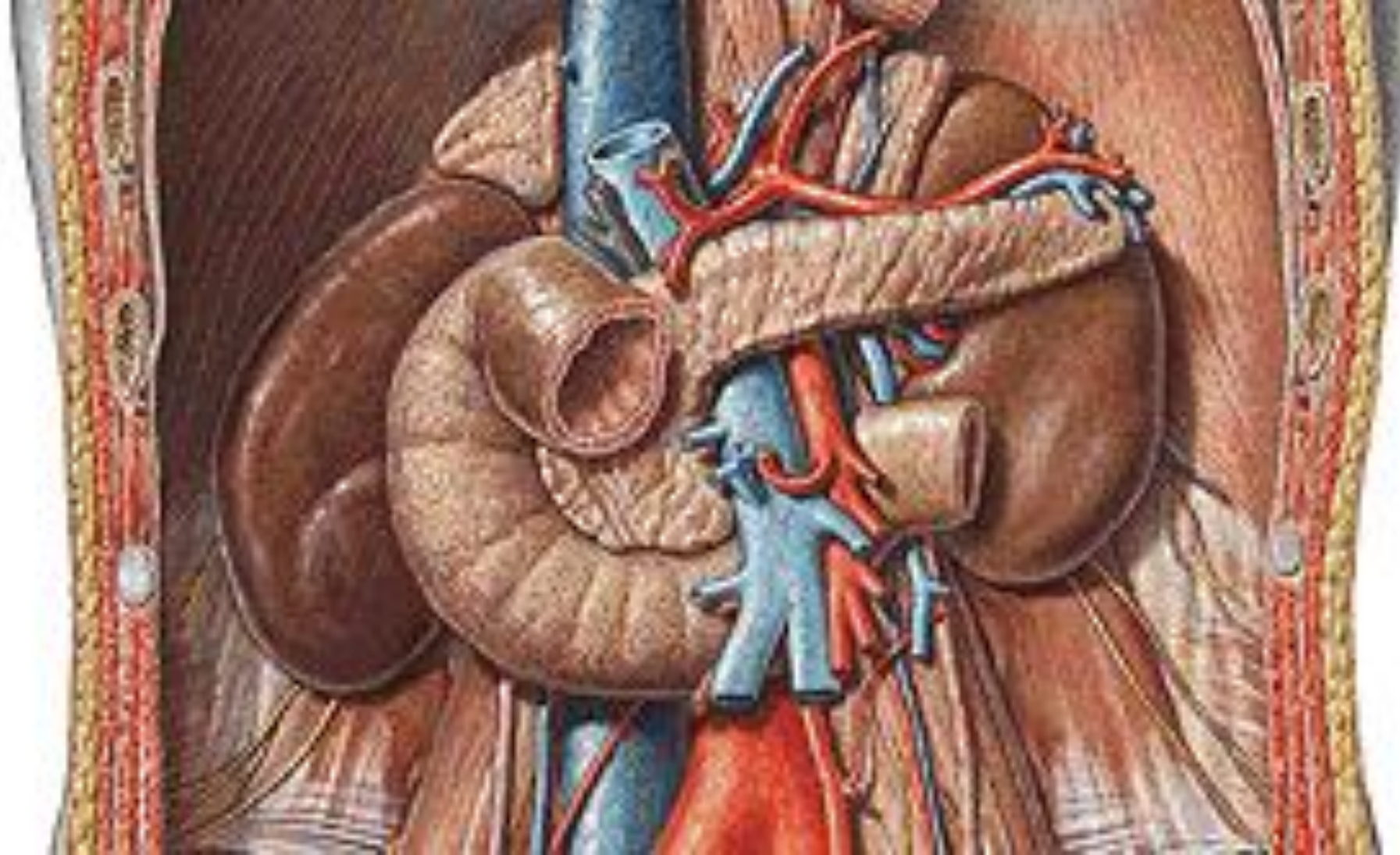


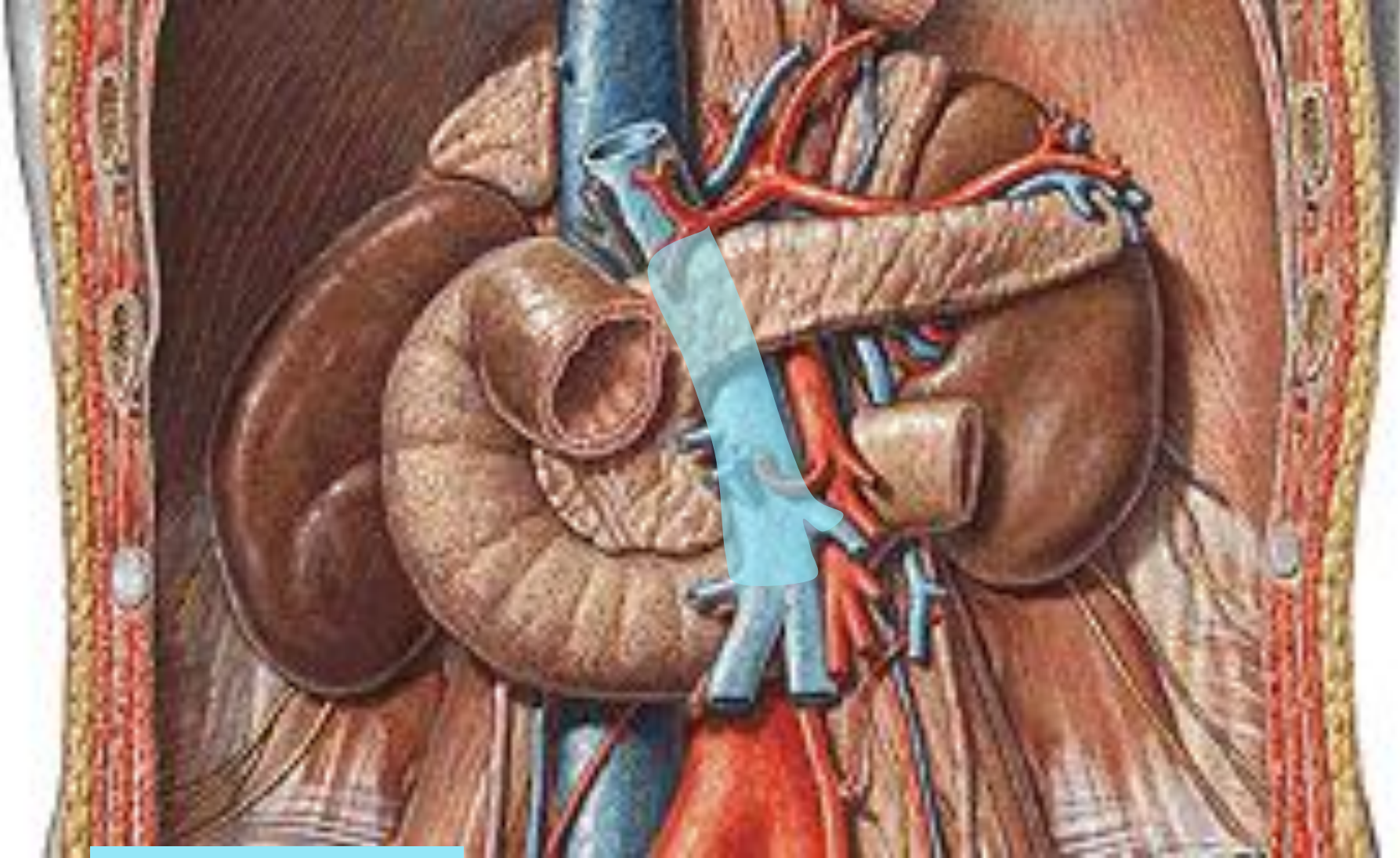


La vena cava inferior

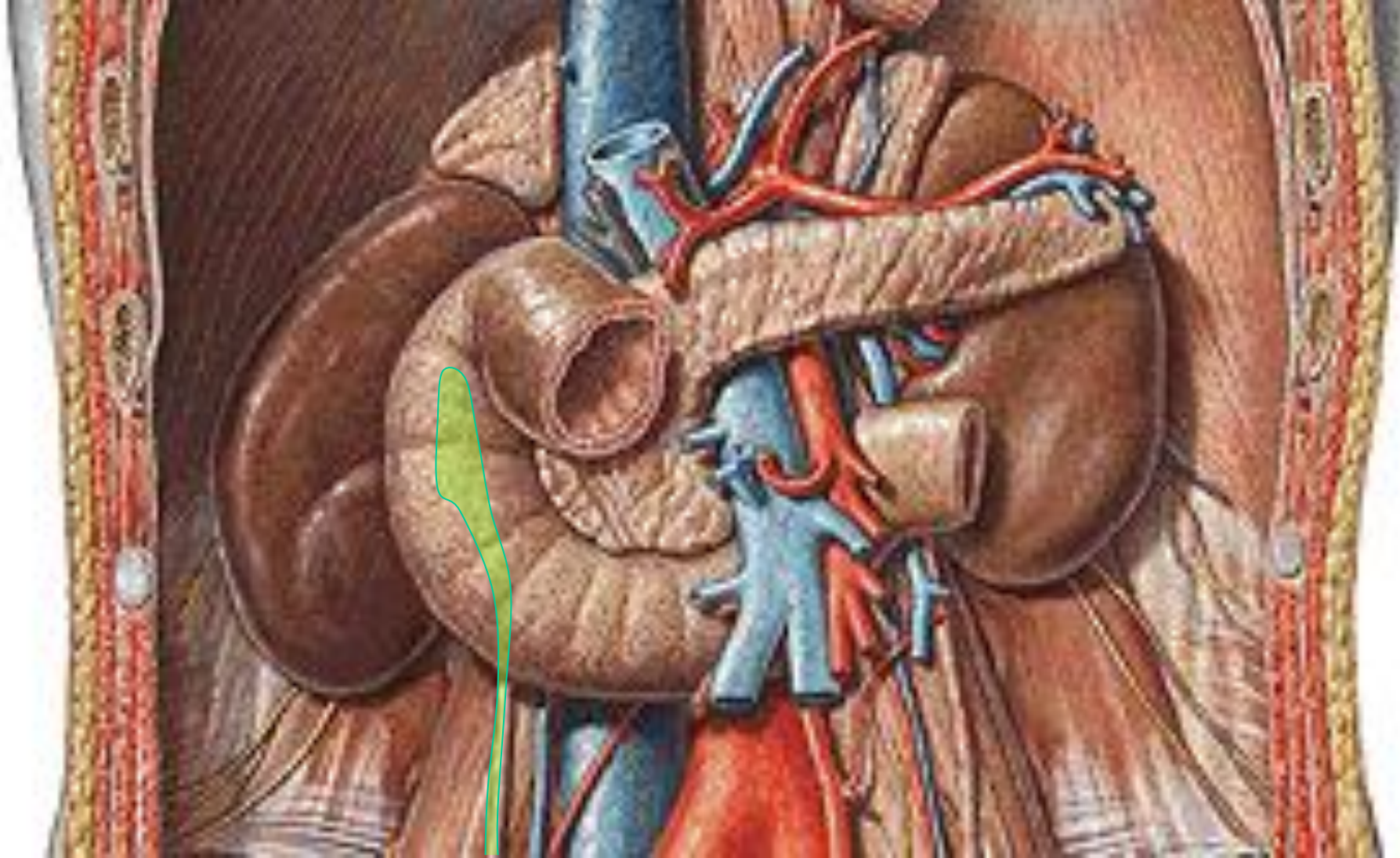


La aorta
abdominal

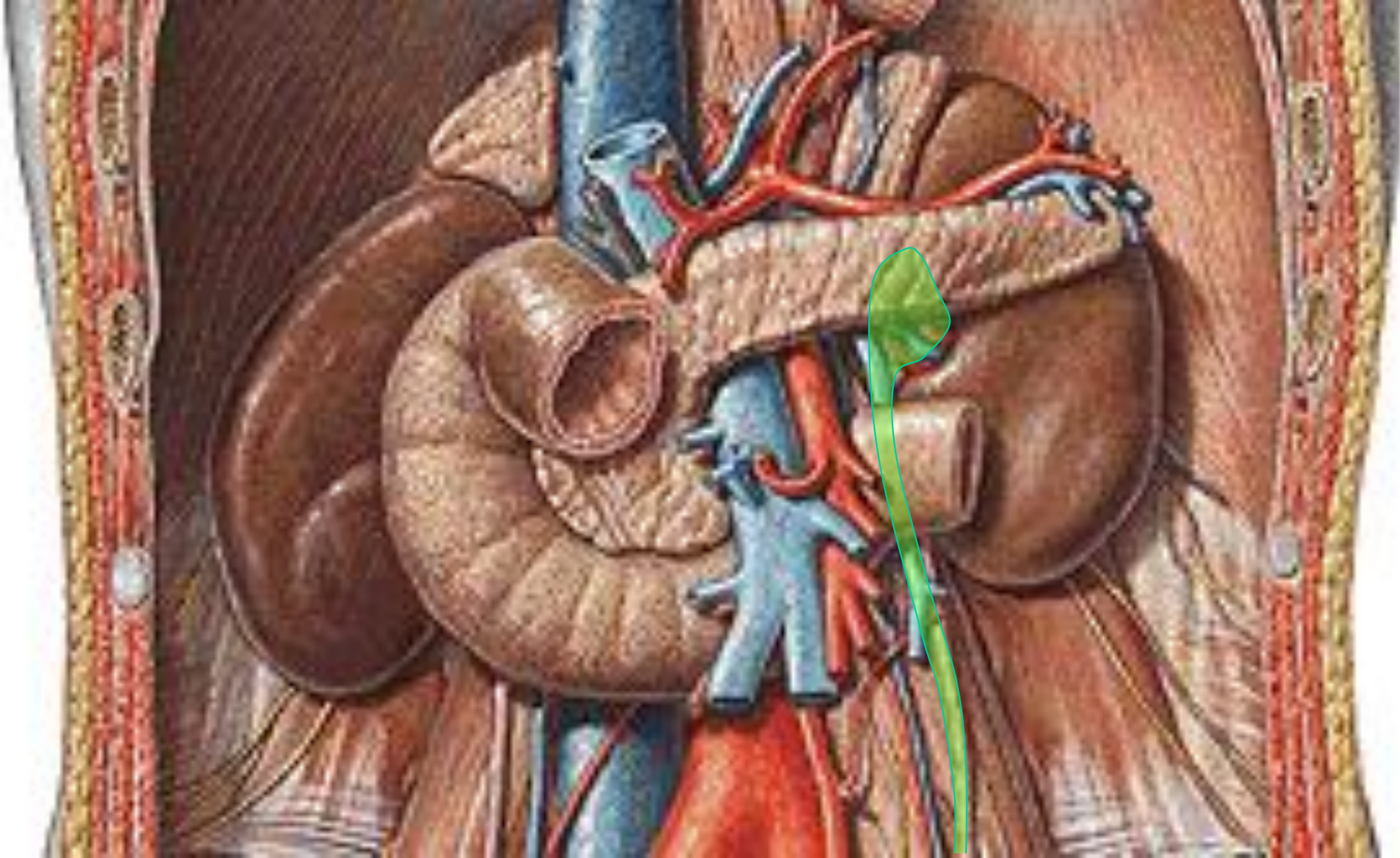




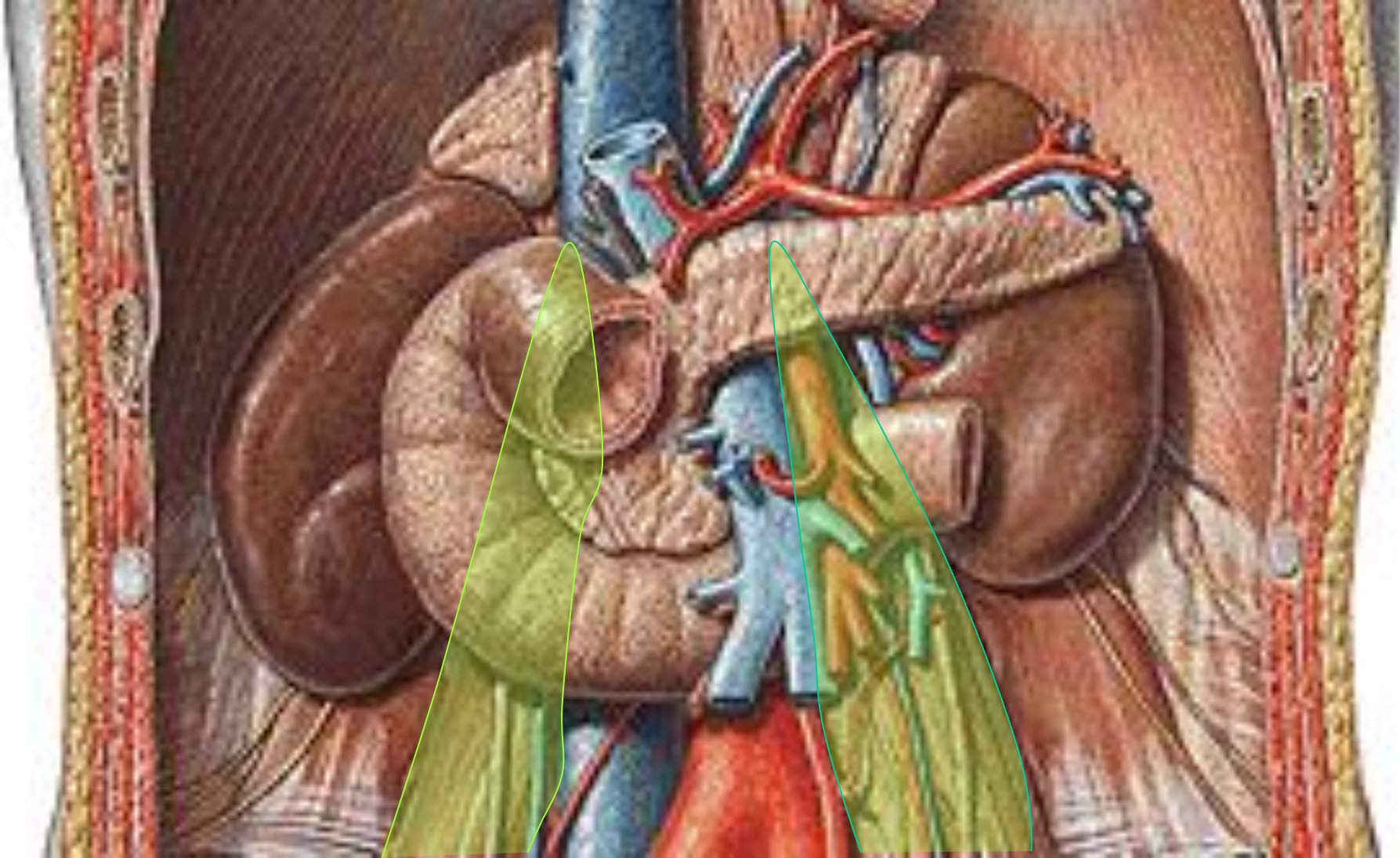Parte de la
vena porta



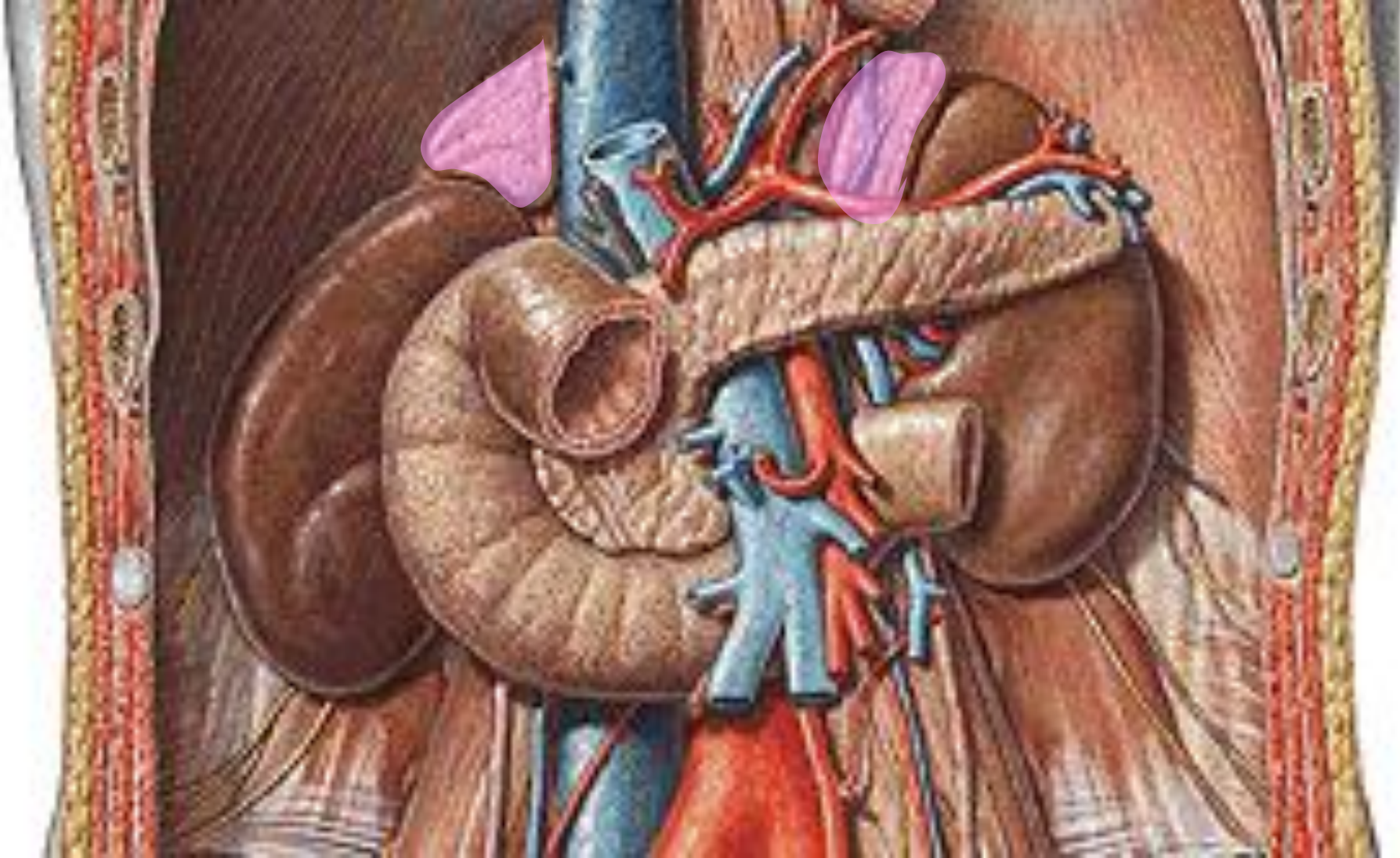
El uréter derecho



El uréter izquierdo

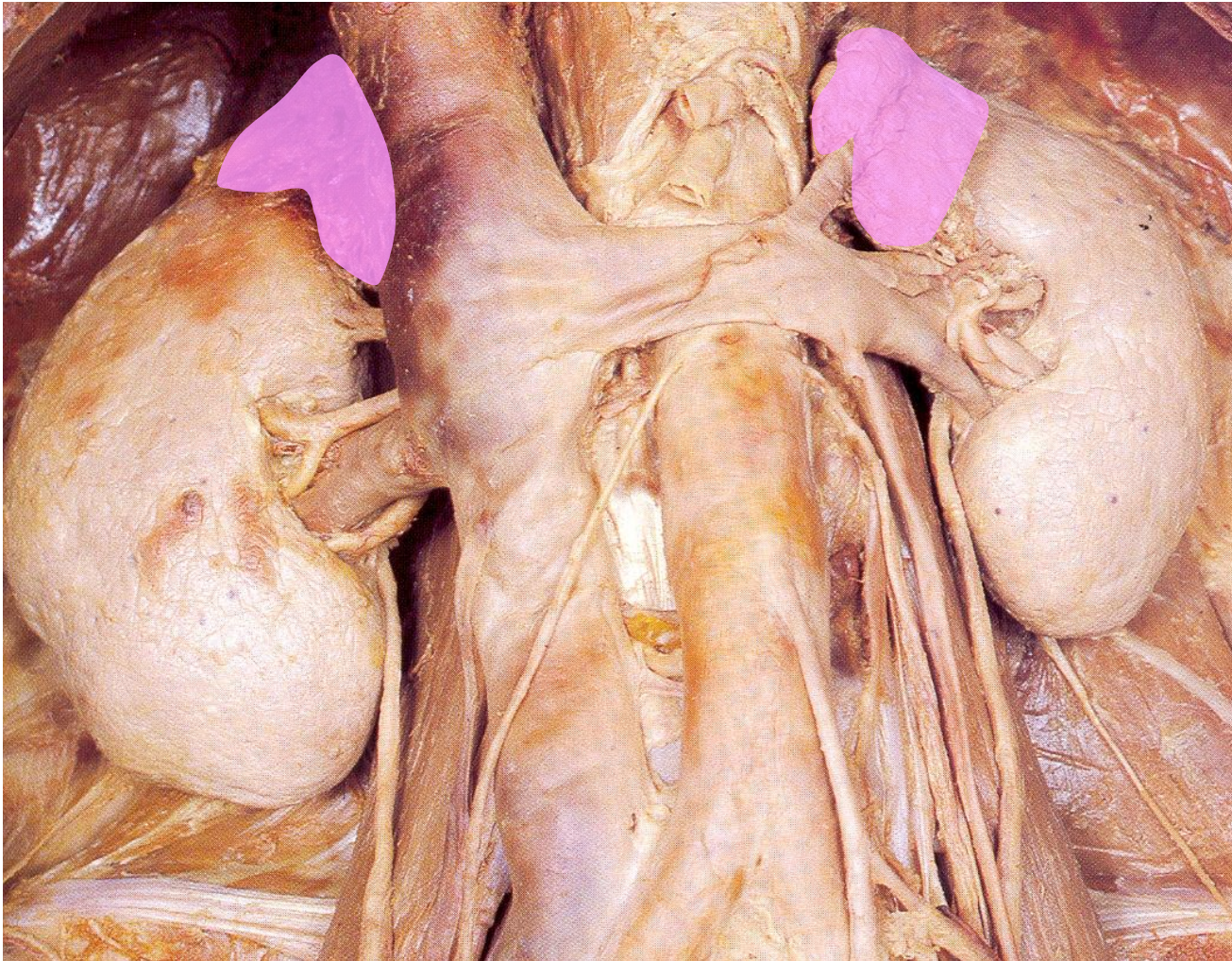


Músculos psoas
mayores

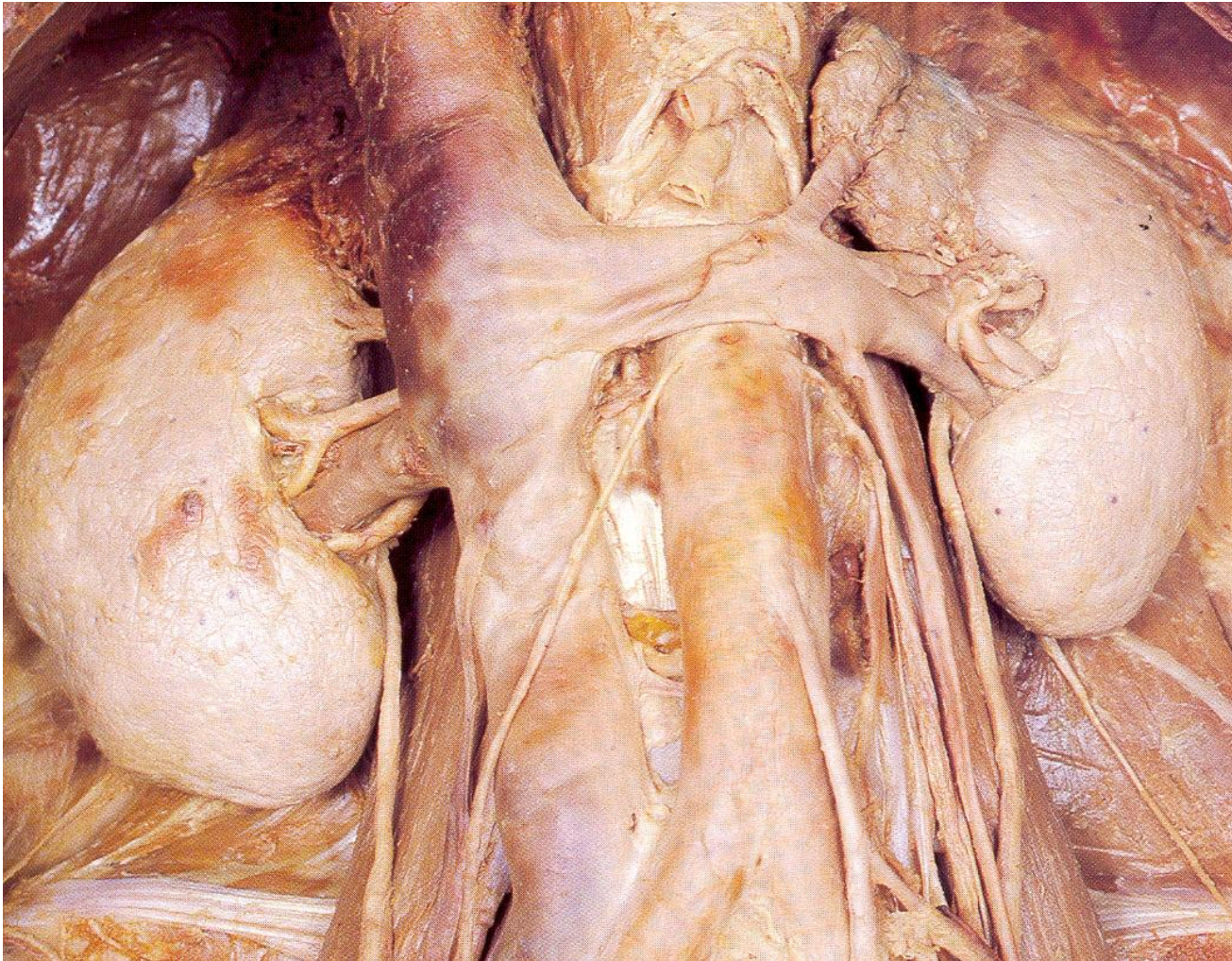


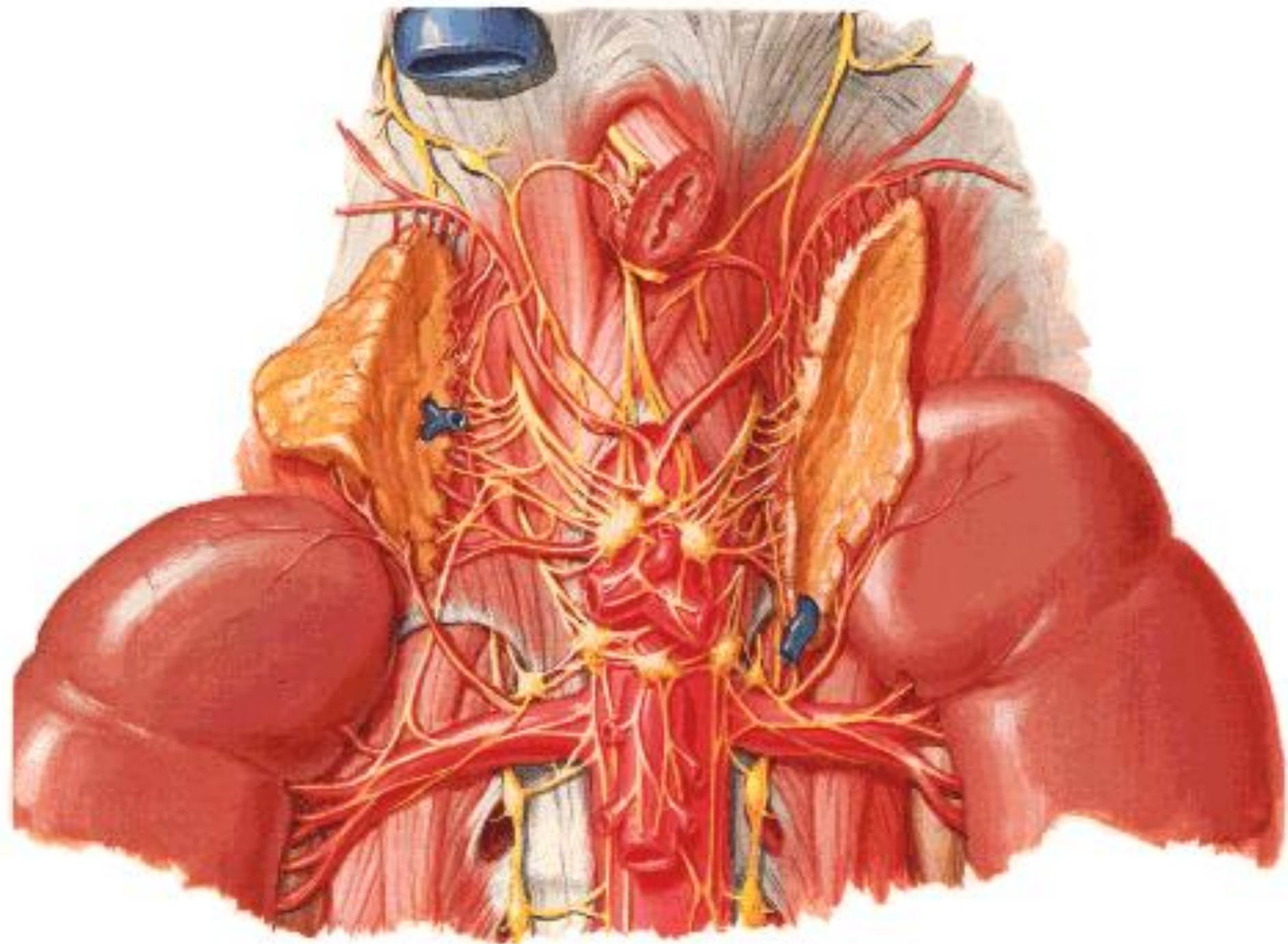
Glándulas
suprarrenales

Glándulas suprarrenales



Glándulas suprarrenales

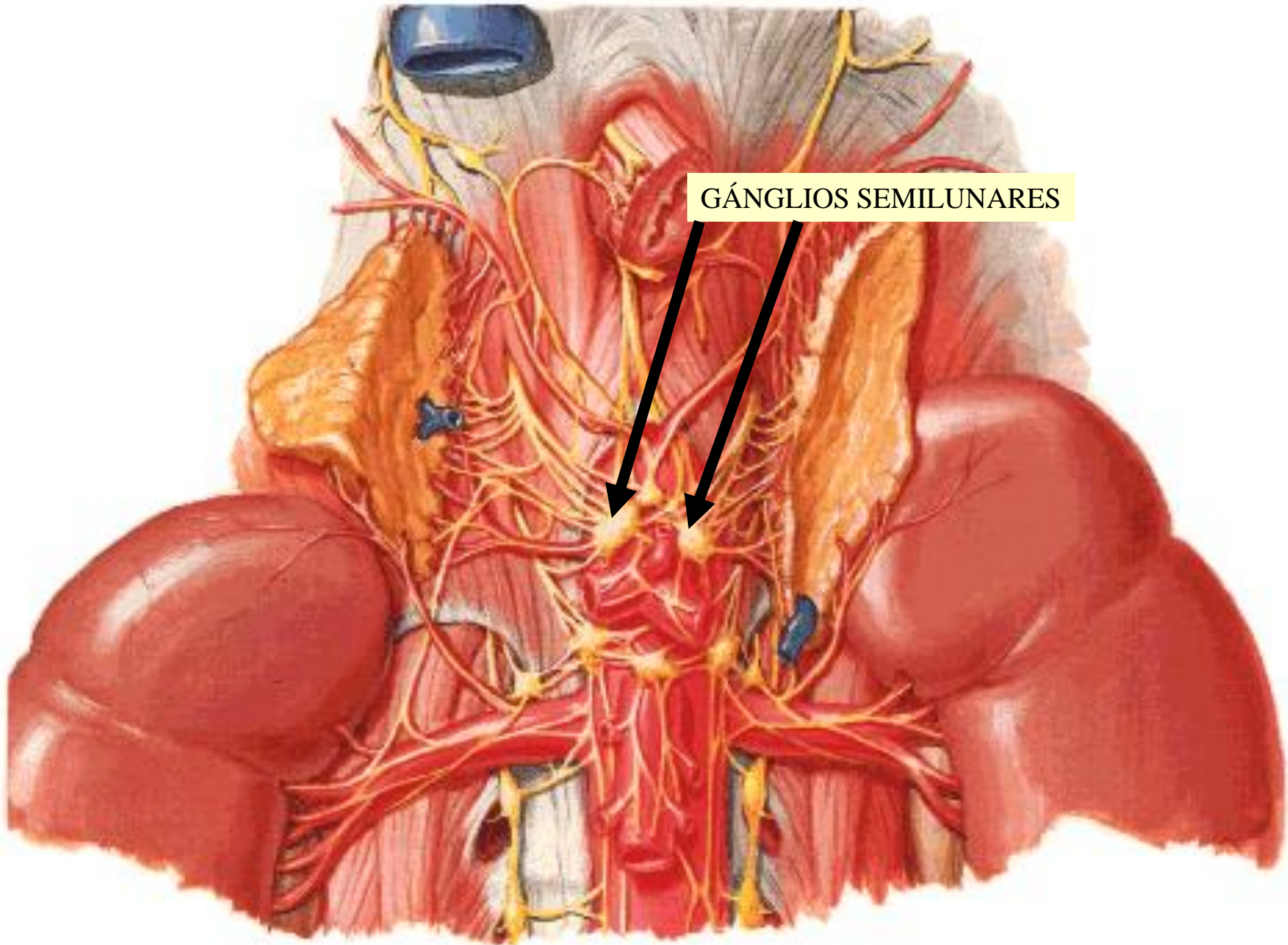


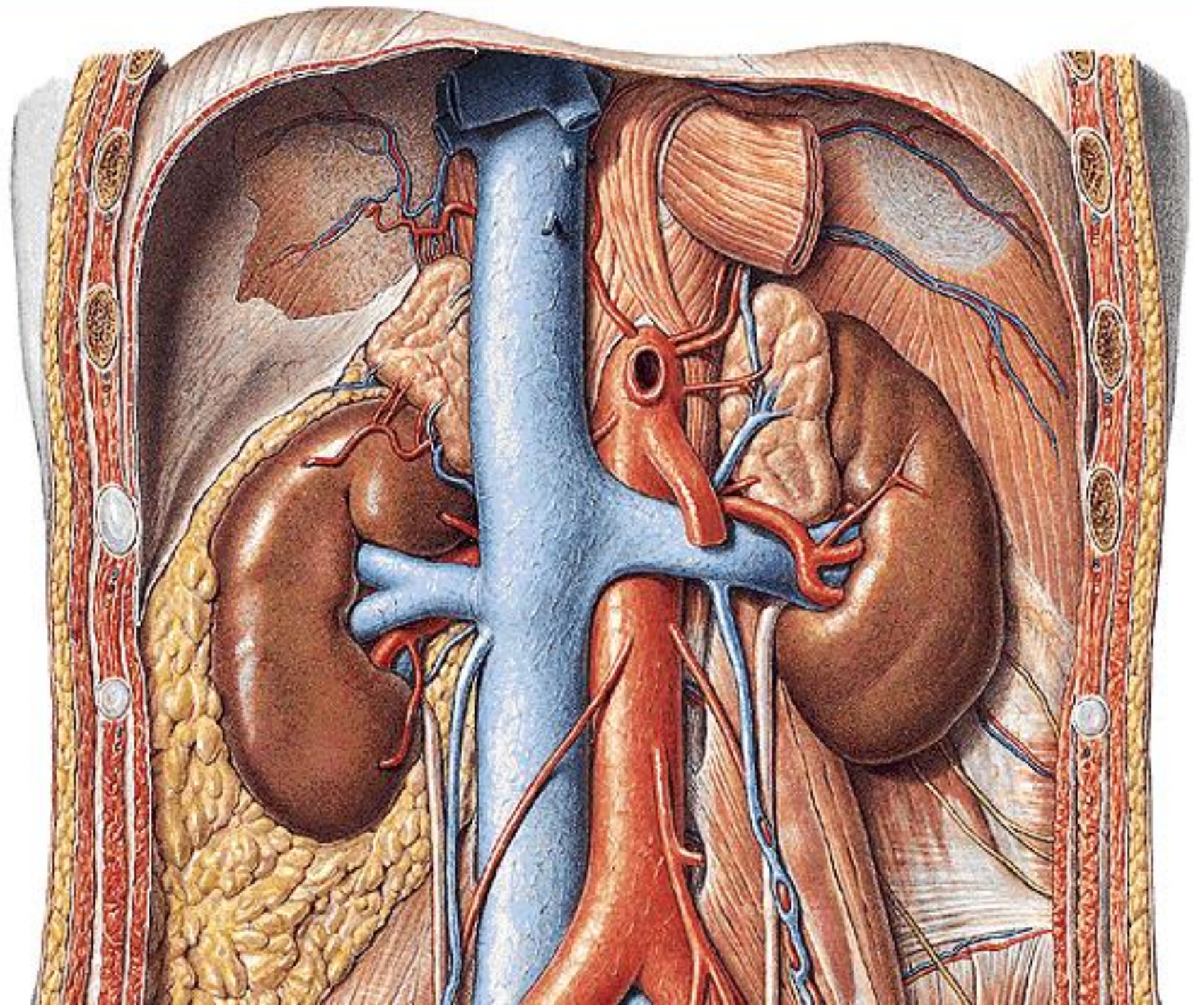


PLEXO SOLAR O CELIACO

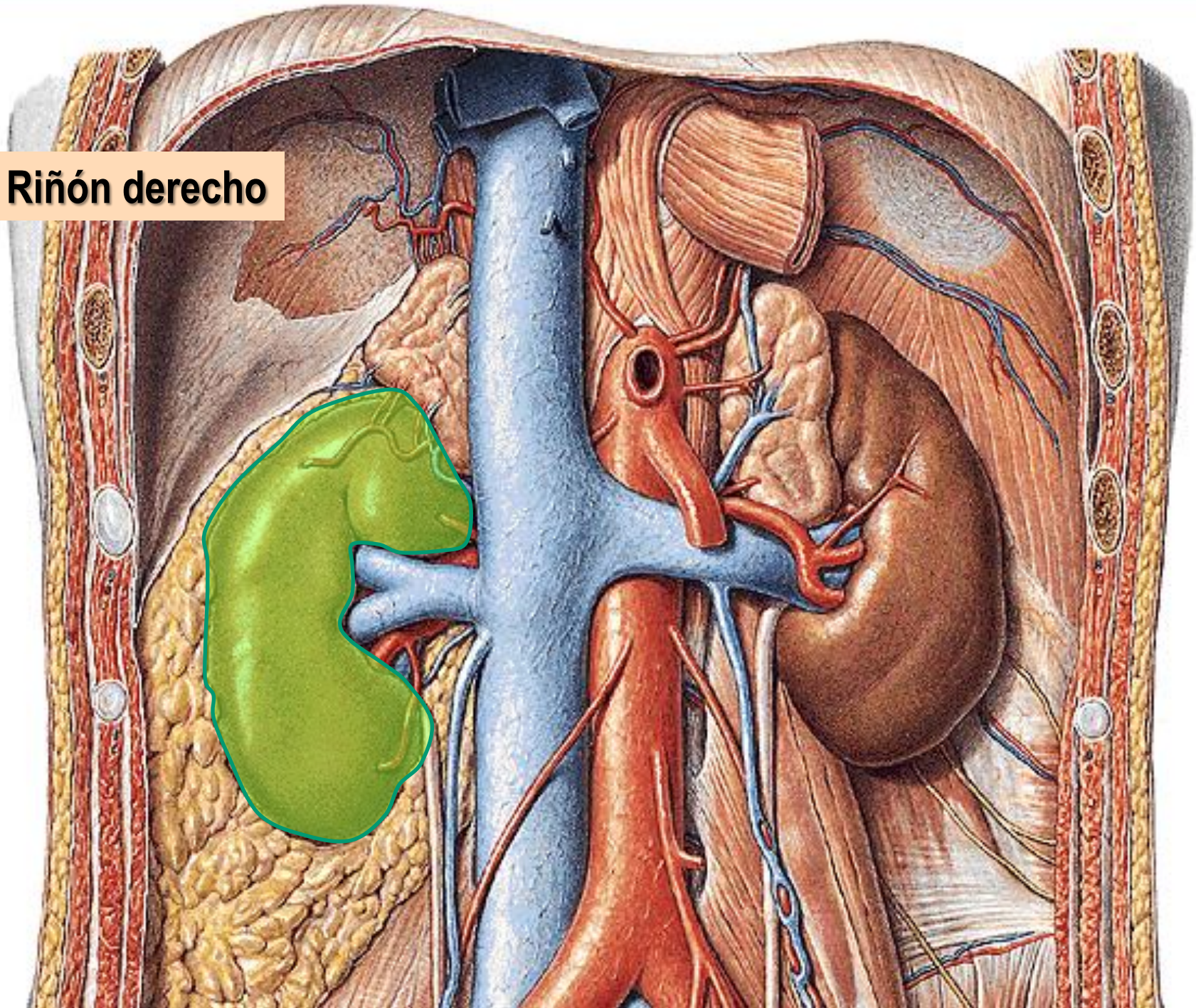


GÁNGLIOS SEMILUNARES

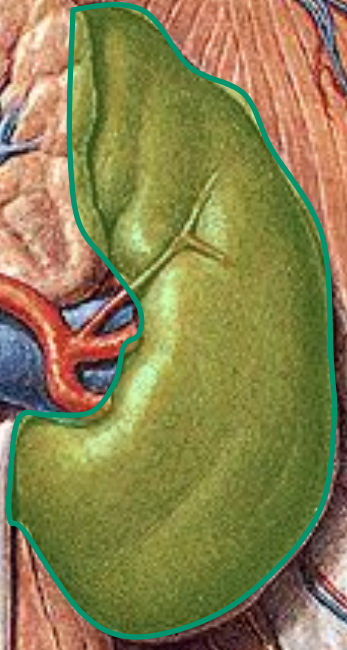



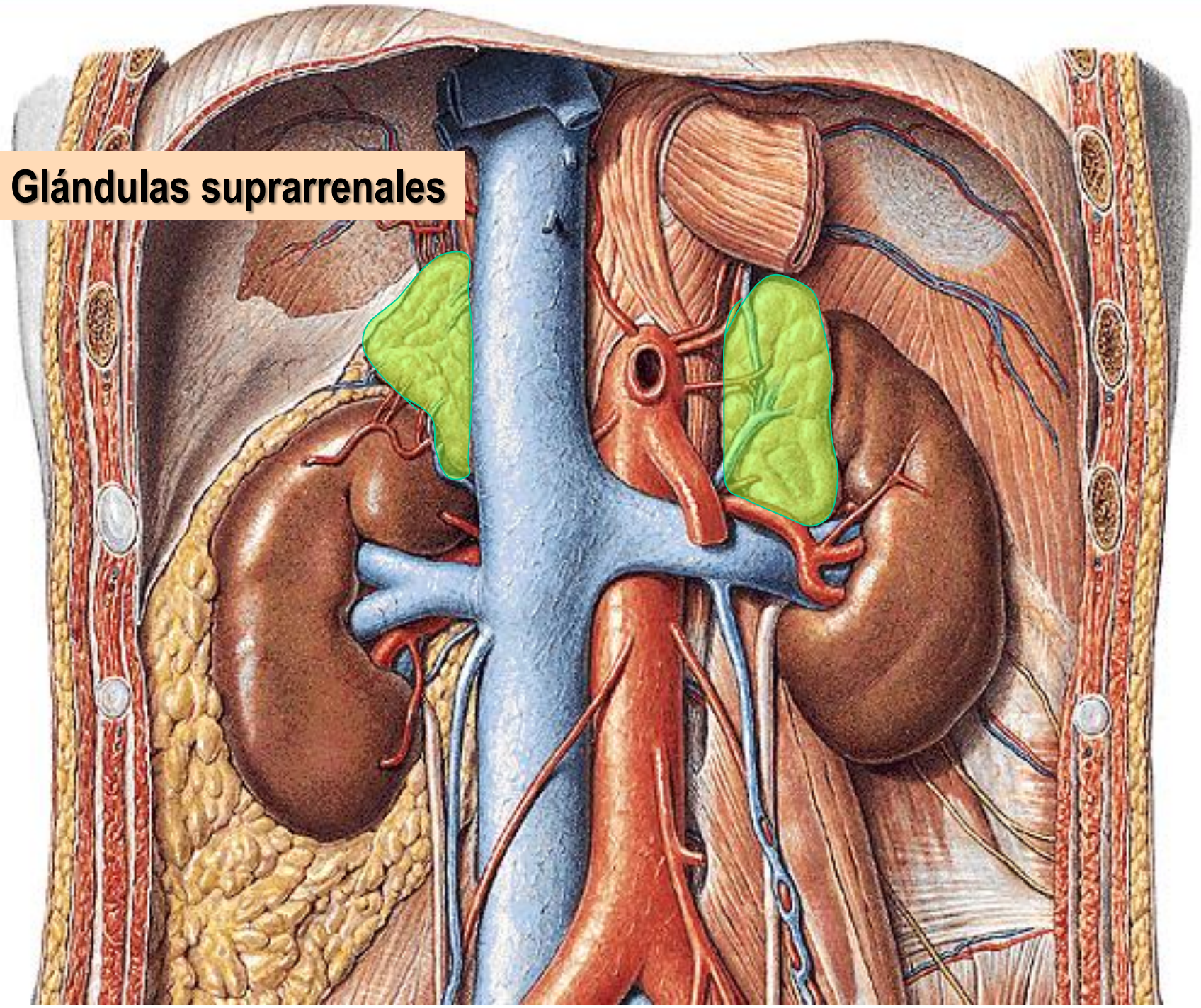
Riñón derecho



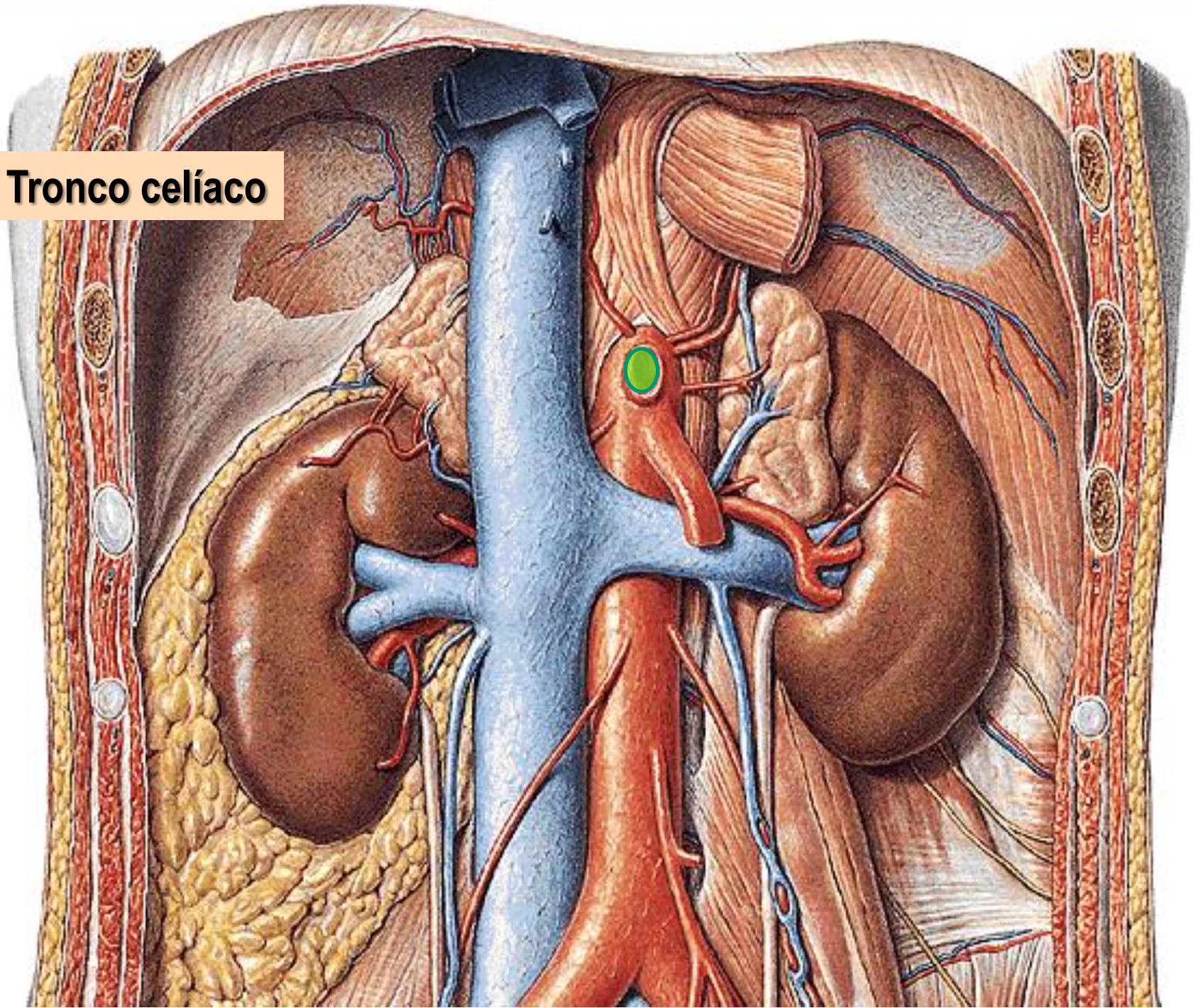
Riñón izquierdo



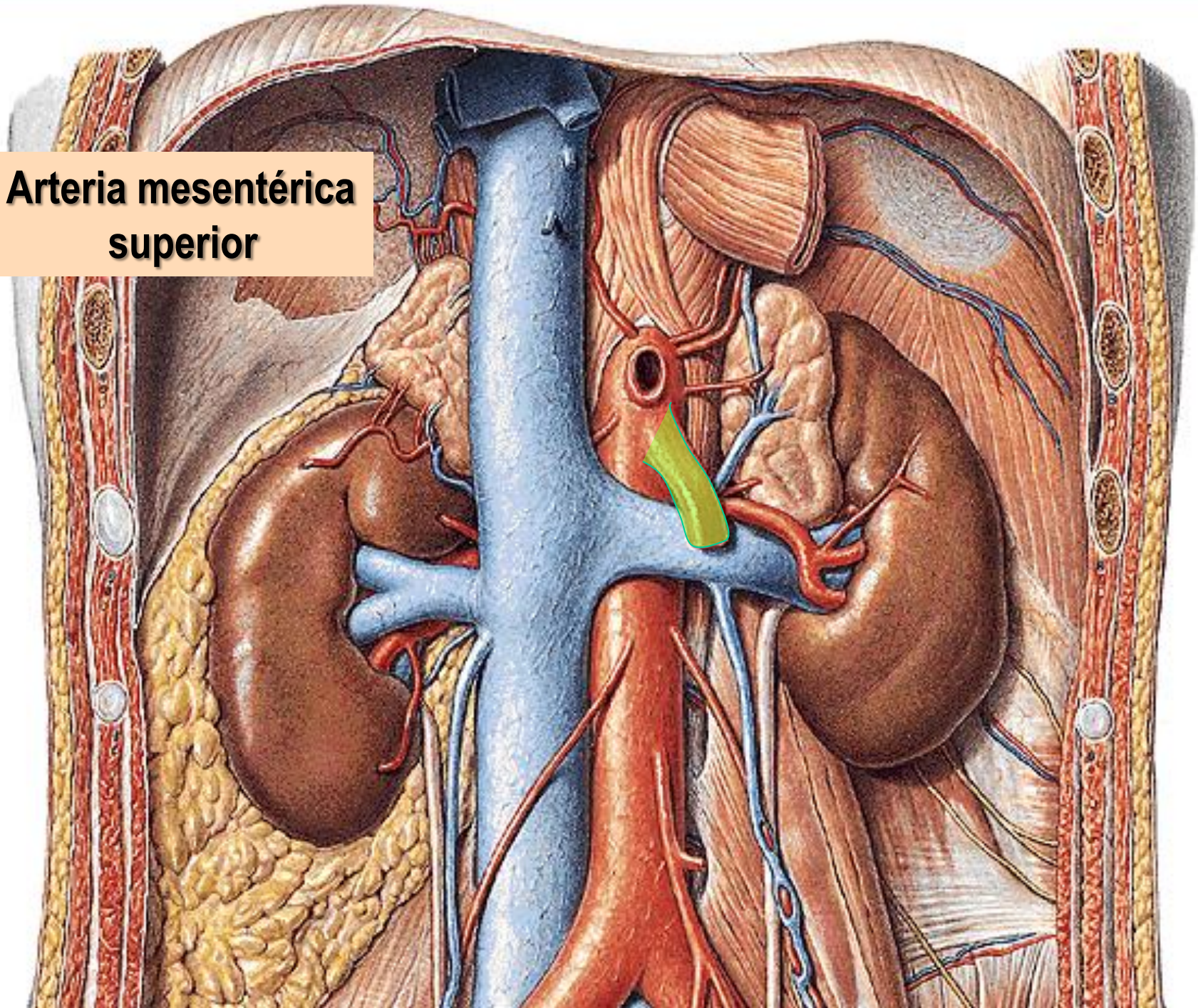
Glándulas suprarrenales



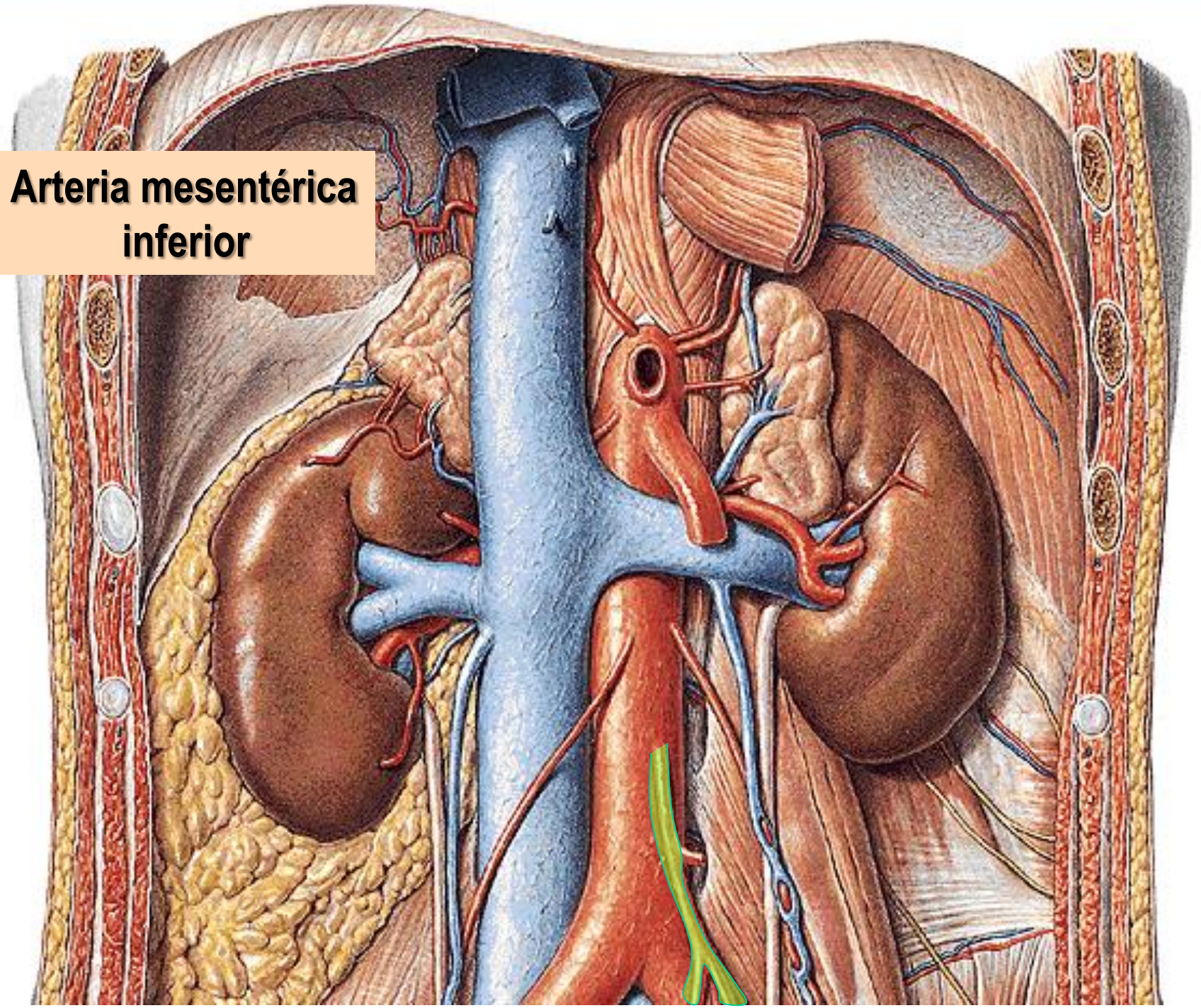
Tronco celíaco



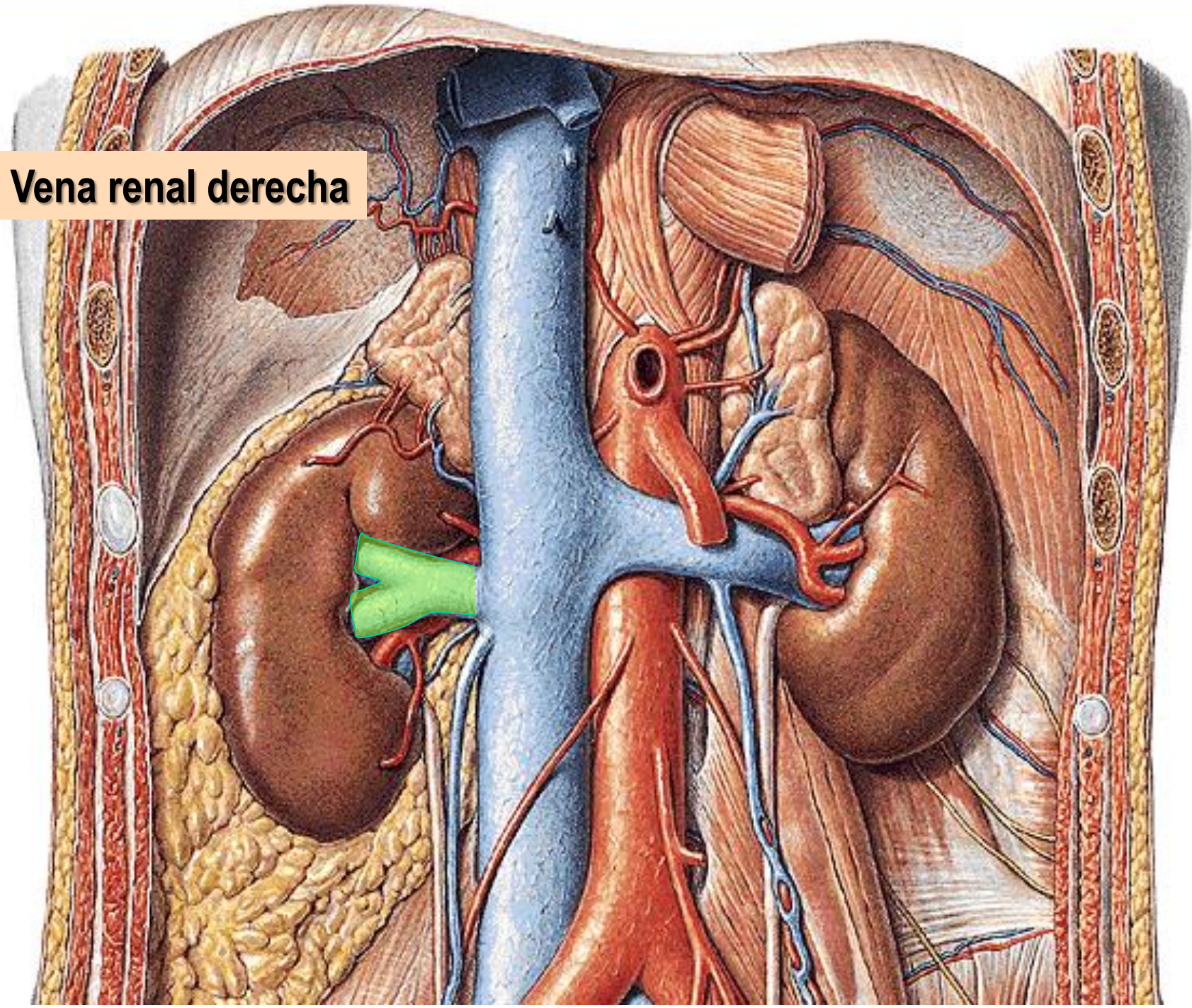
Arteria mesentérica superior



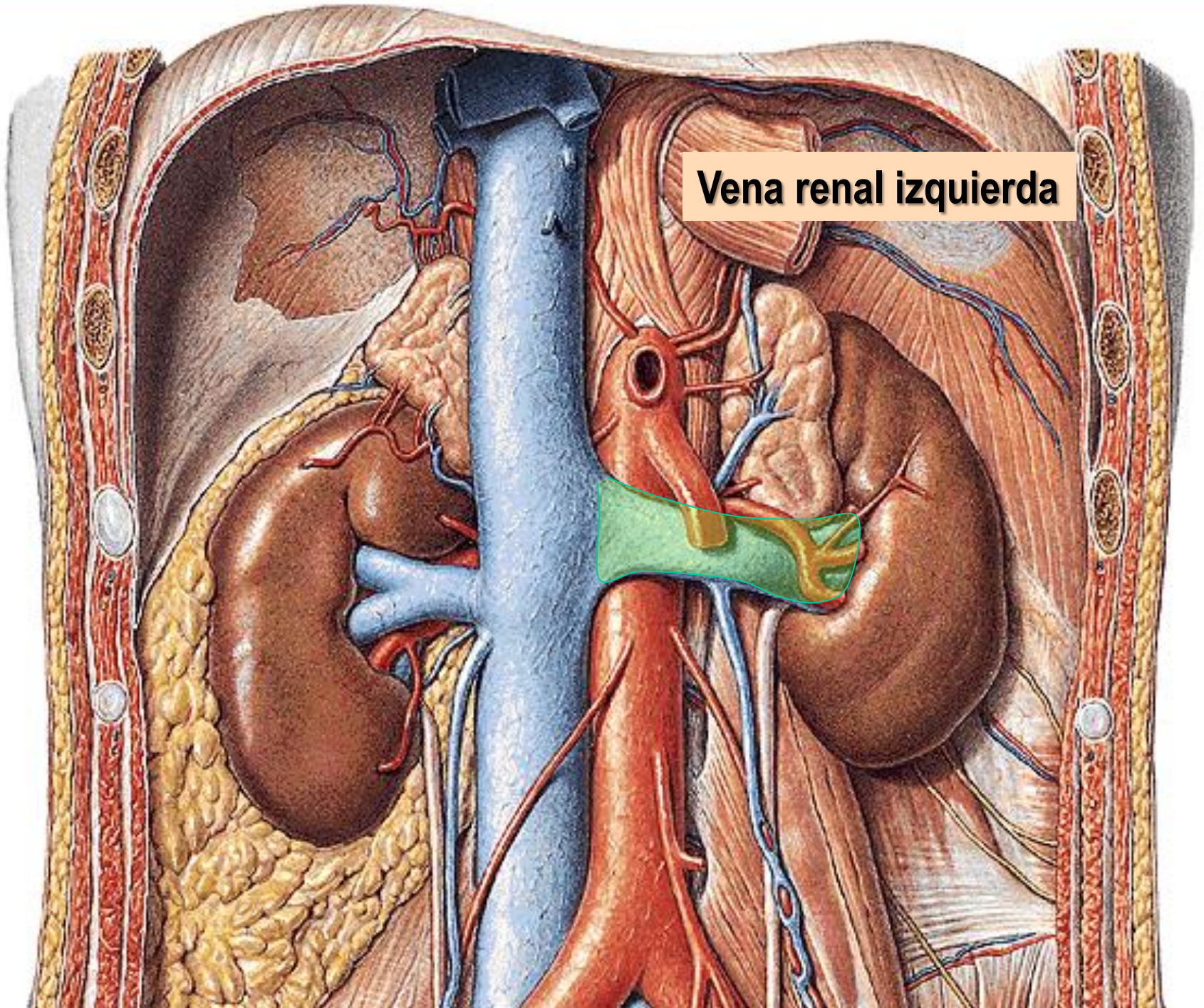
Arteria mesentérica inferior



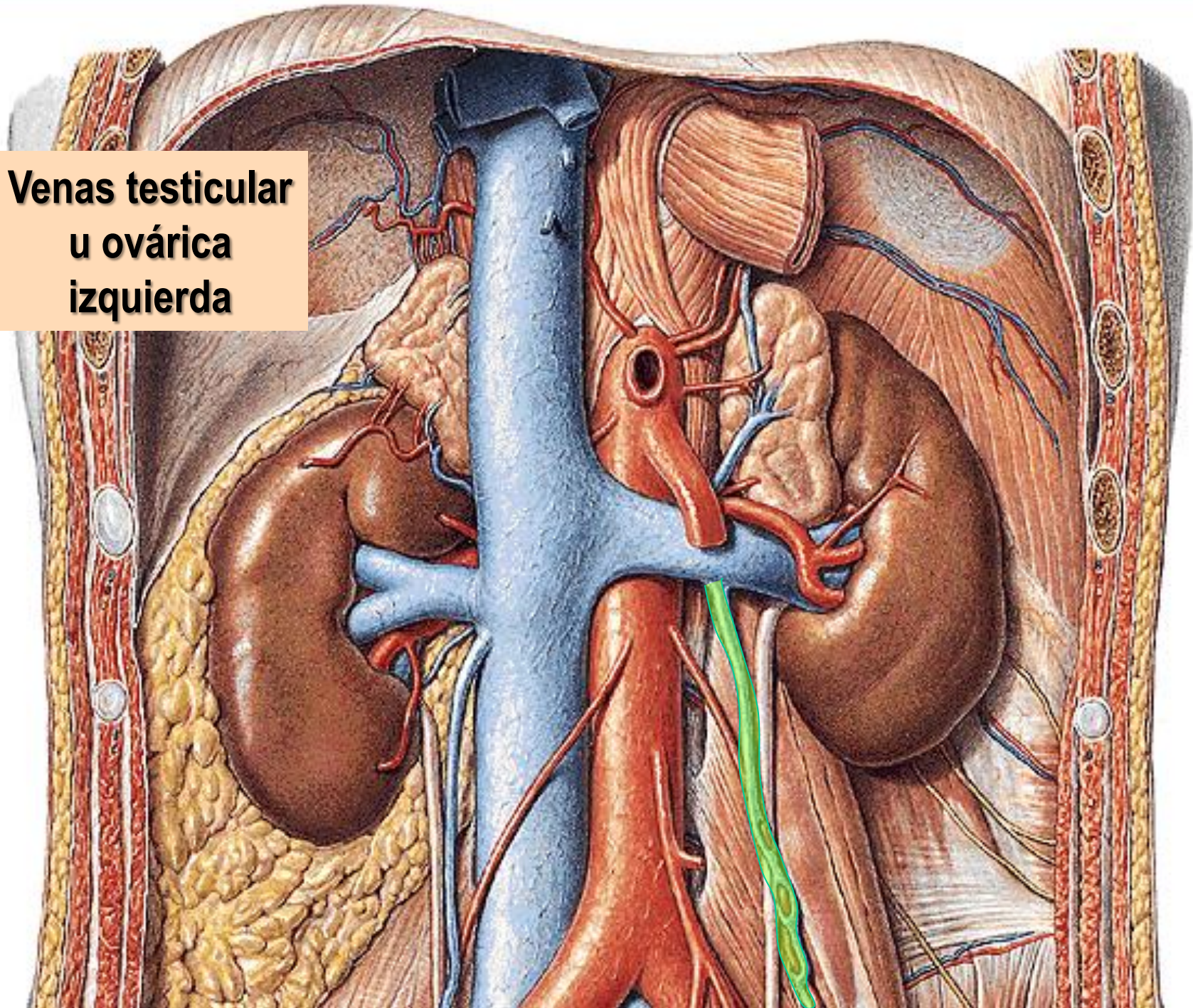
Vena renal derecha



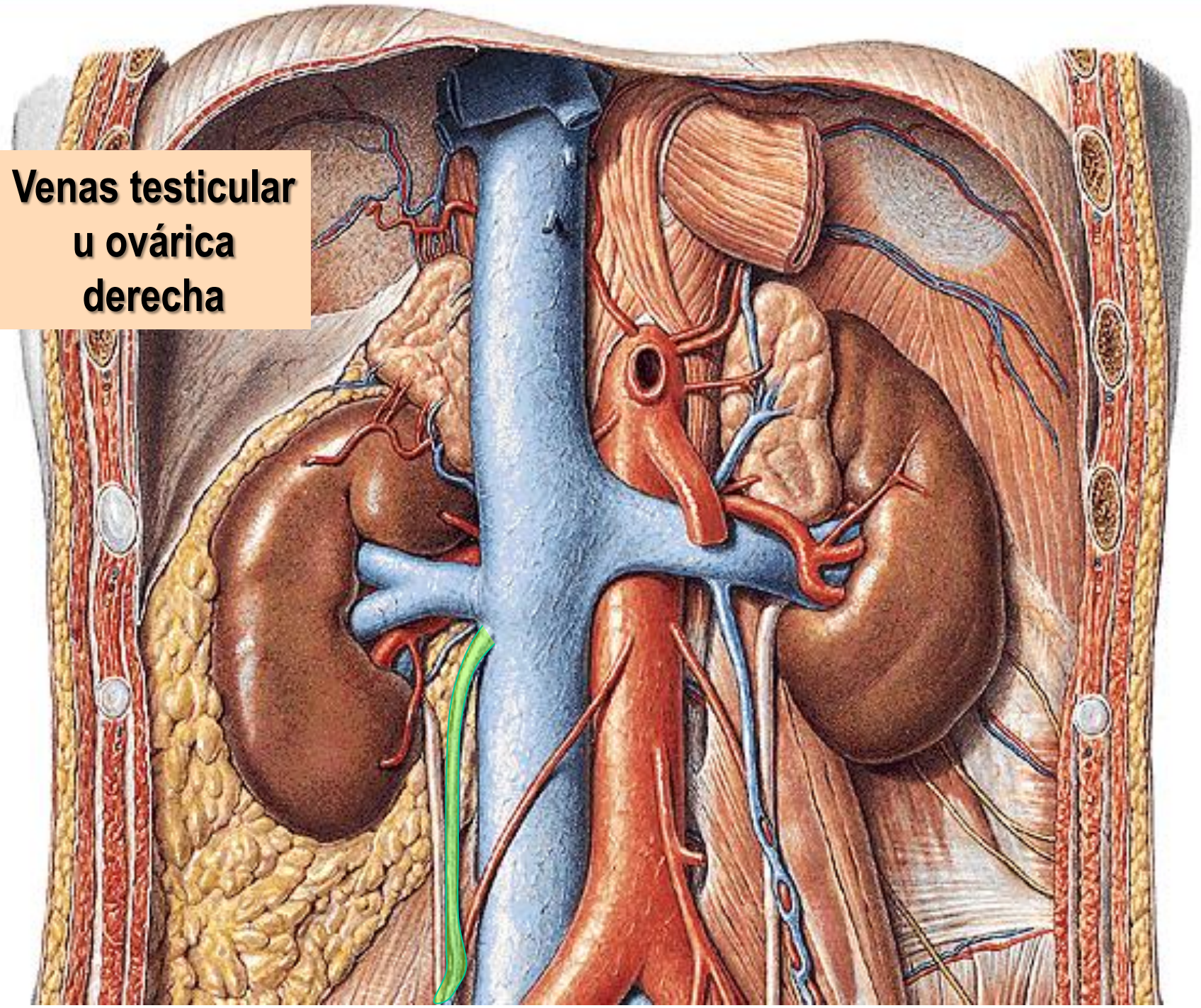
Vena renal izquierda



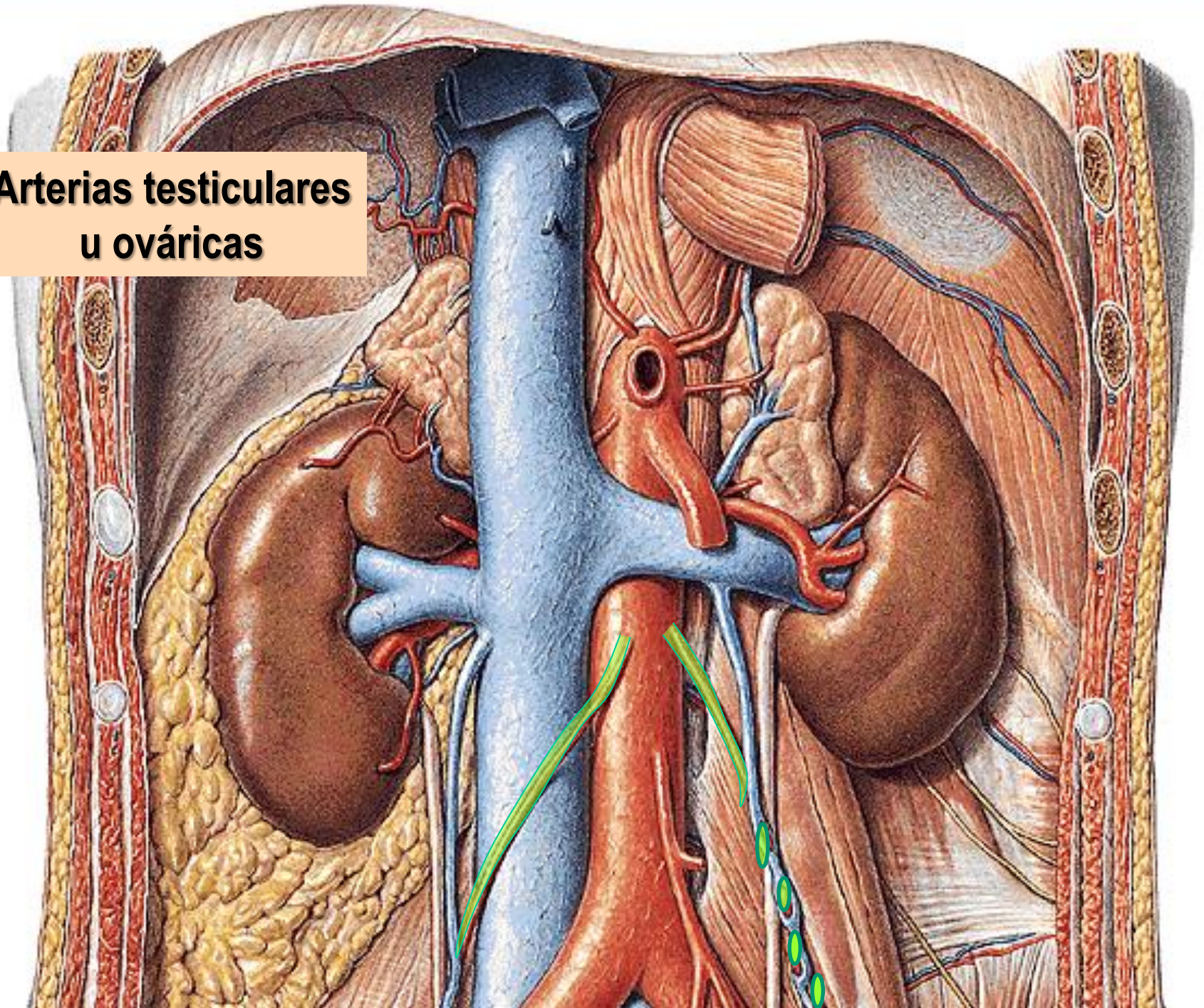
**Venas testicular
u ovárica
izquierda**



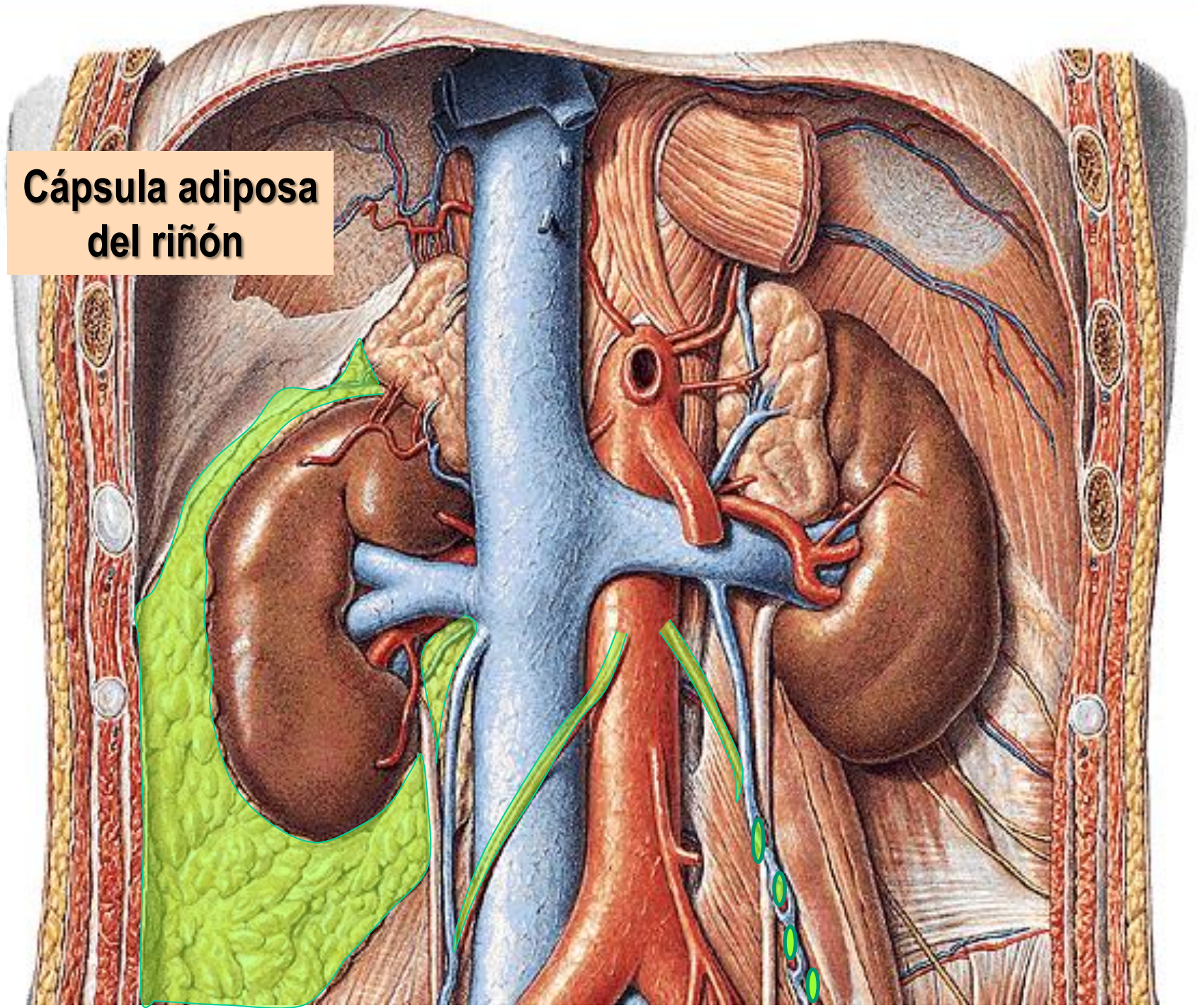
**Venas testicular
u ovárica
derecha**



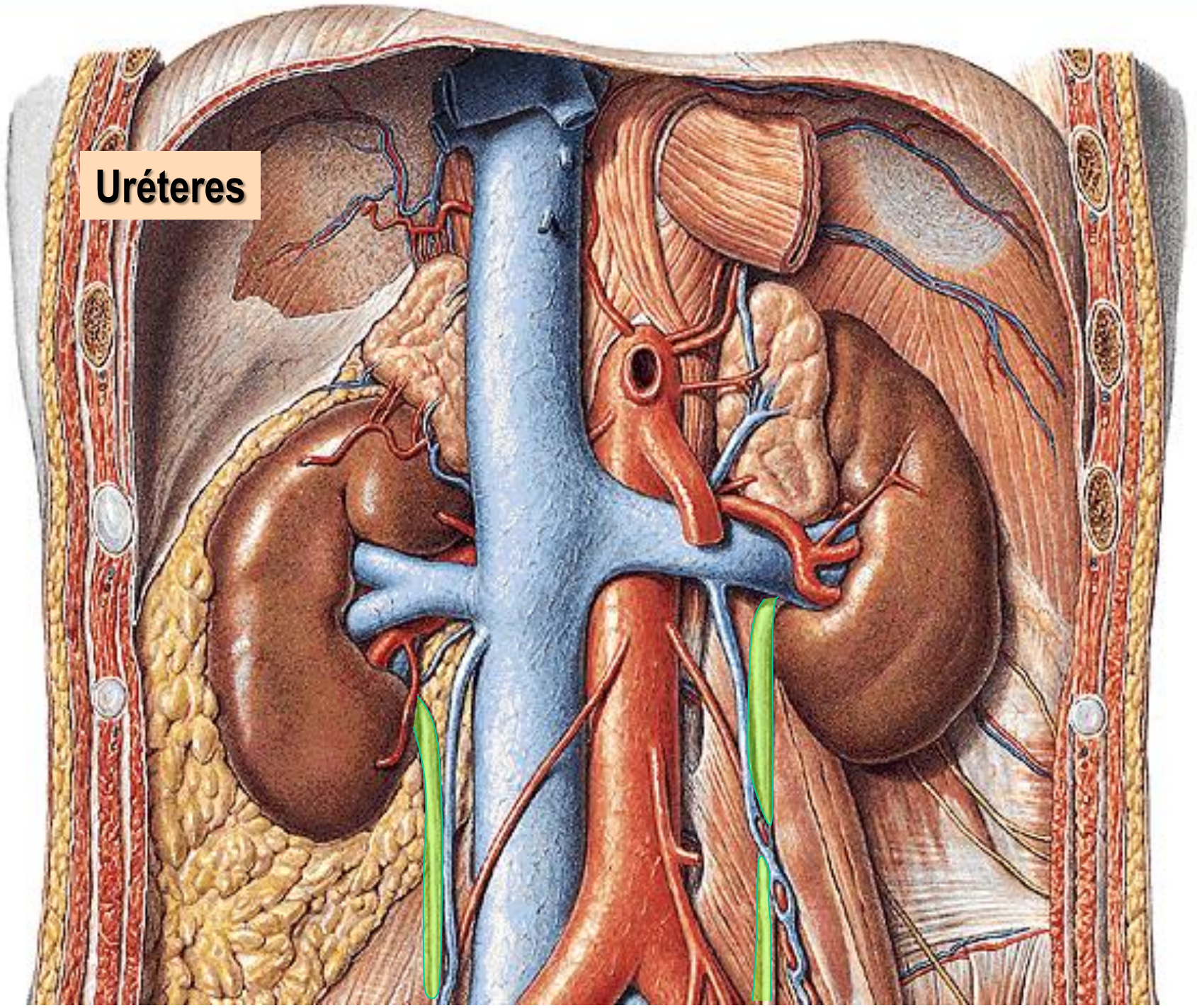
**Arterias testiculares
u ováricas**

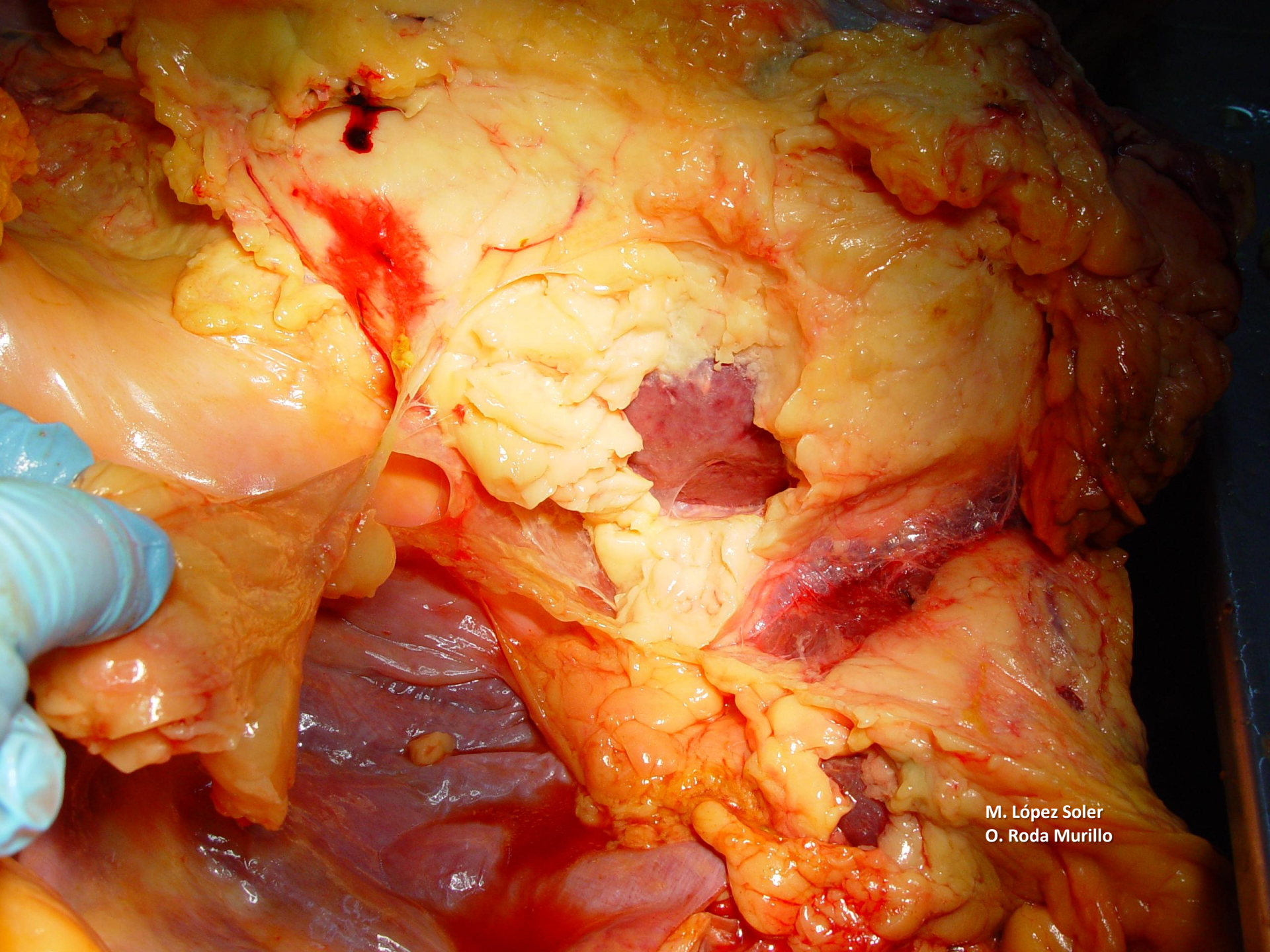


**Cápsula adiposa
del riñón**

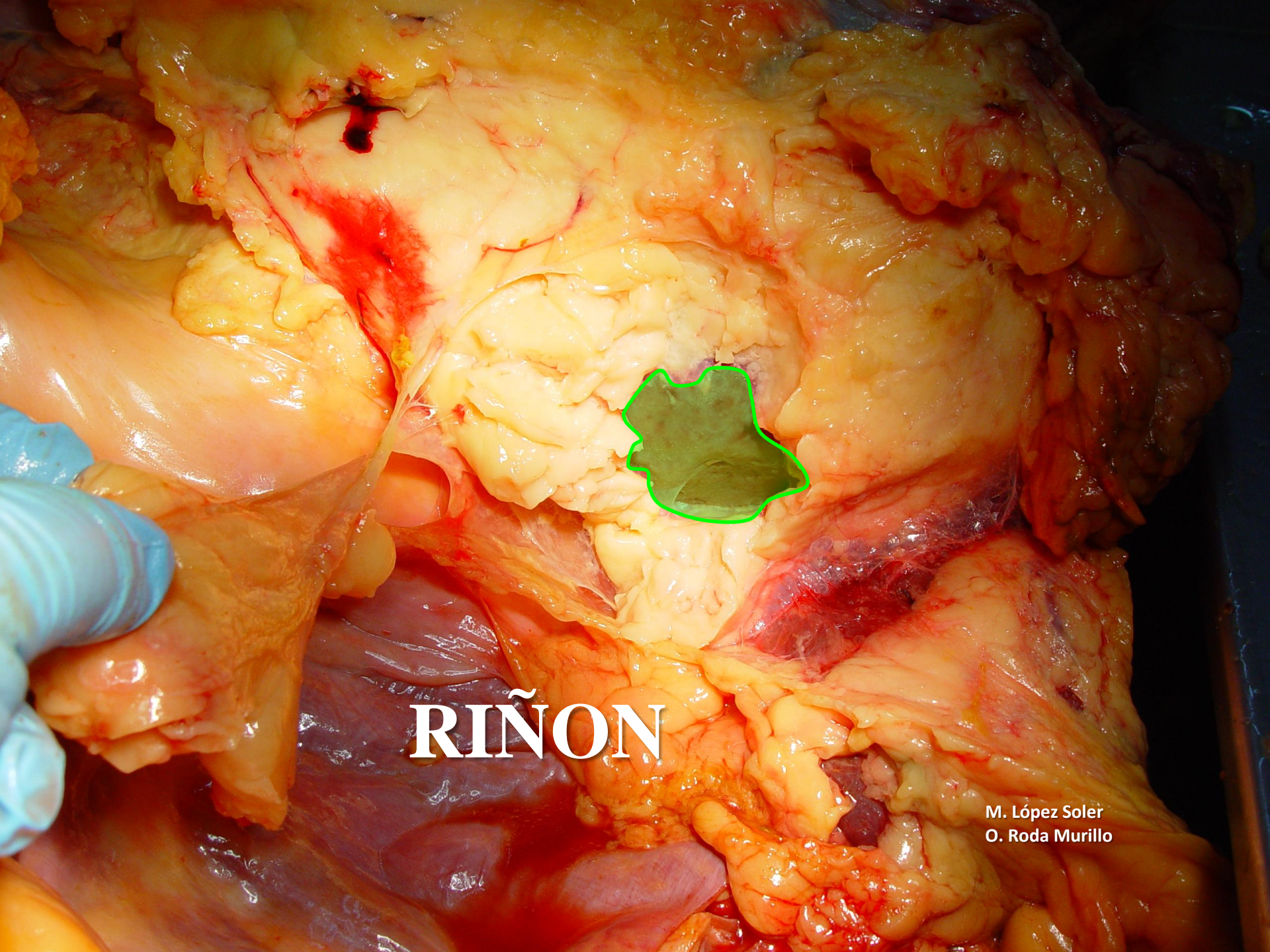

Uréteres



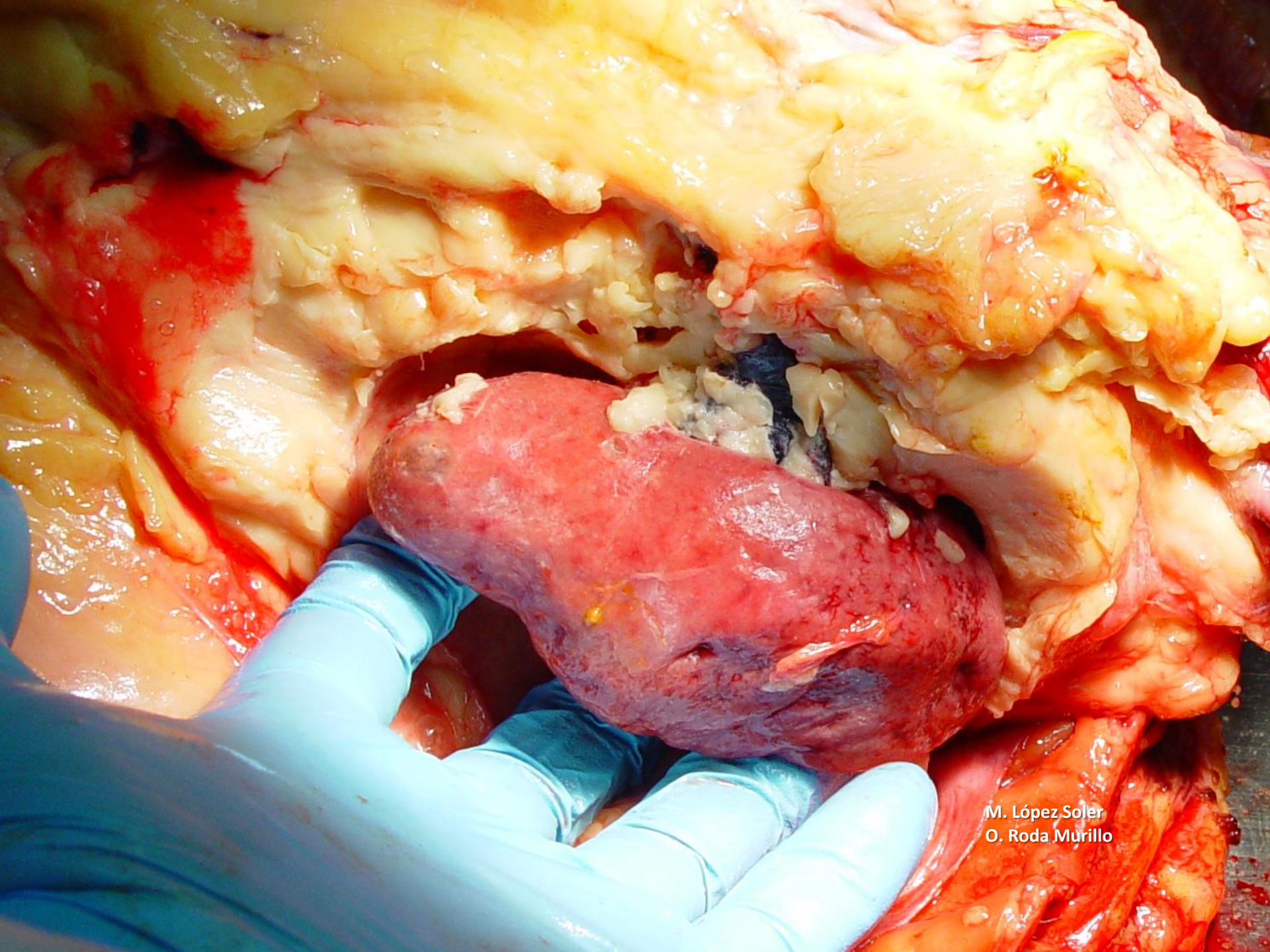


M. López Soler
O. Roda Murillo

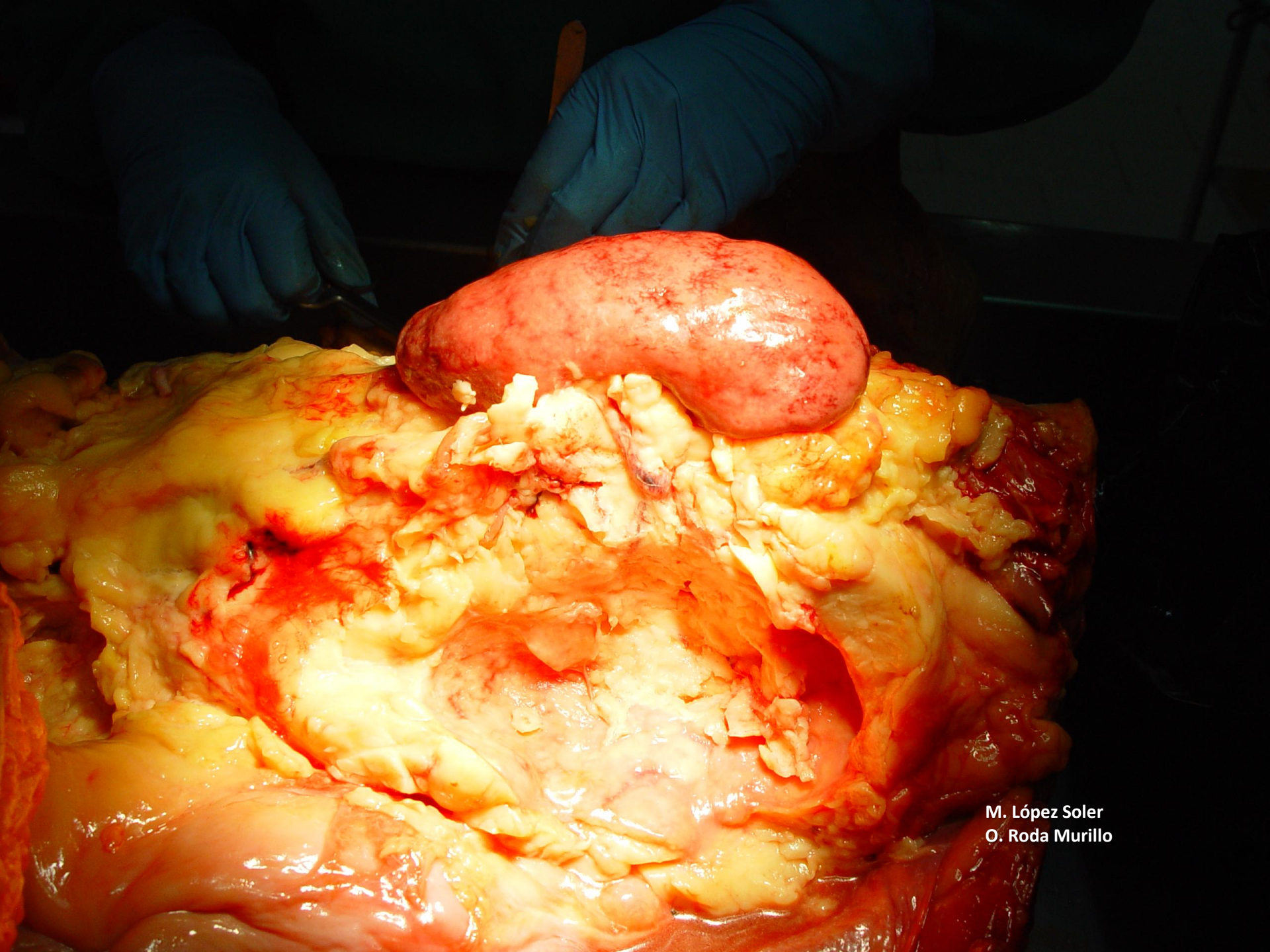


RIÑÓN

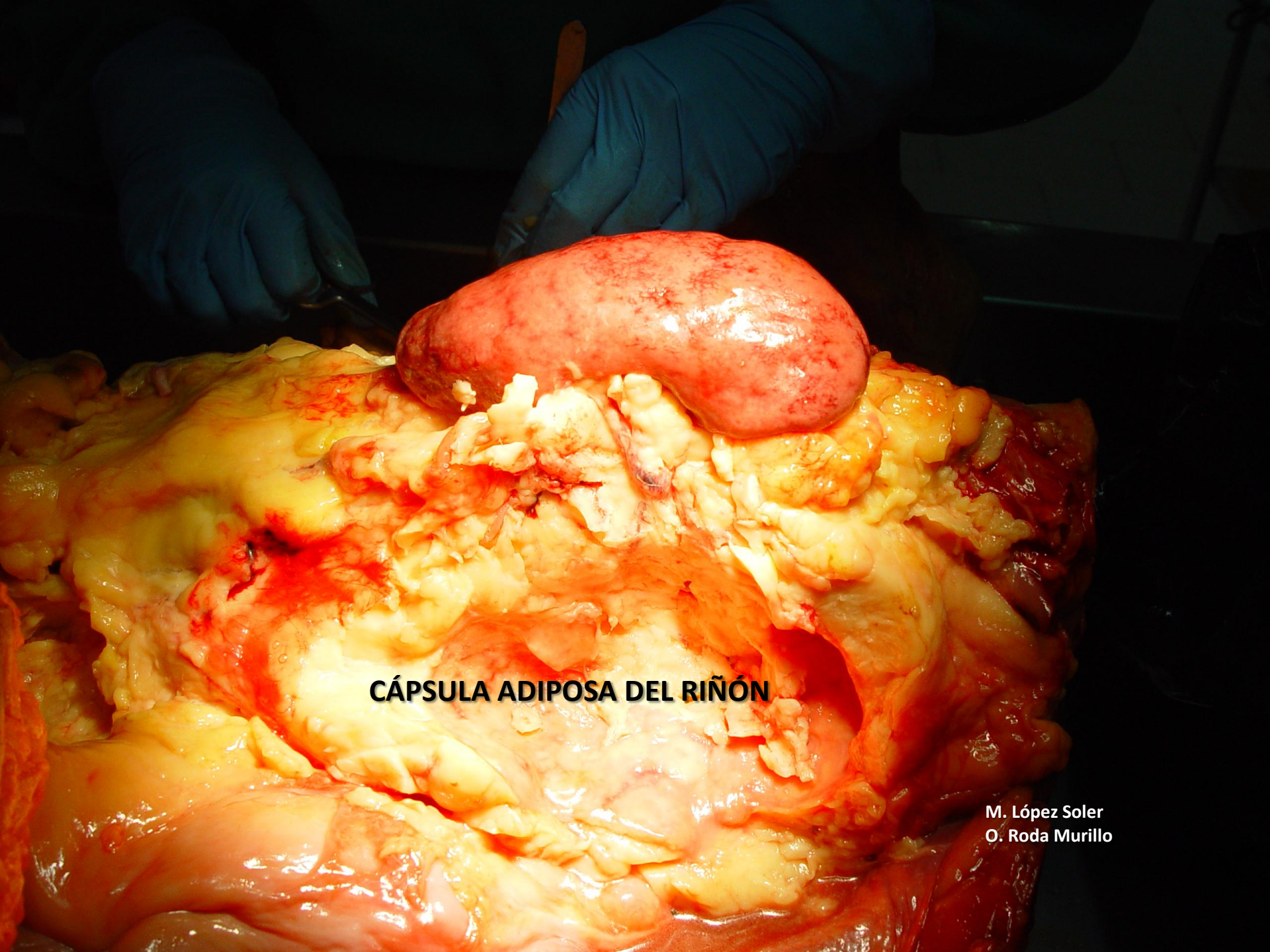
M. López Soler
O. Roda Murillo



M. López Soler
O. Roda Murillo

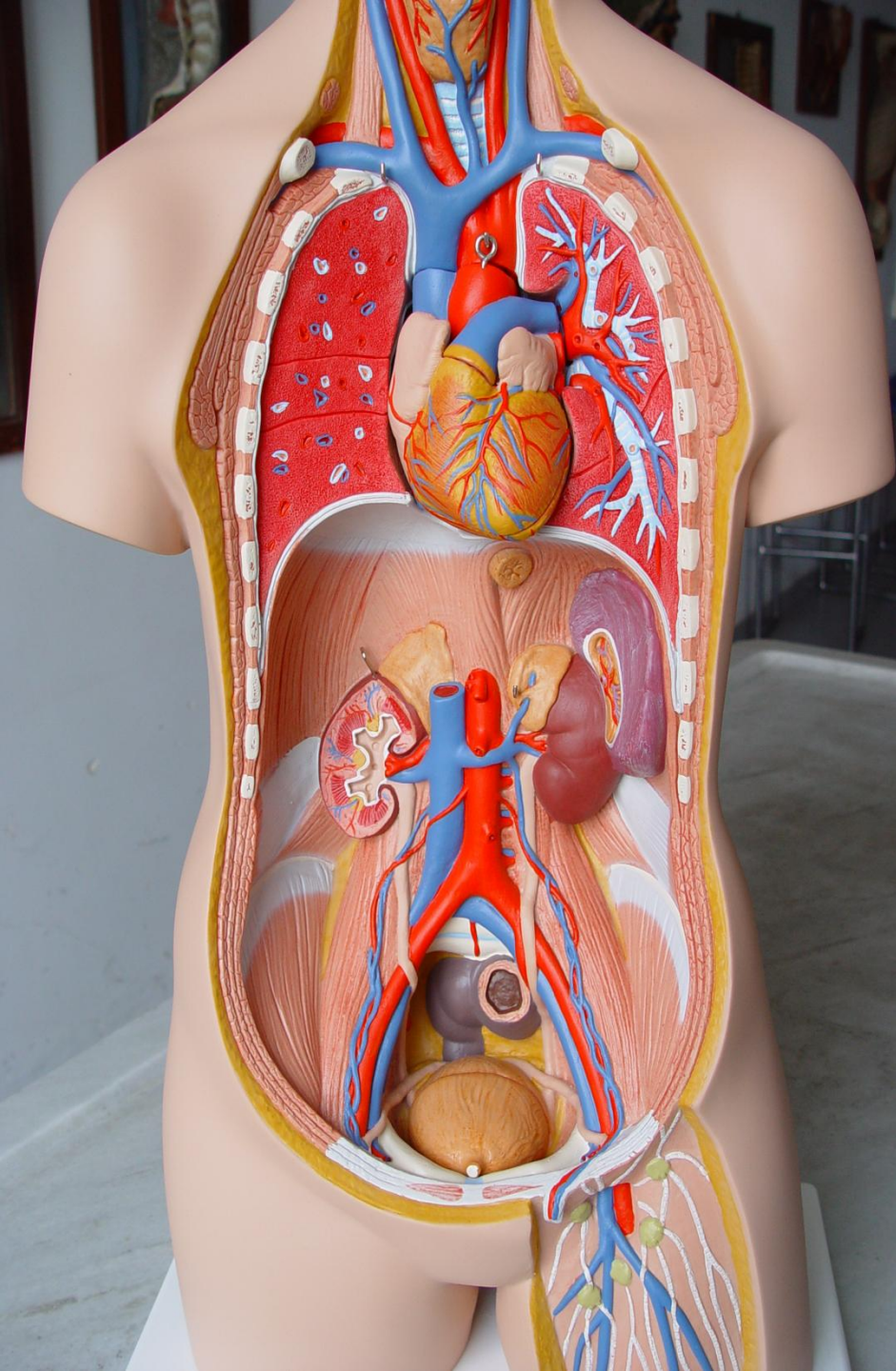


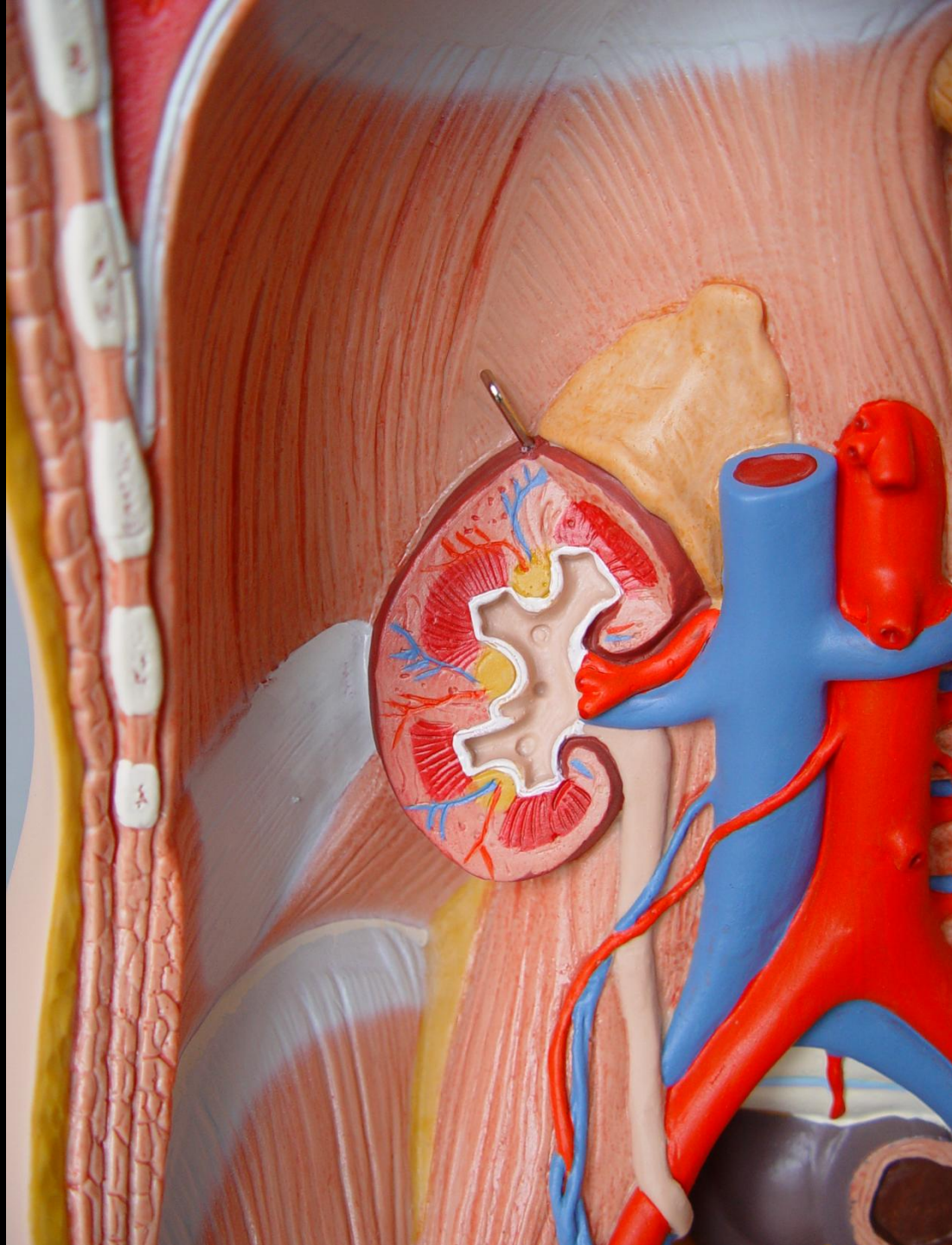
M. López Soler
O. Roda Murillo



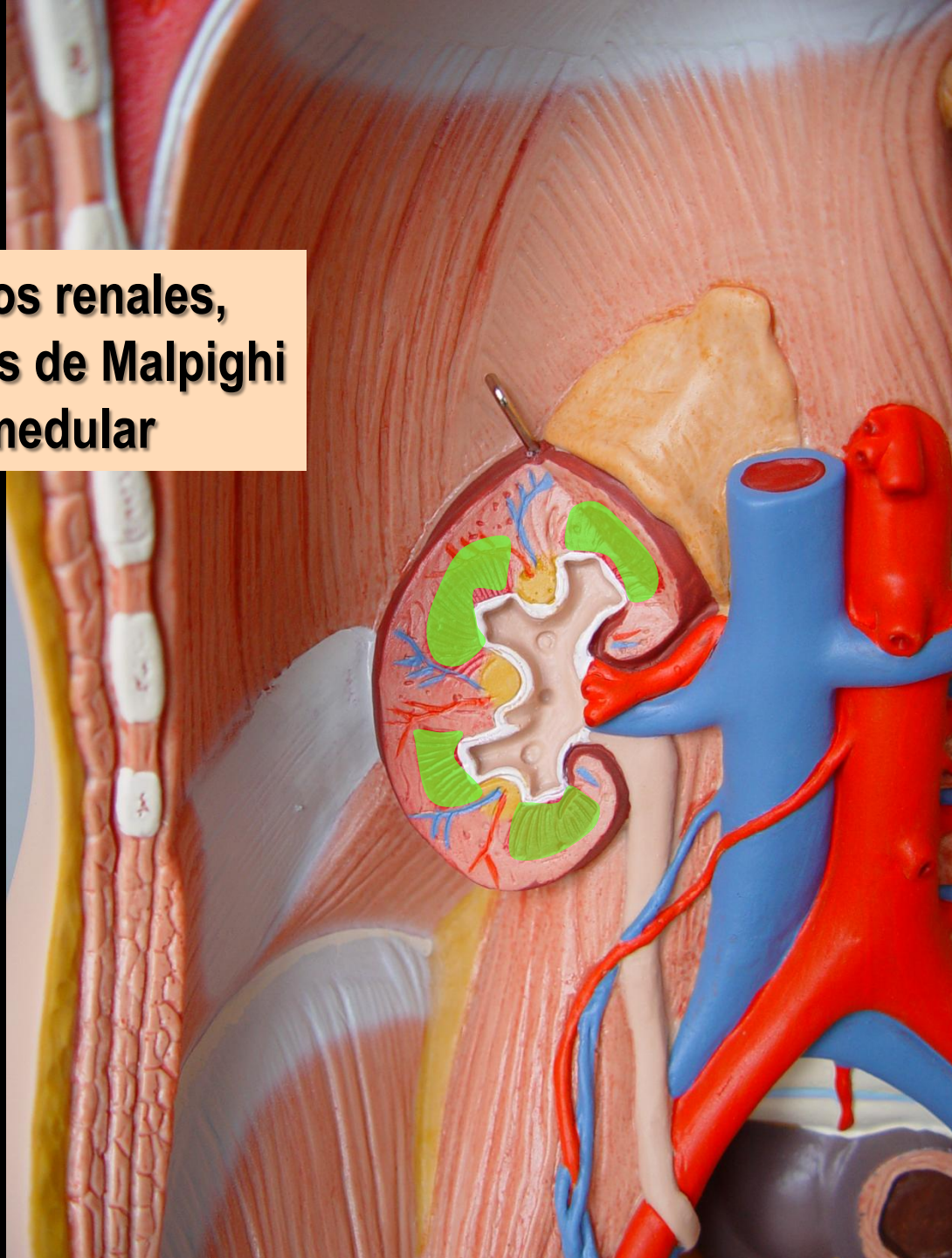
CÁPSULA ADIPOSITA DEL RIÑÓN

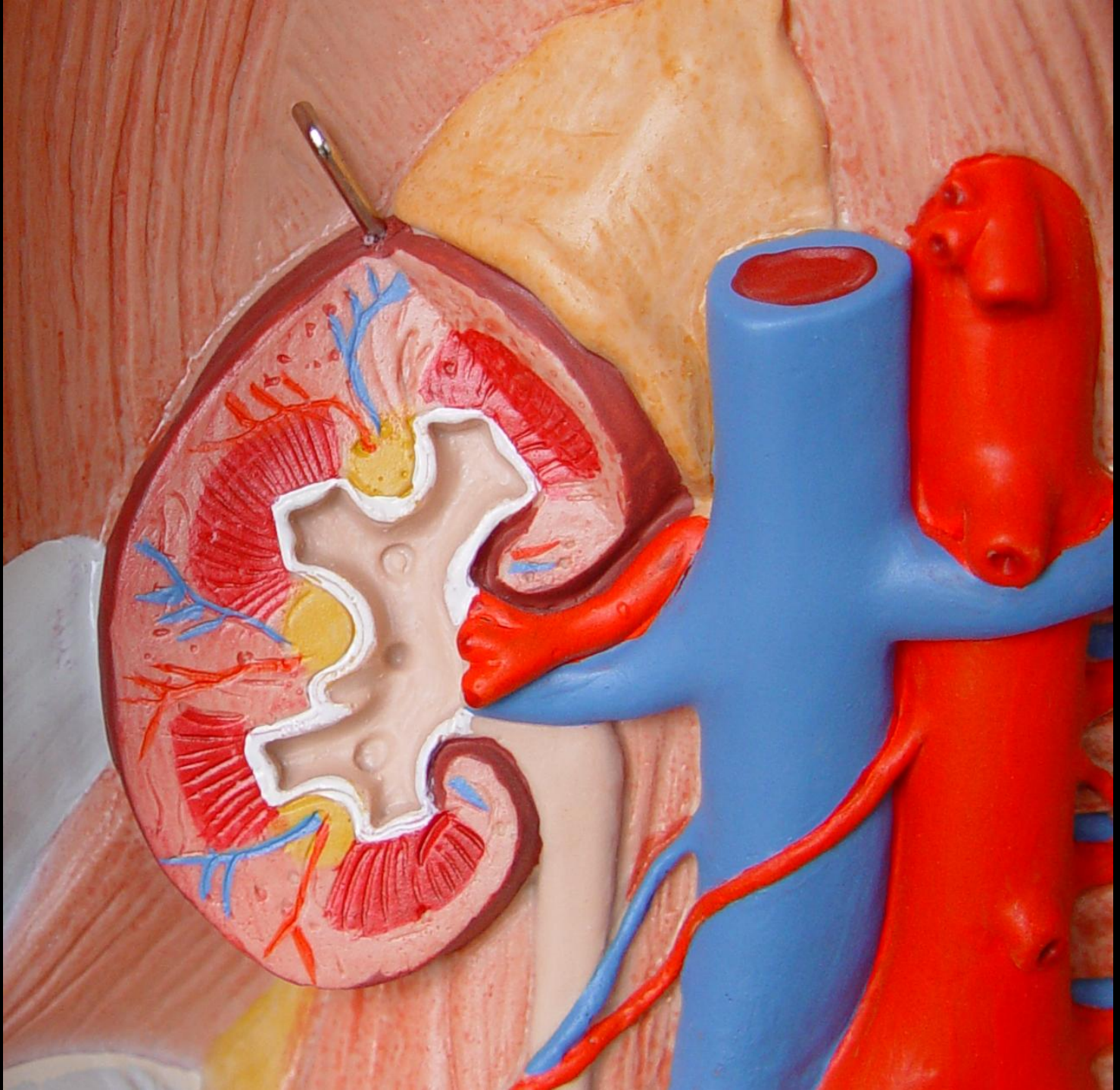
M. López Soler
O. Roda Murillo



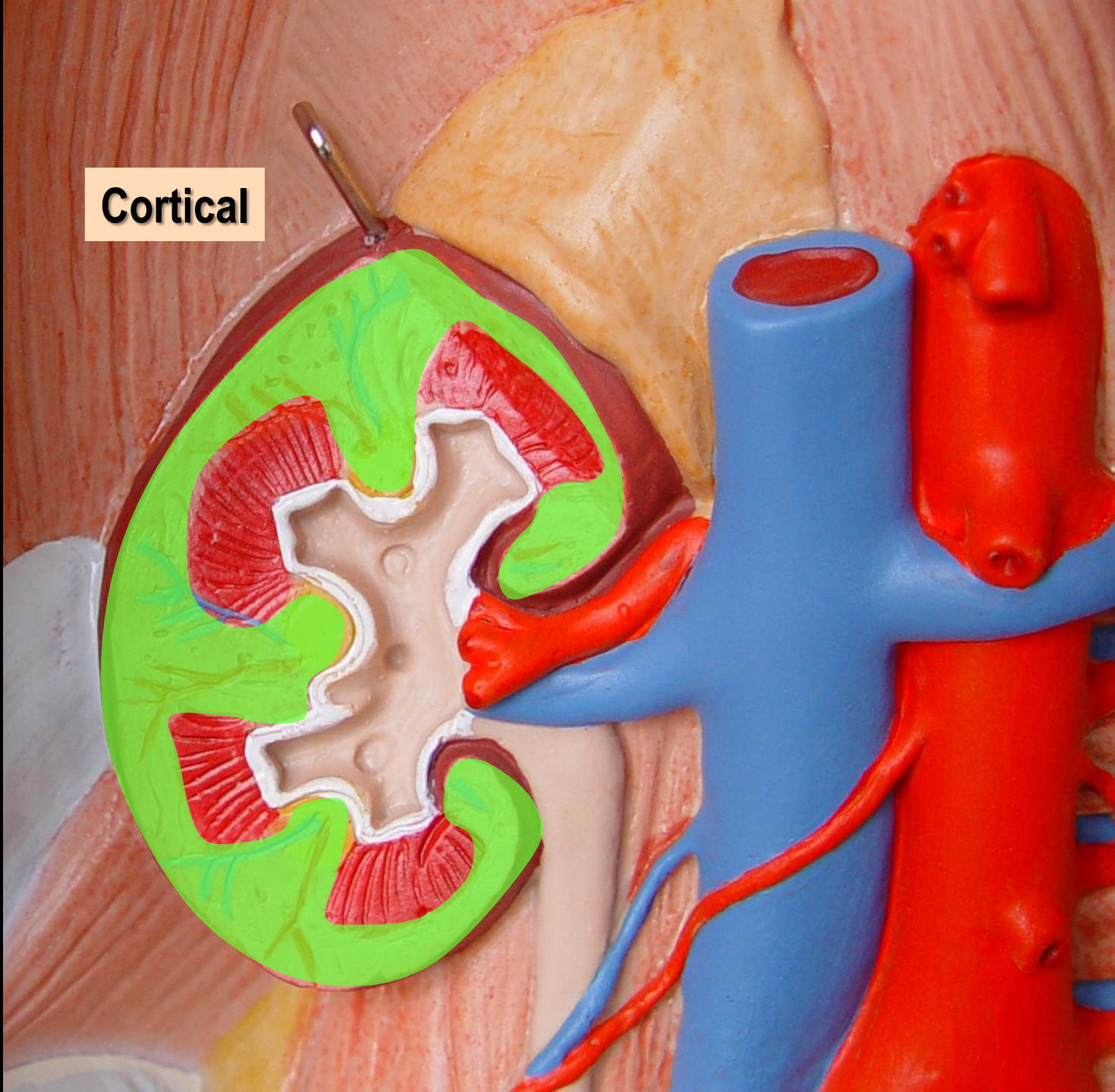


**Lóbulos renales,
pirámides de Malpighi
o medular**

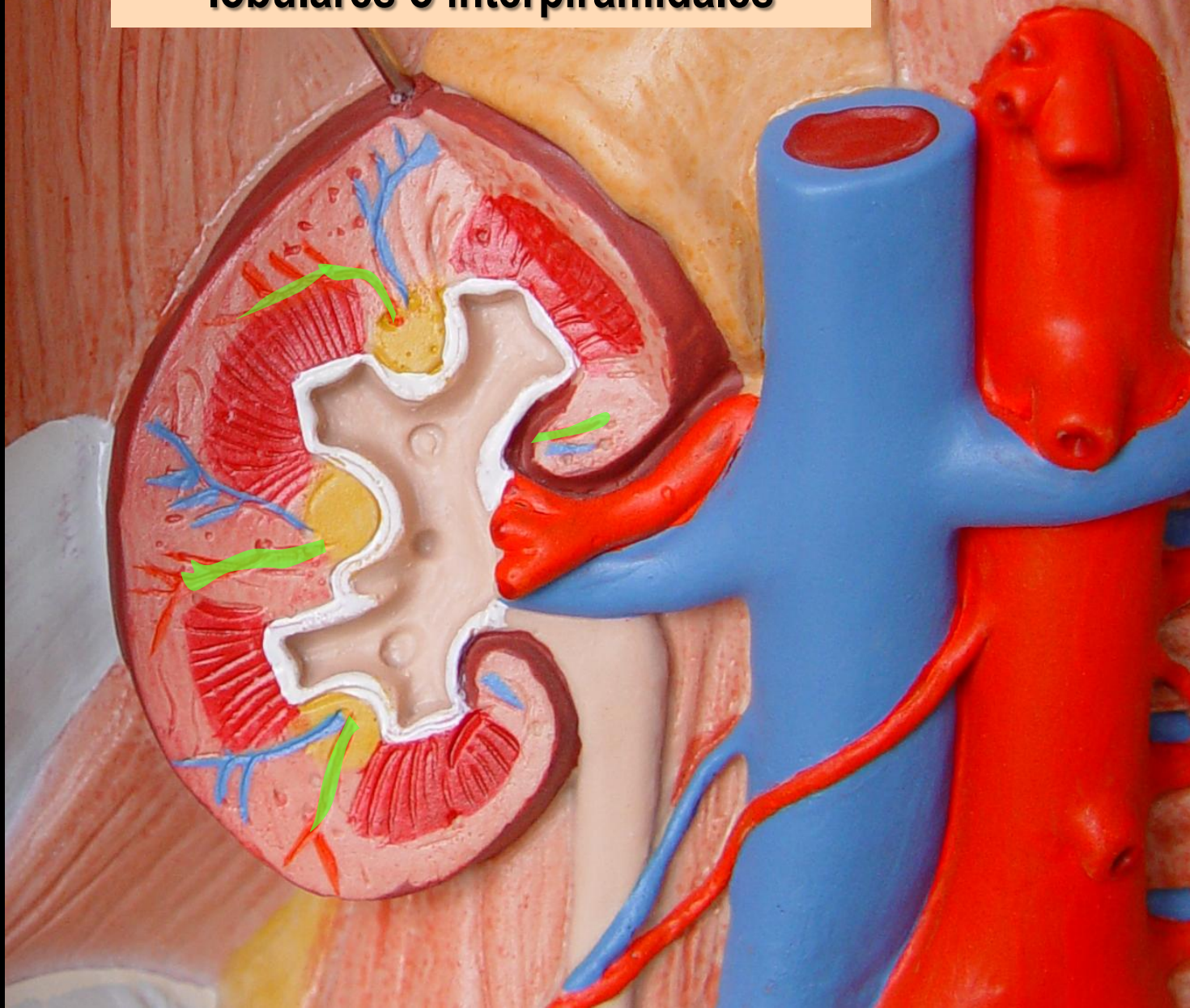




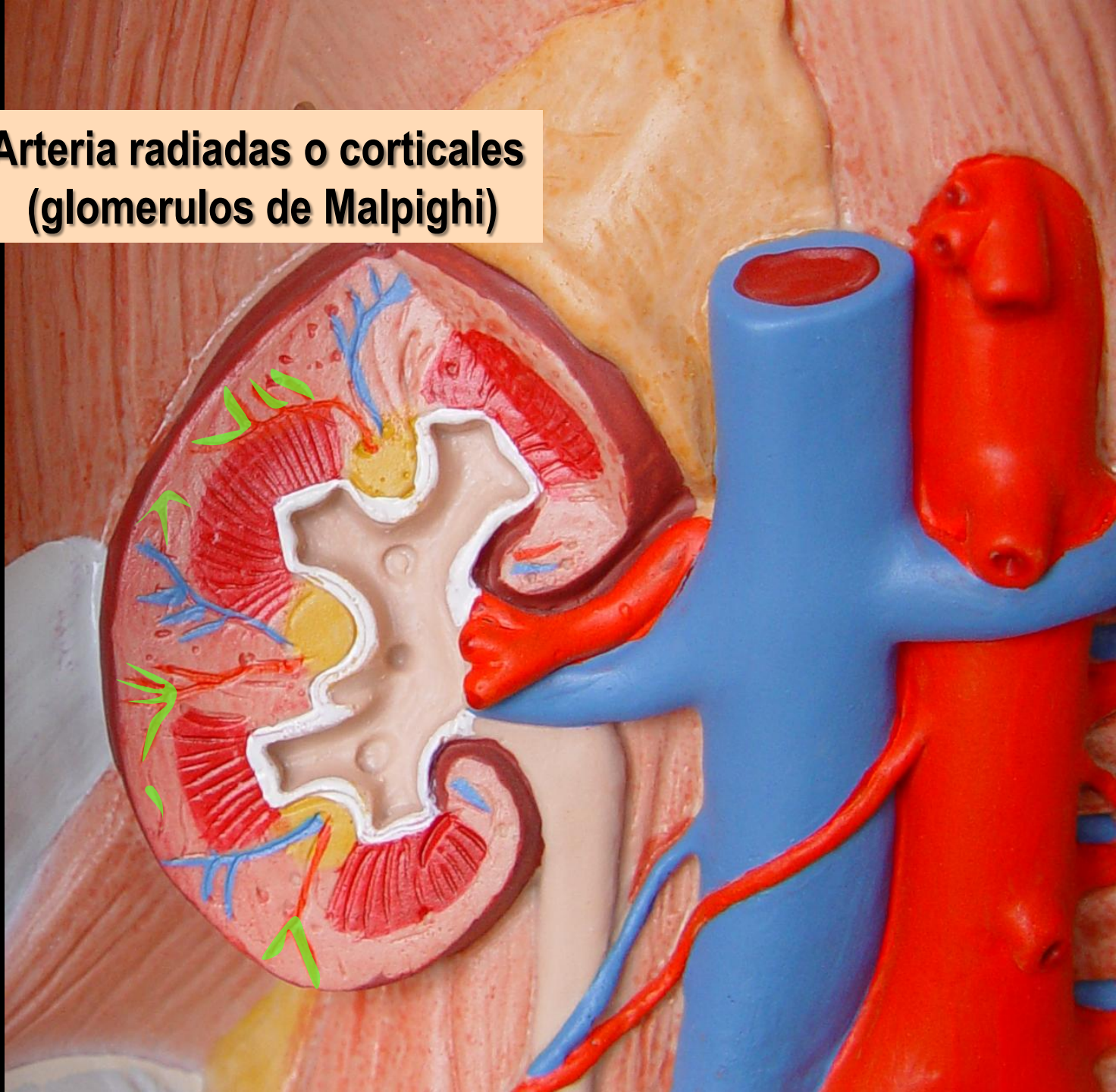
Cortical



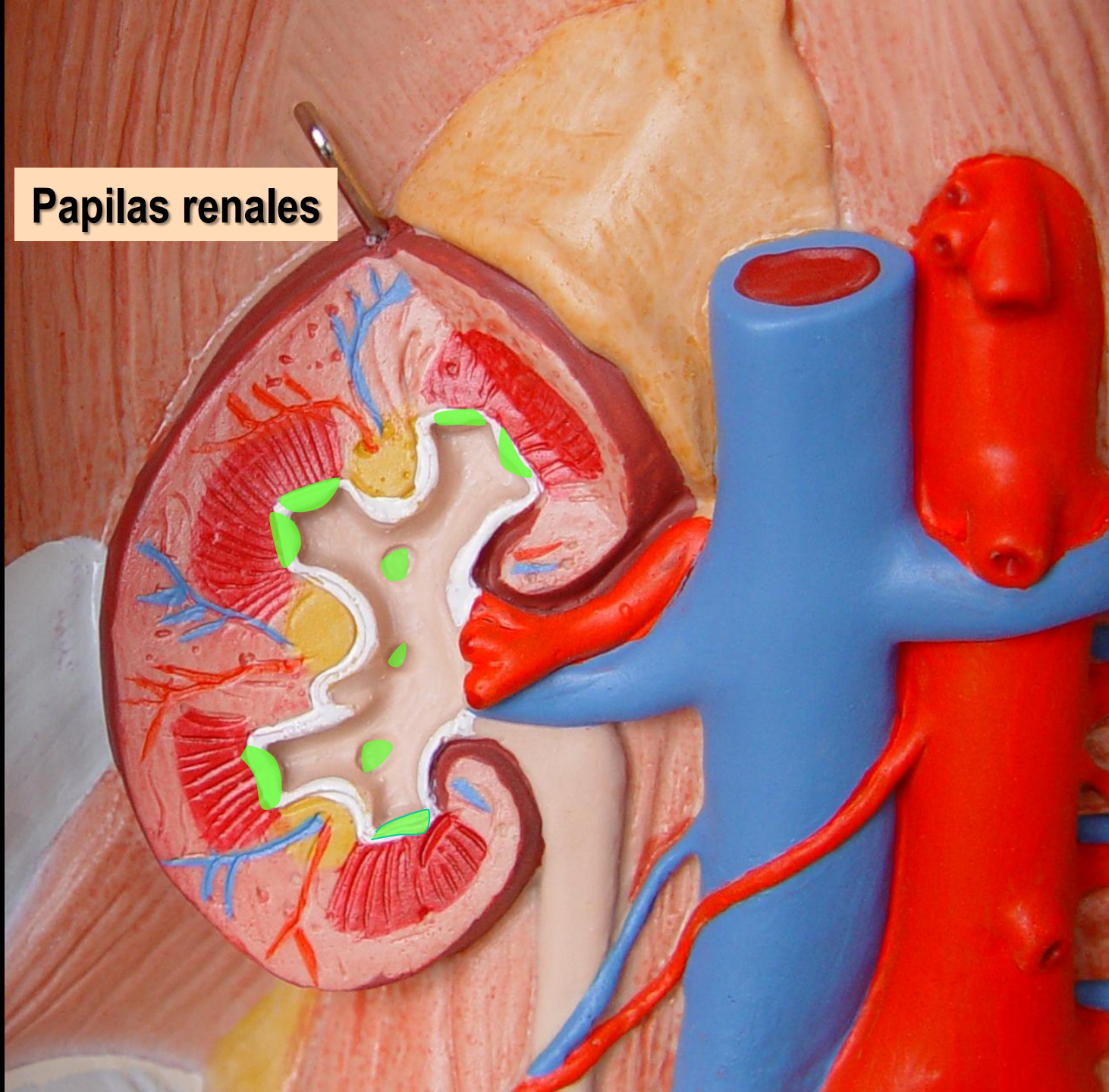
**Arterias peripiramidales
lobulares o interpiramidales**

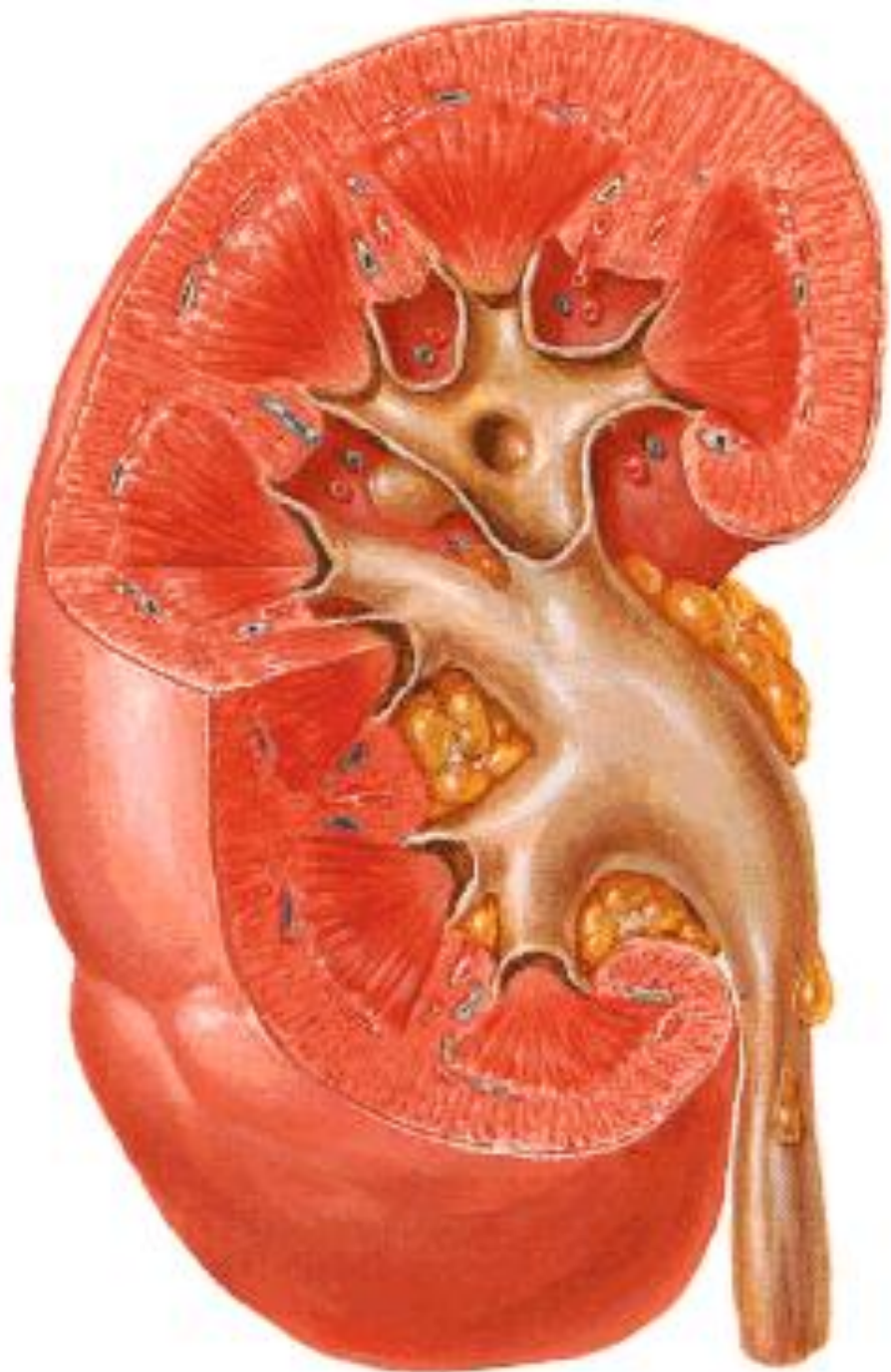


**Arteria radiadas o corticales
(glomerulos de Malpighi)**

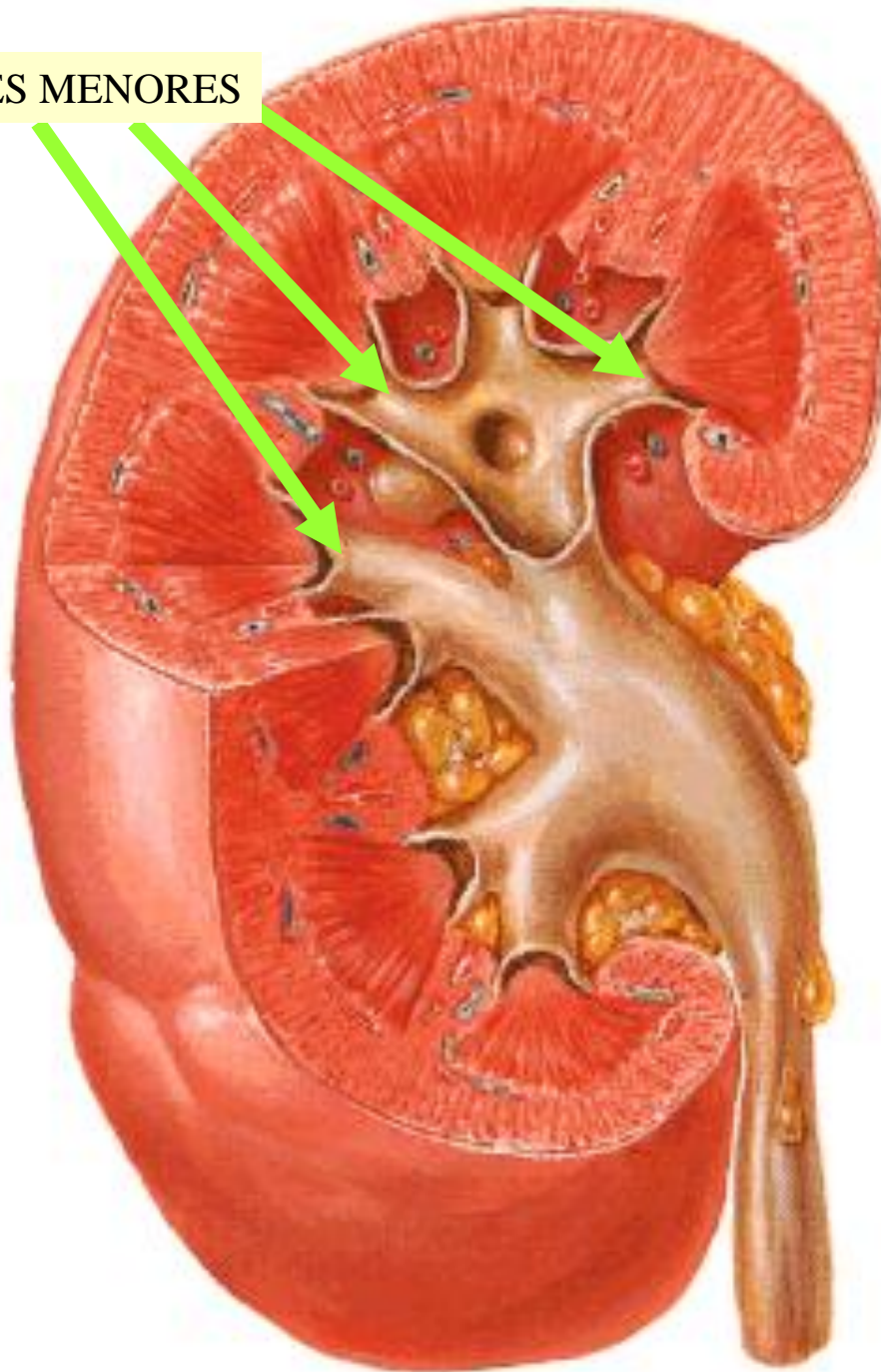


Papilas renales

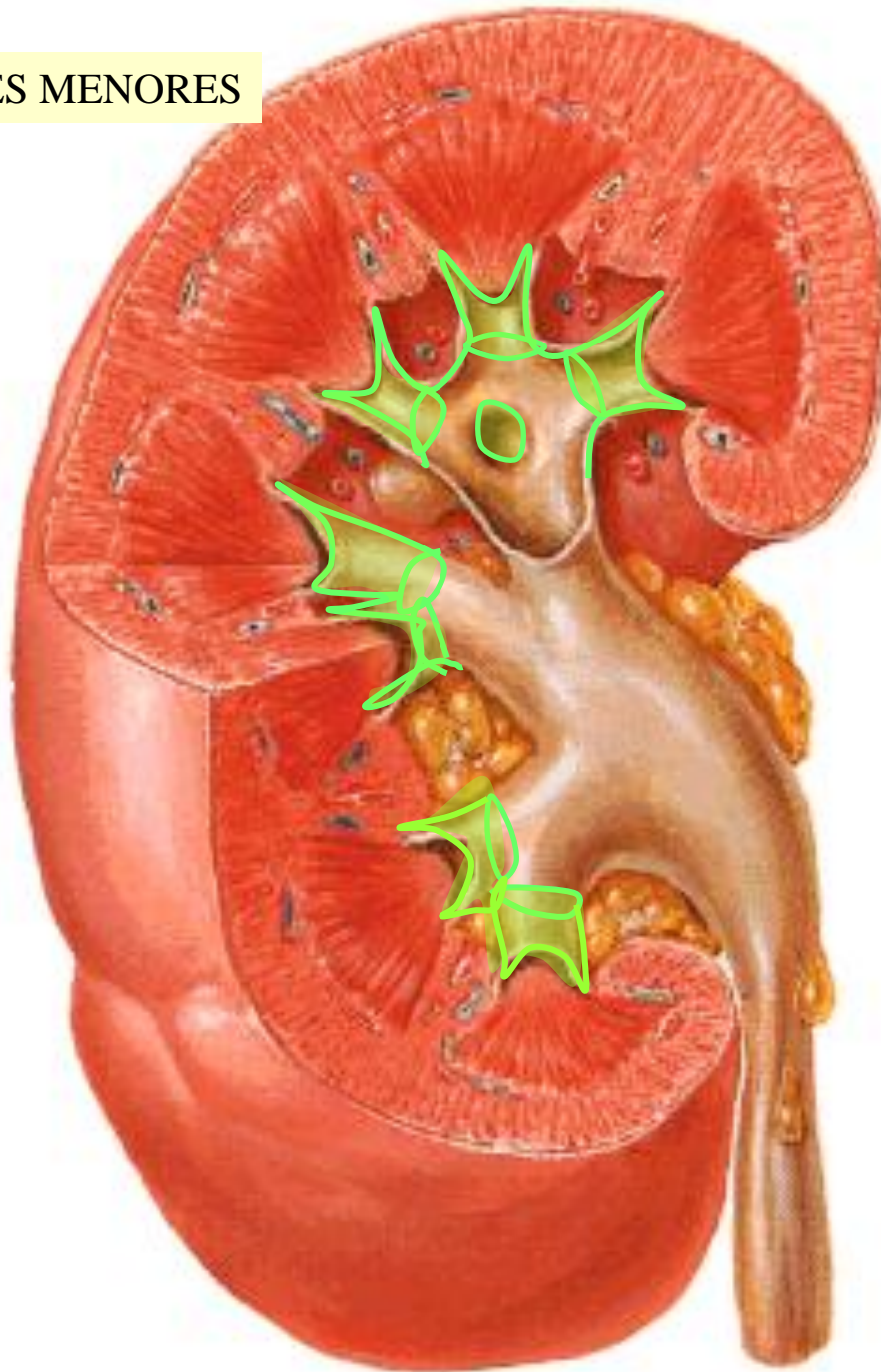




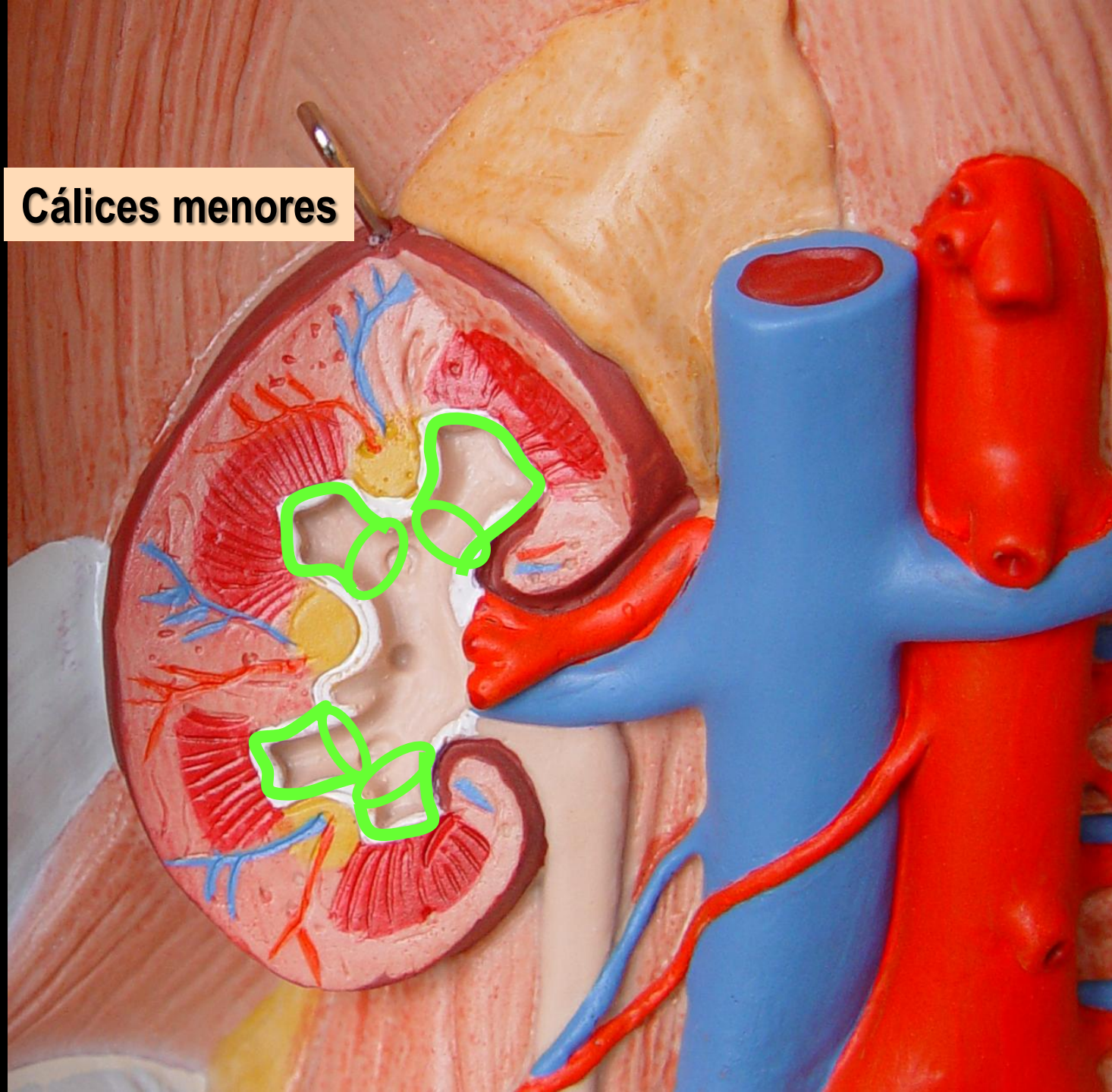
(10-20) CALICES MENORES

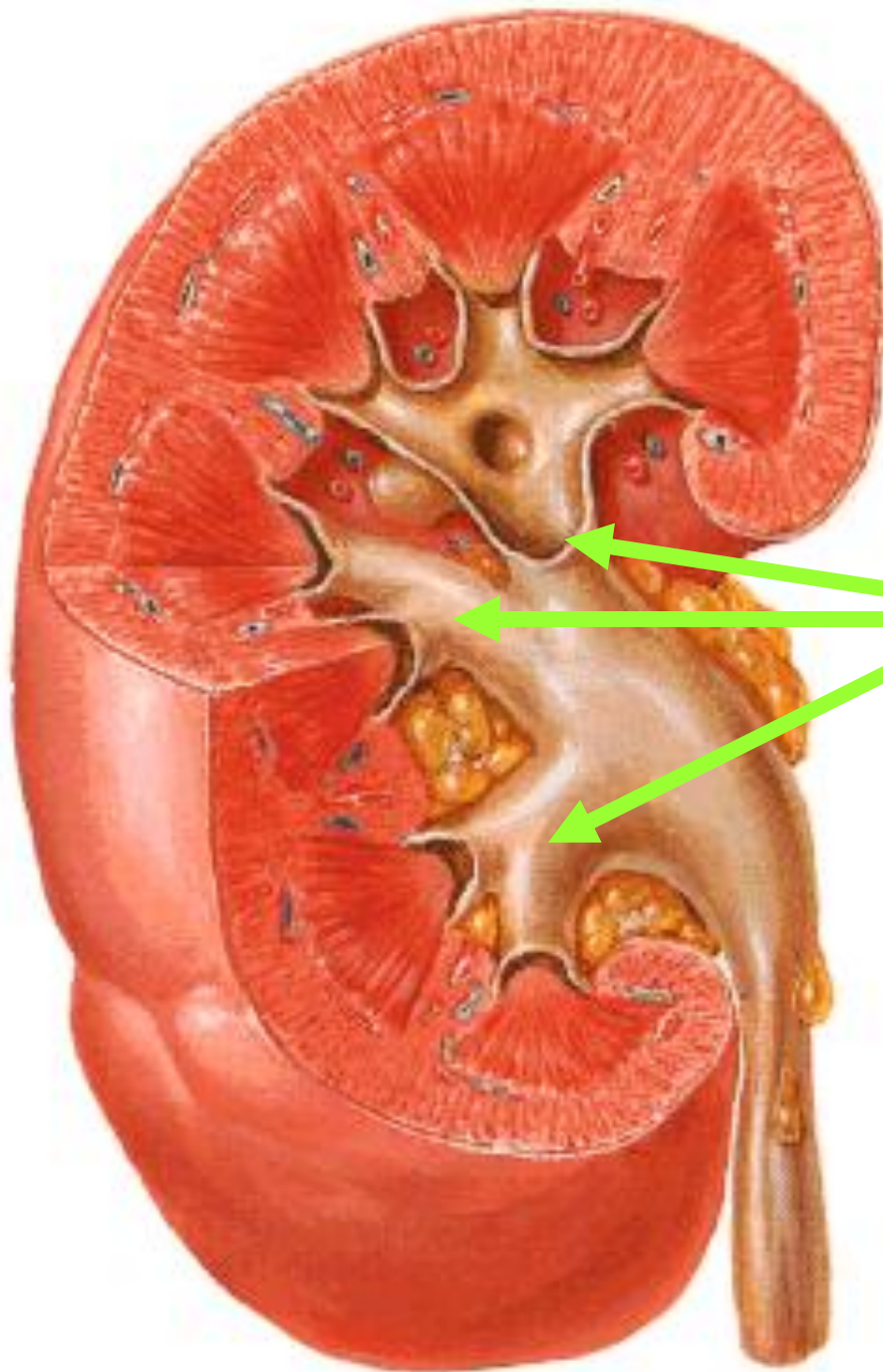


(10-20) CALICES MENORES

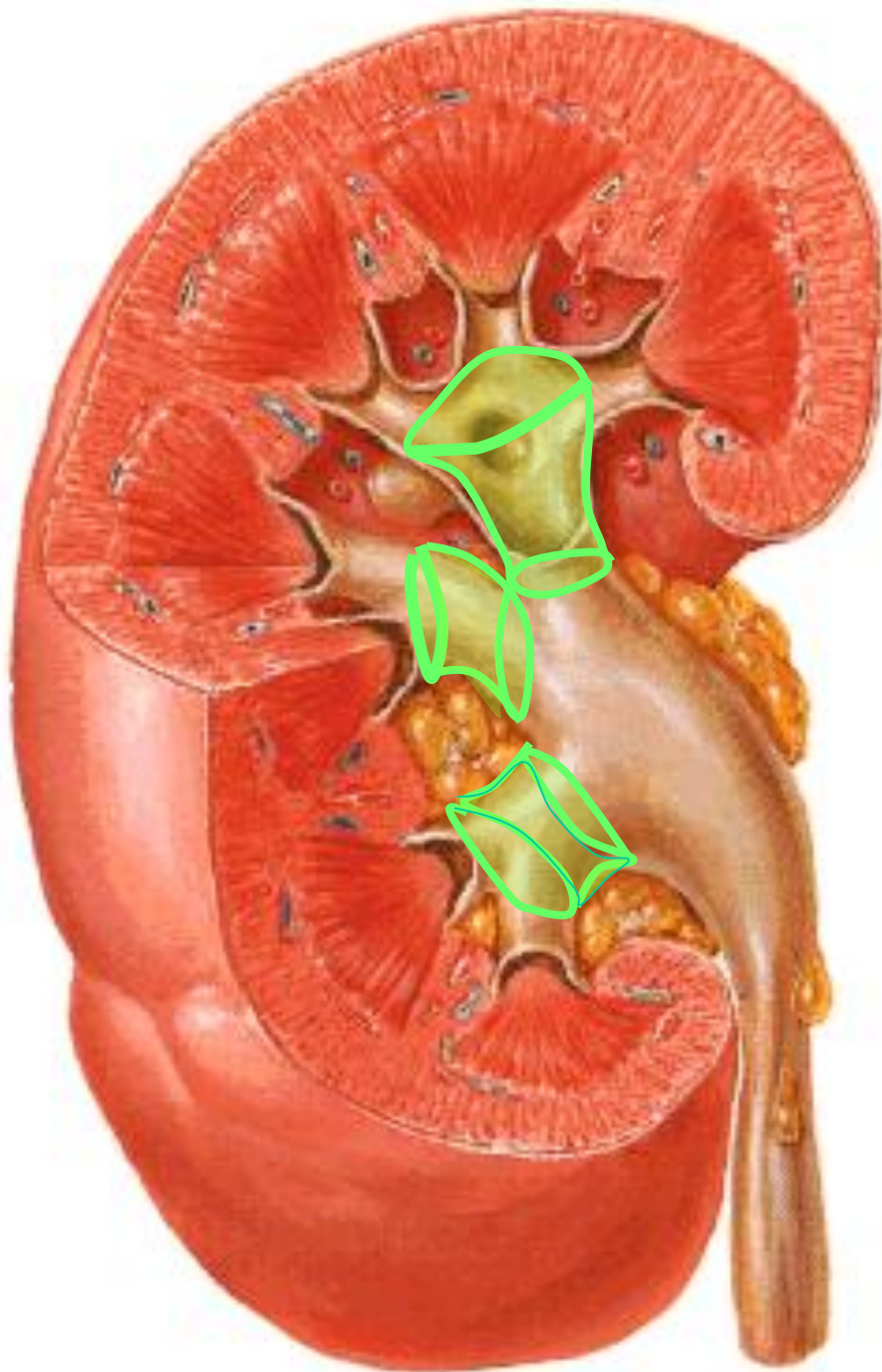


Cállices menores



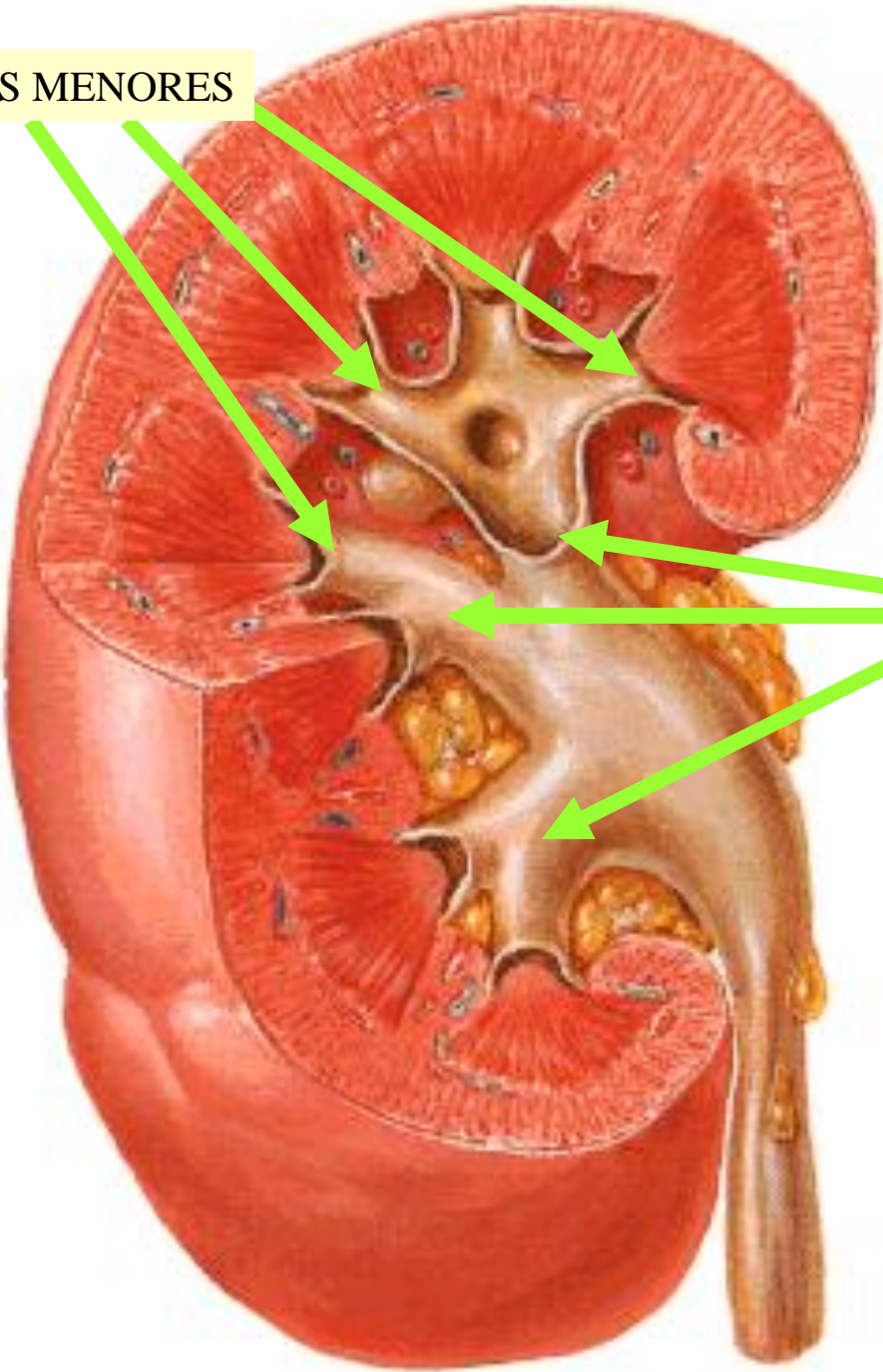


(2-5) CALICES
MAYORES



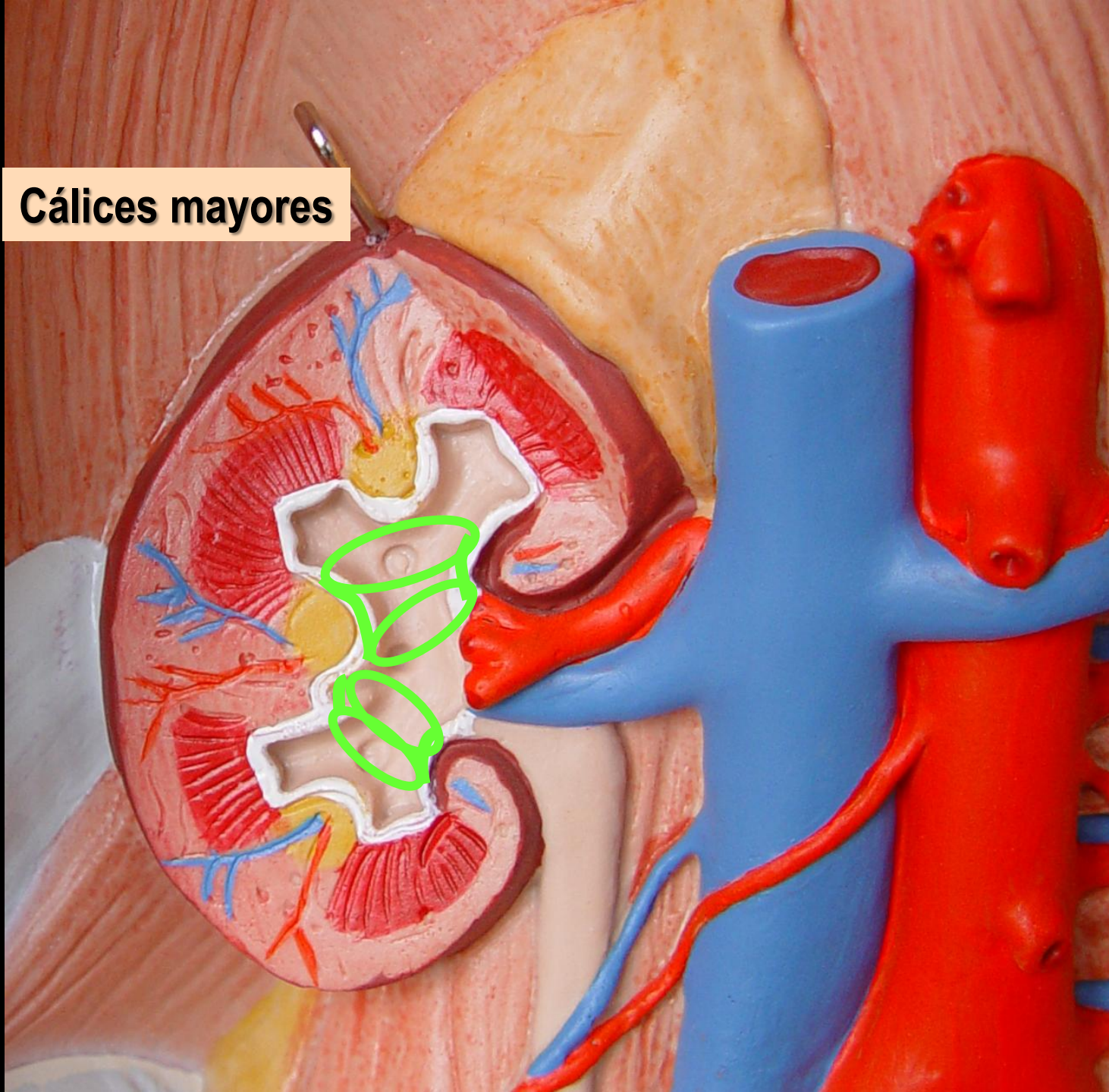
(2-5) CALICES
MAYORES

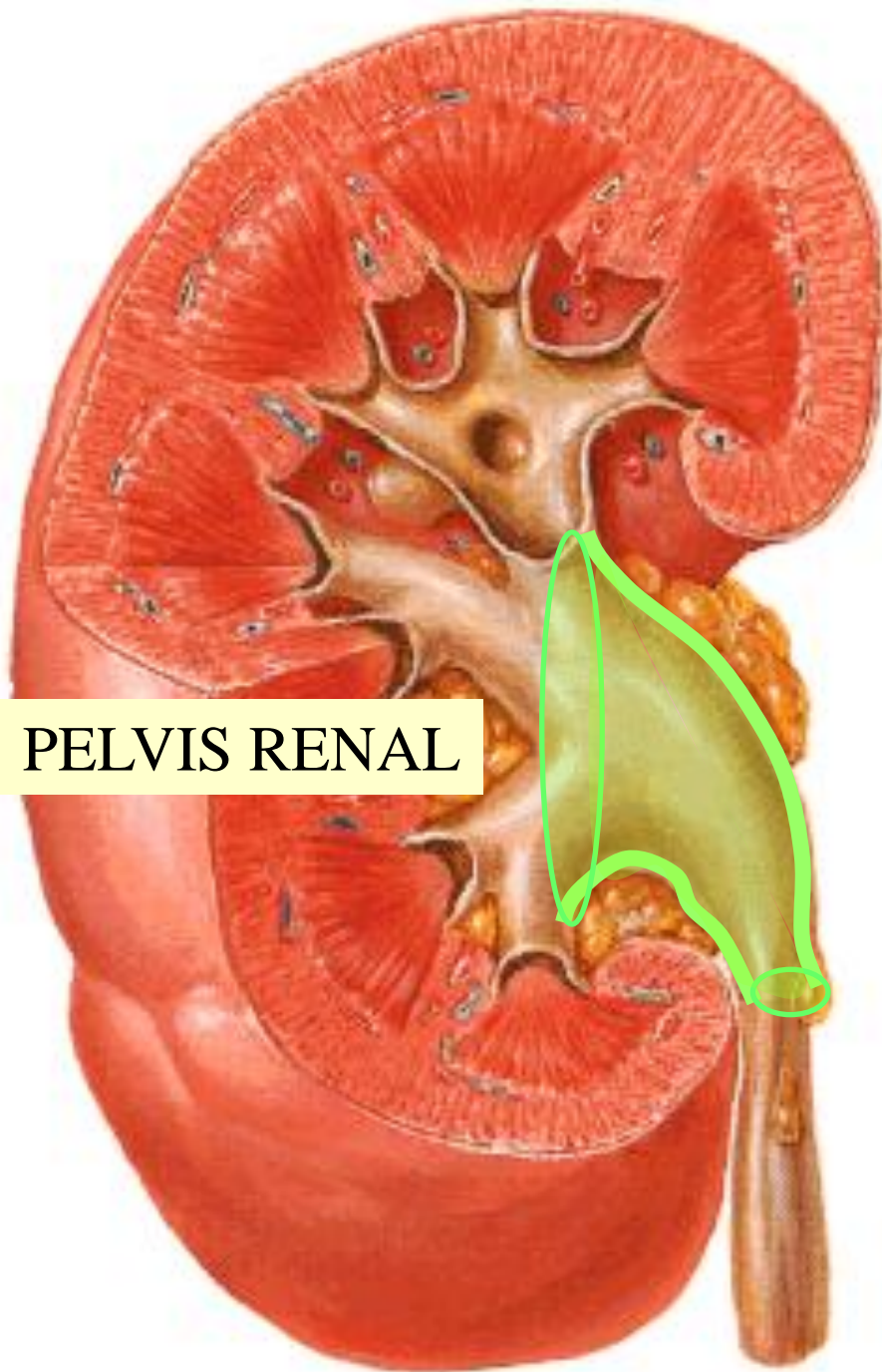
(10-20) CALICES MENORES



(2-5) CALICES MAYORES

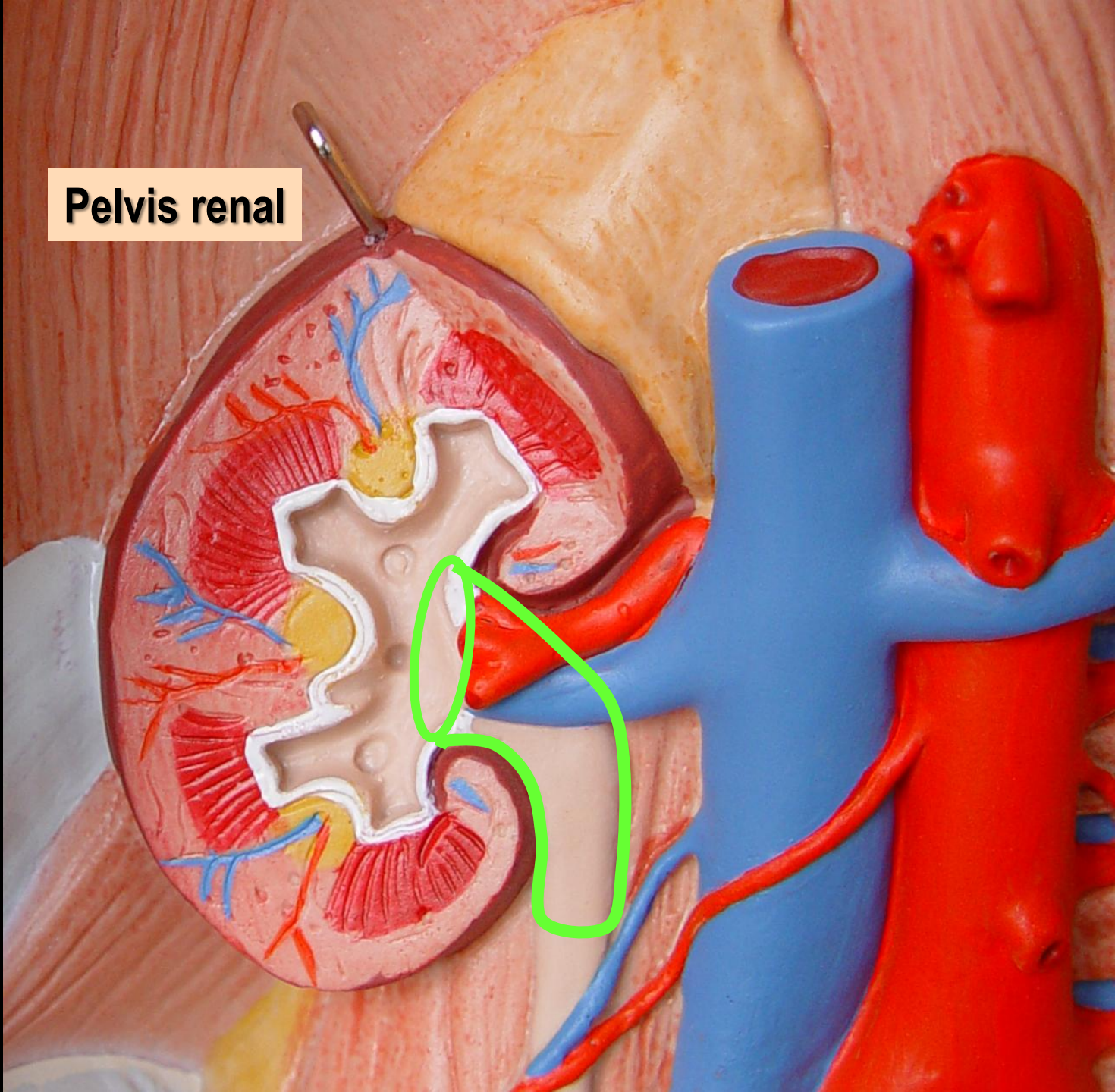
Cálices mayores

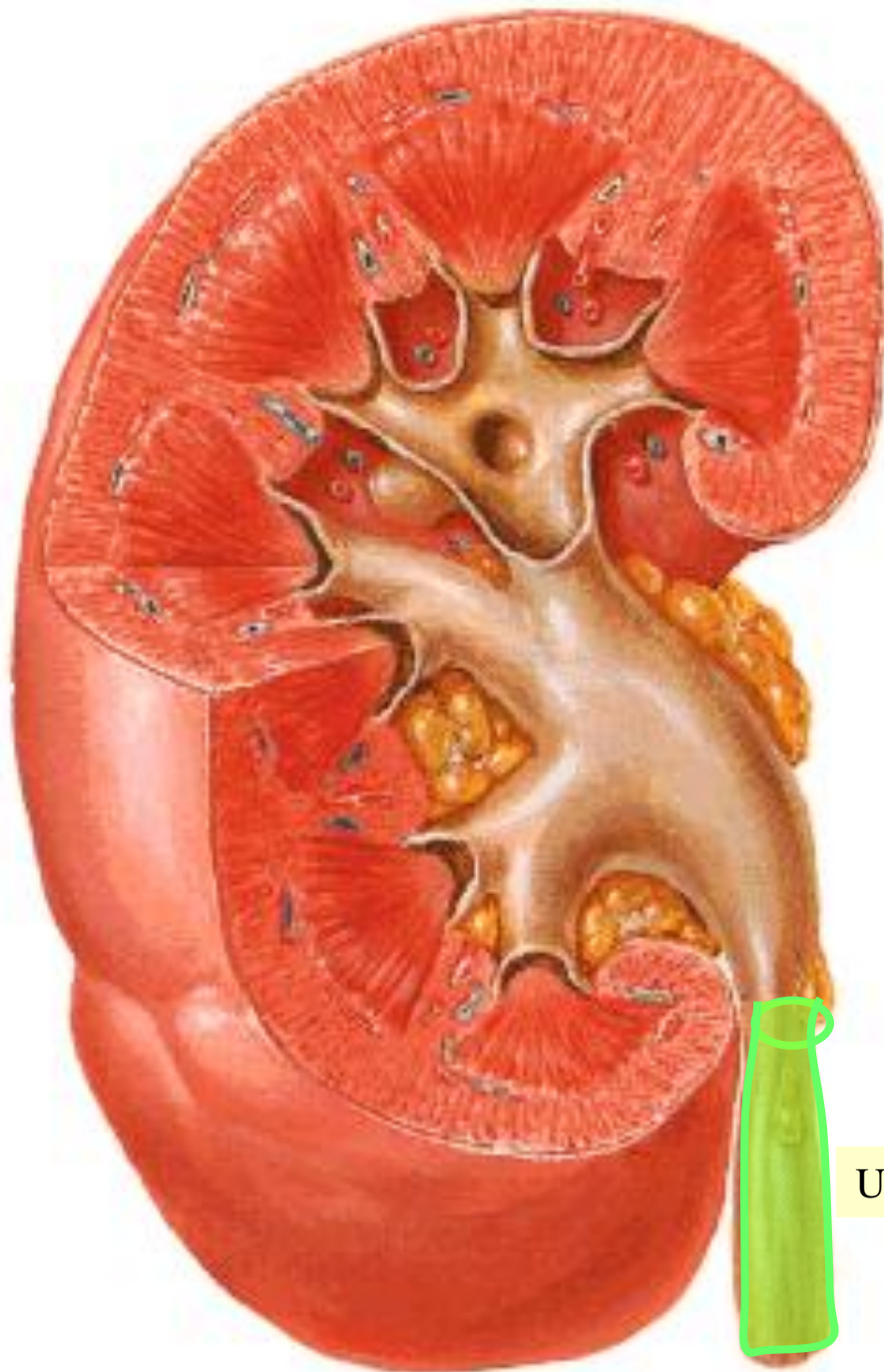




PELVIS RENAL

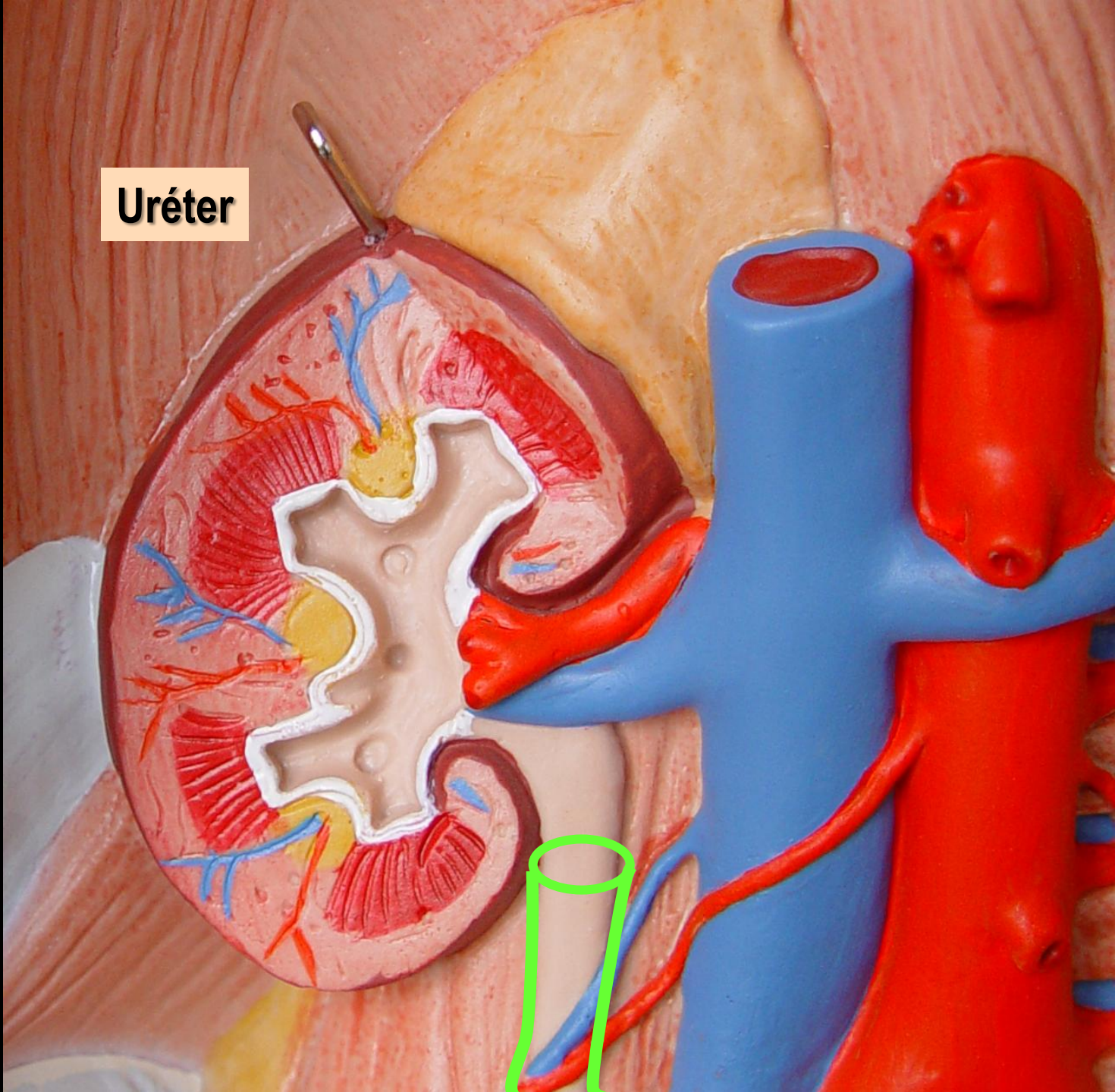
Pelvis renal



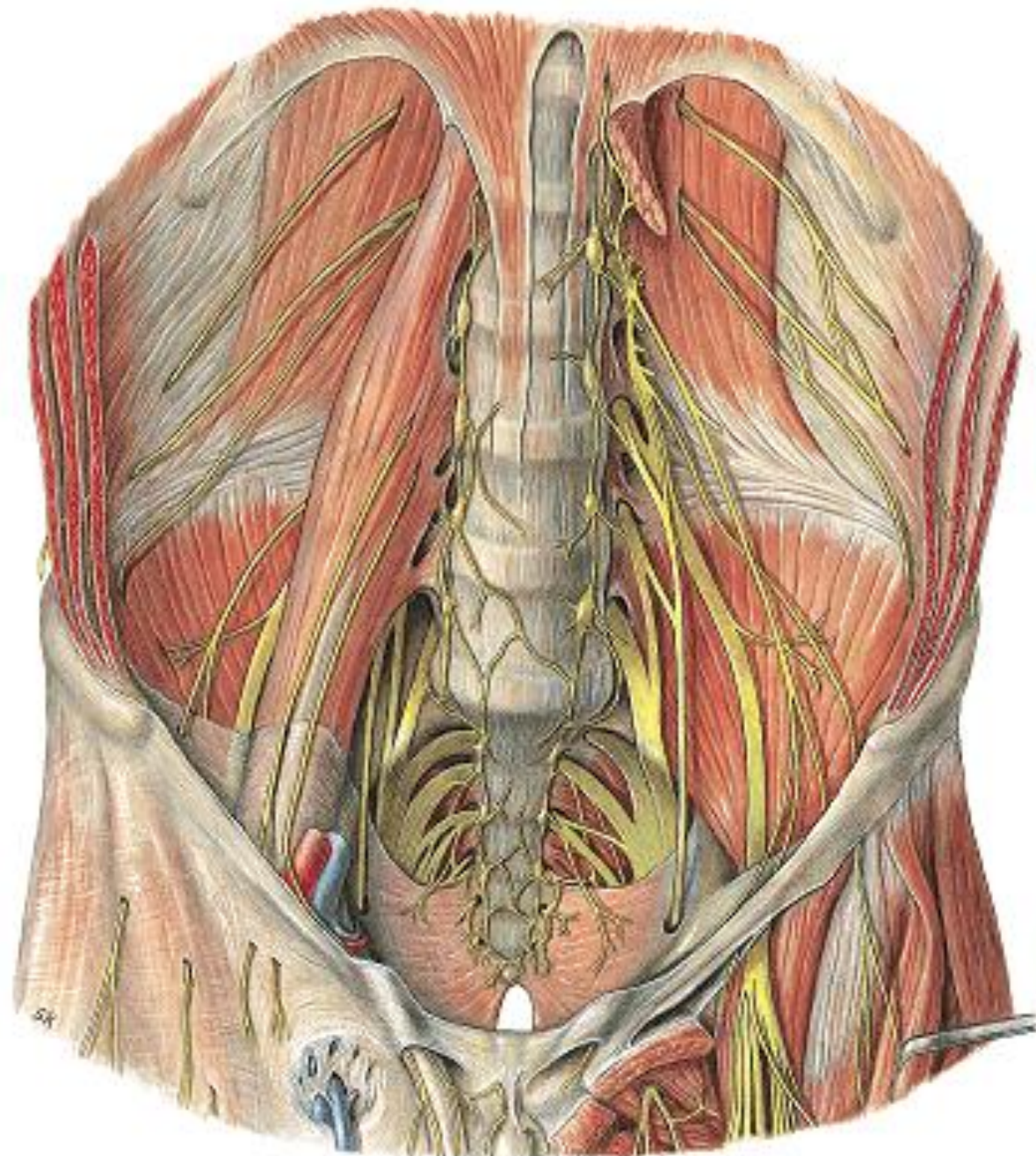


URETER

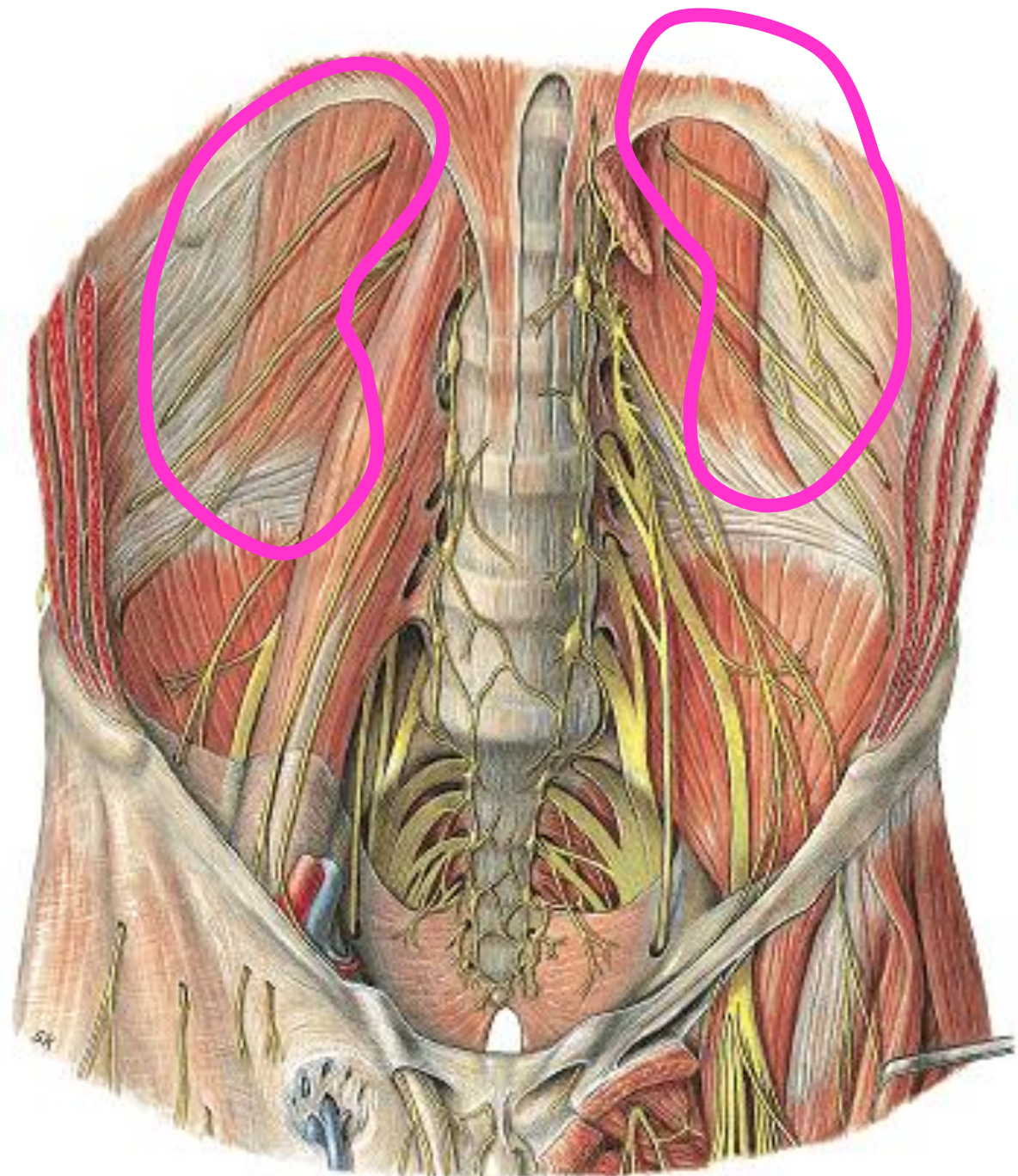
Uréter



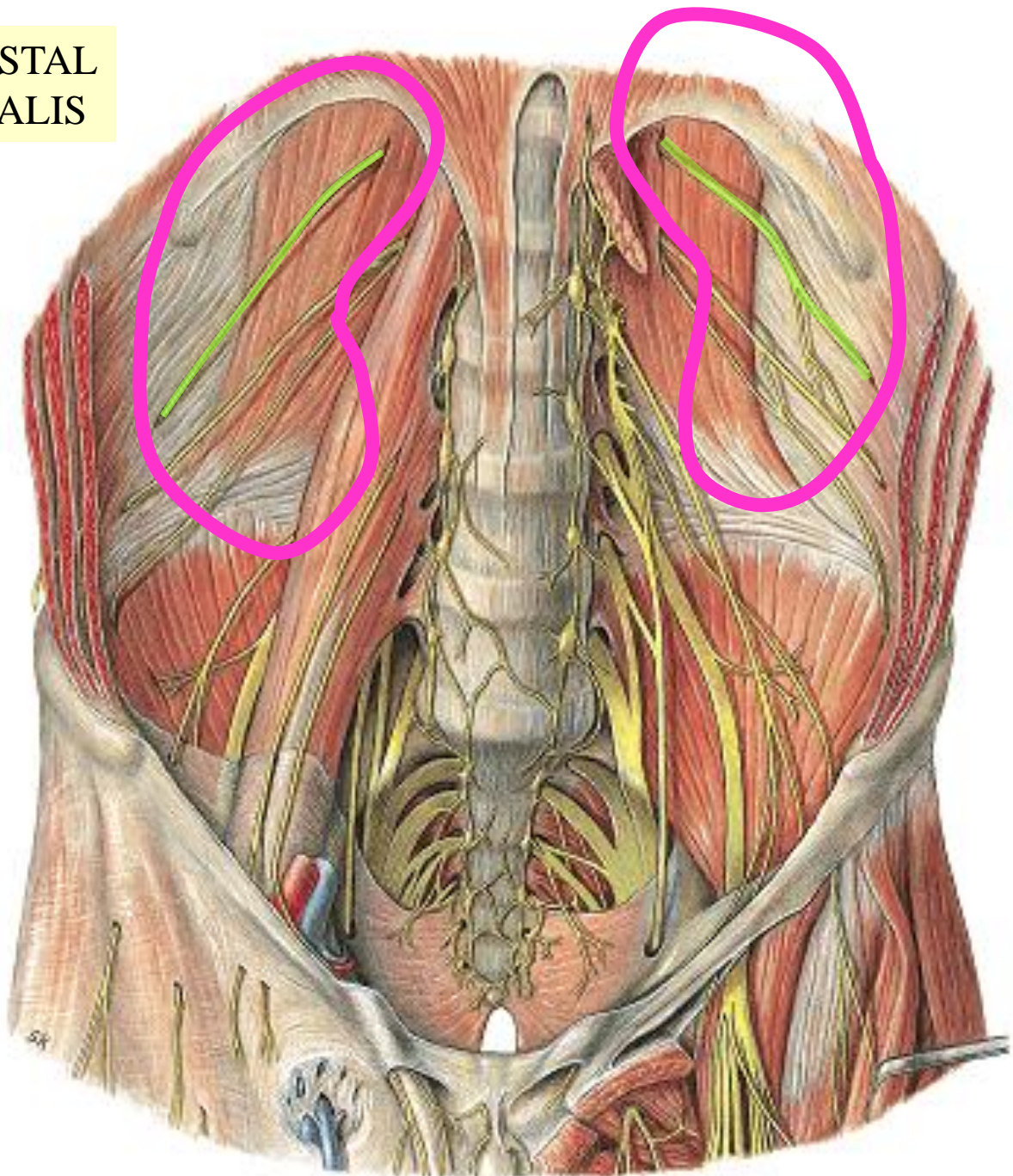
**RELACIONES
DE LOS RIÑONES**

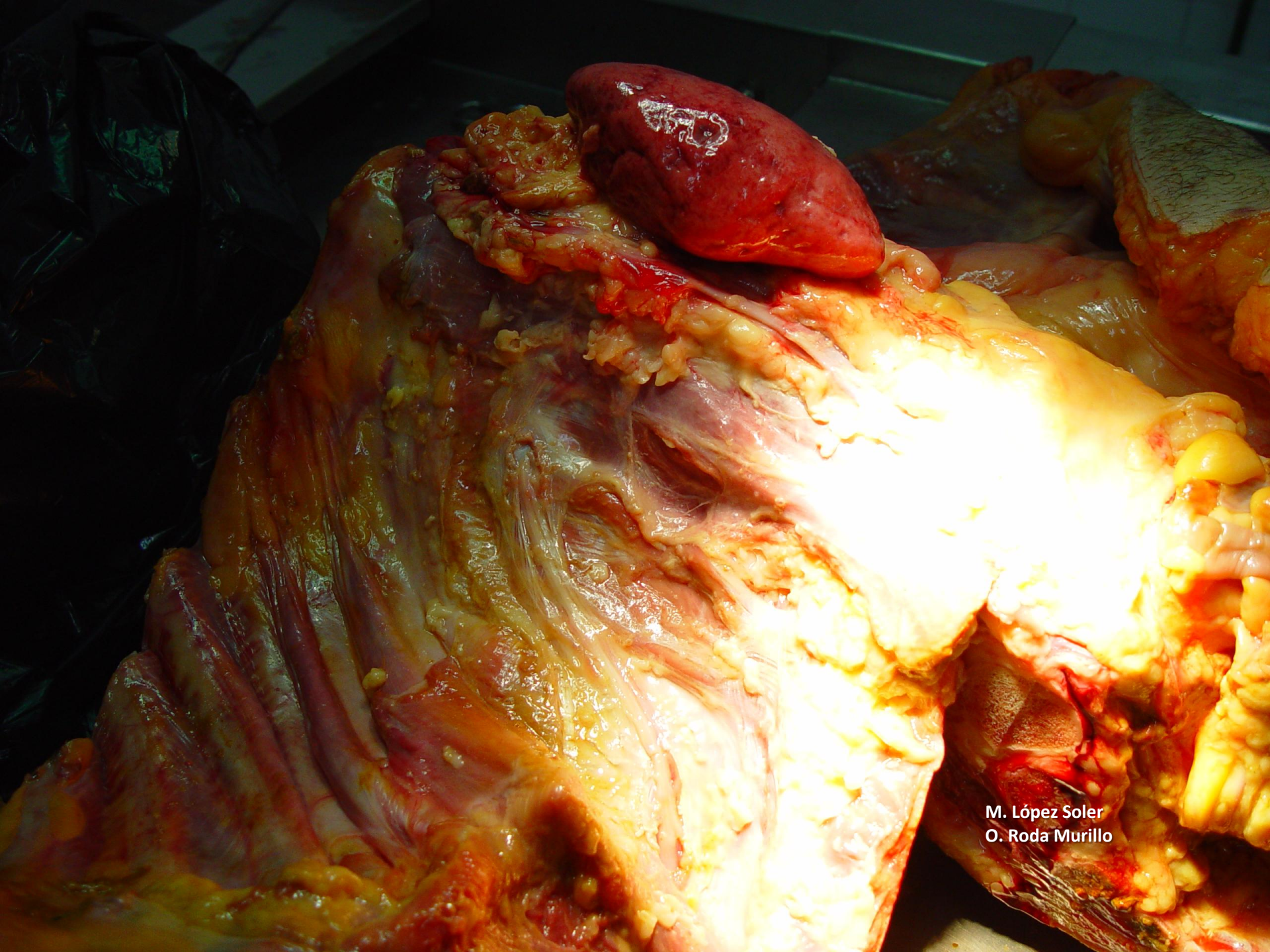


RIÑONES

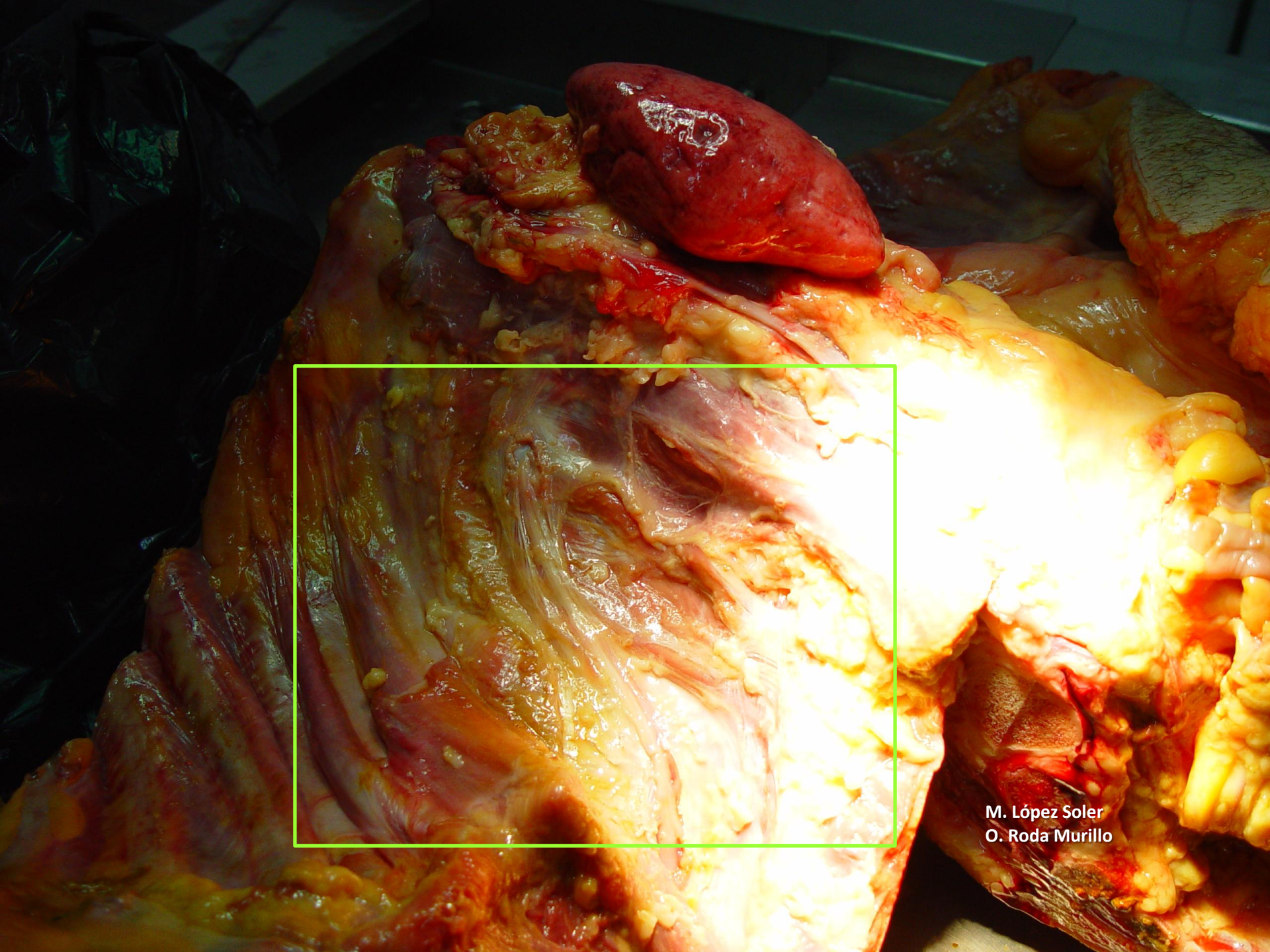


XII INTERCOSTAL
N. SUBCOSTALIS





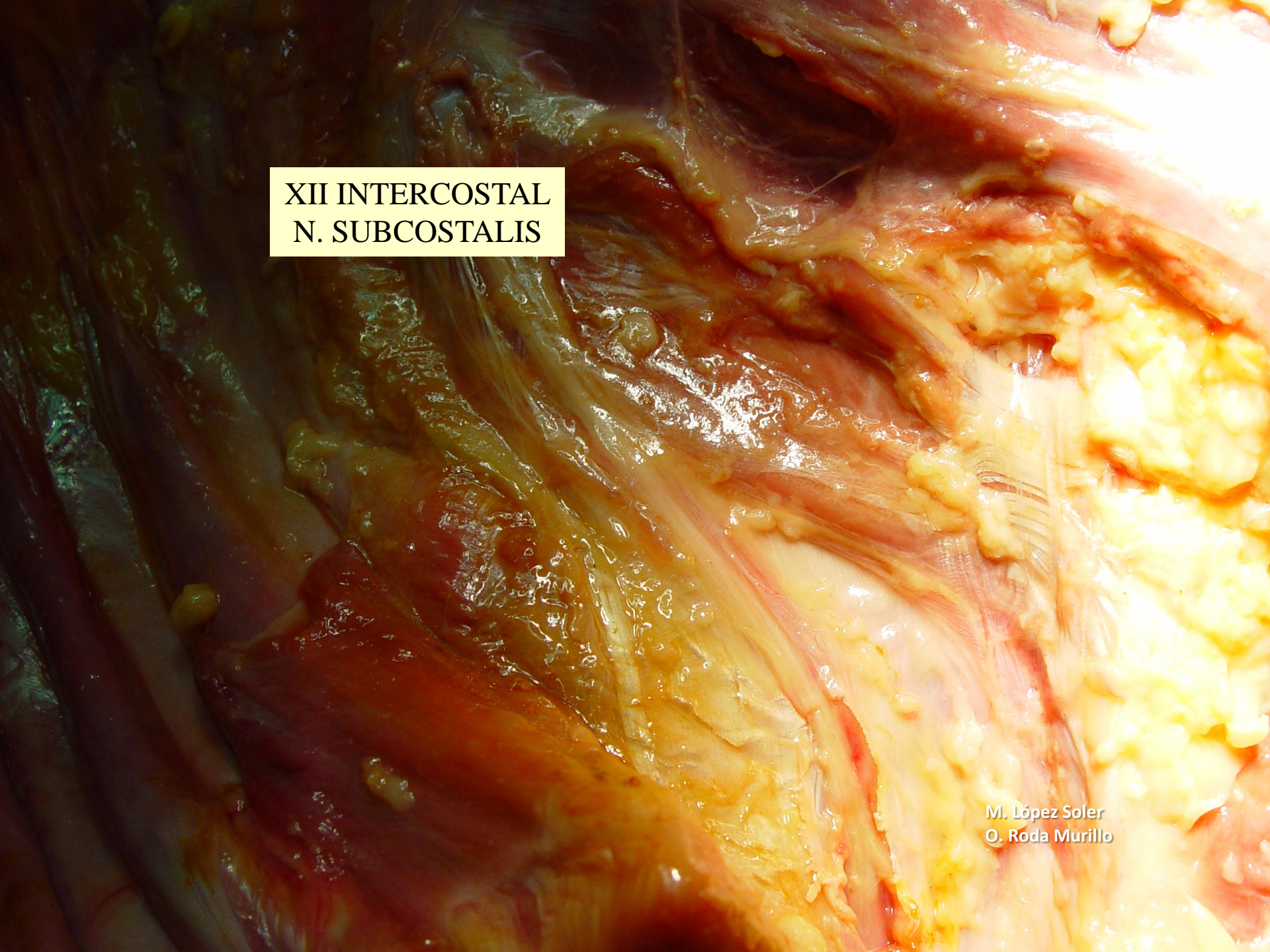
M. López Soler
O. Roda Murillo



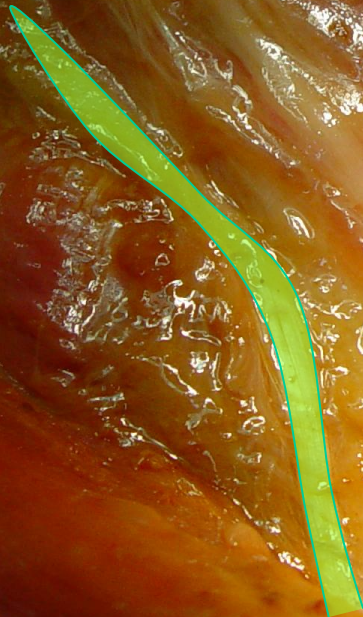
M. López Soler
O. Roda Murillo

XII INTERCOSTAL
N. SUBCOSTALIS

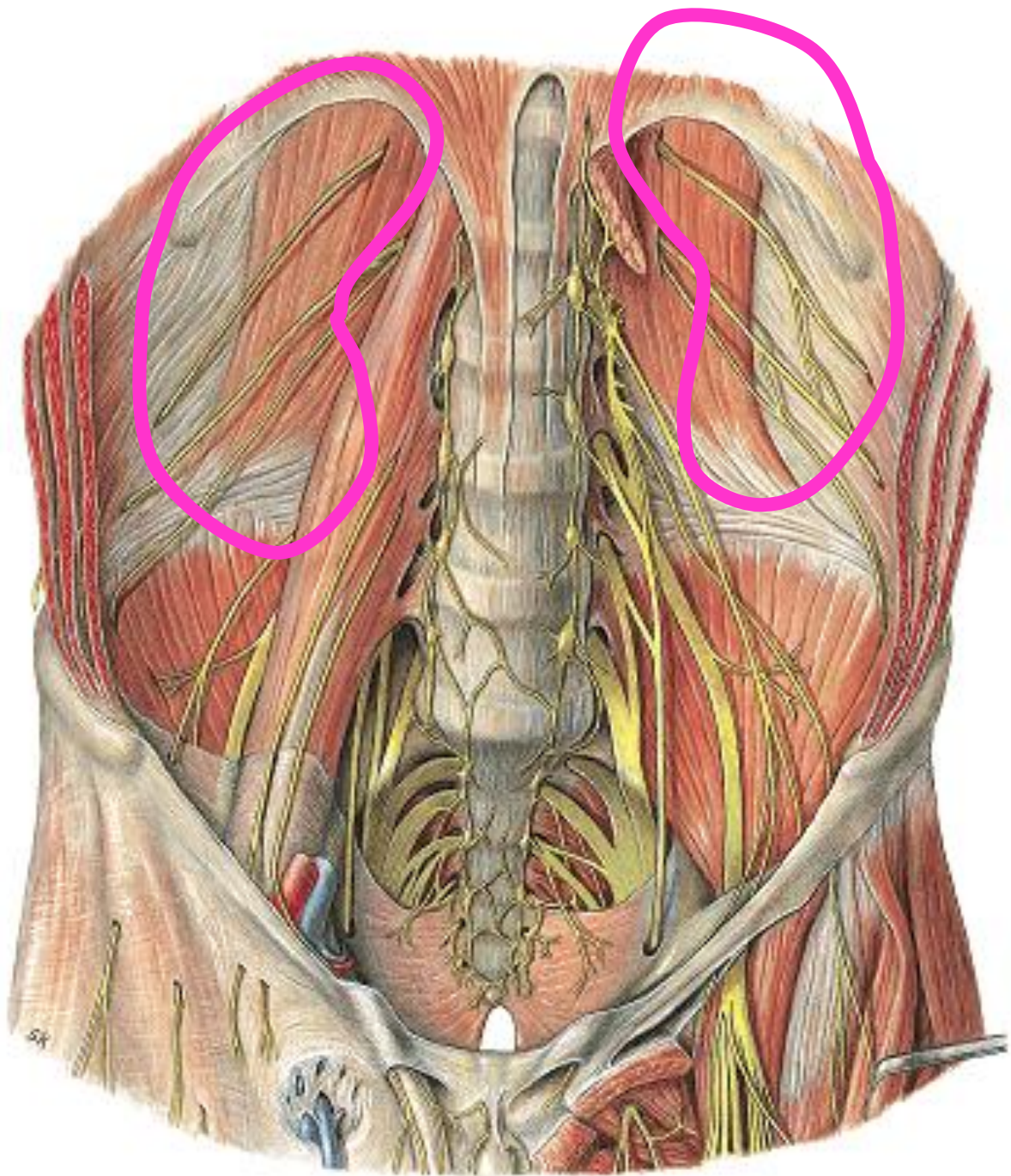
M. López Soler
O. Roda Murillo



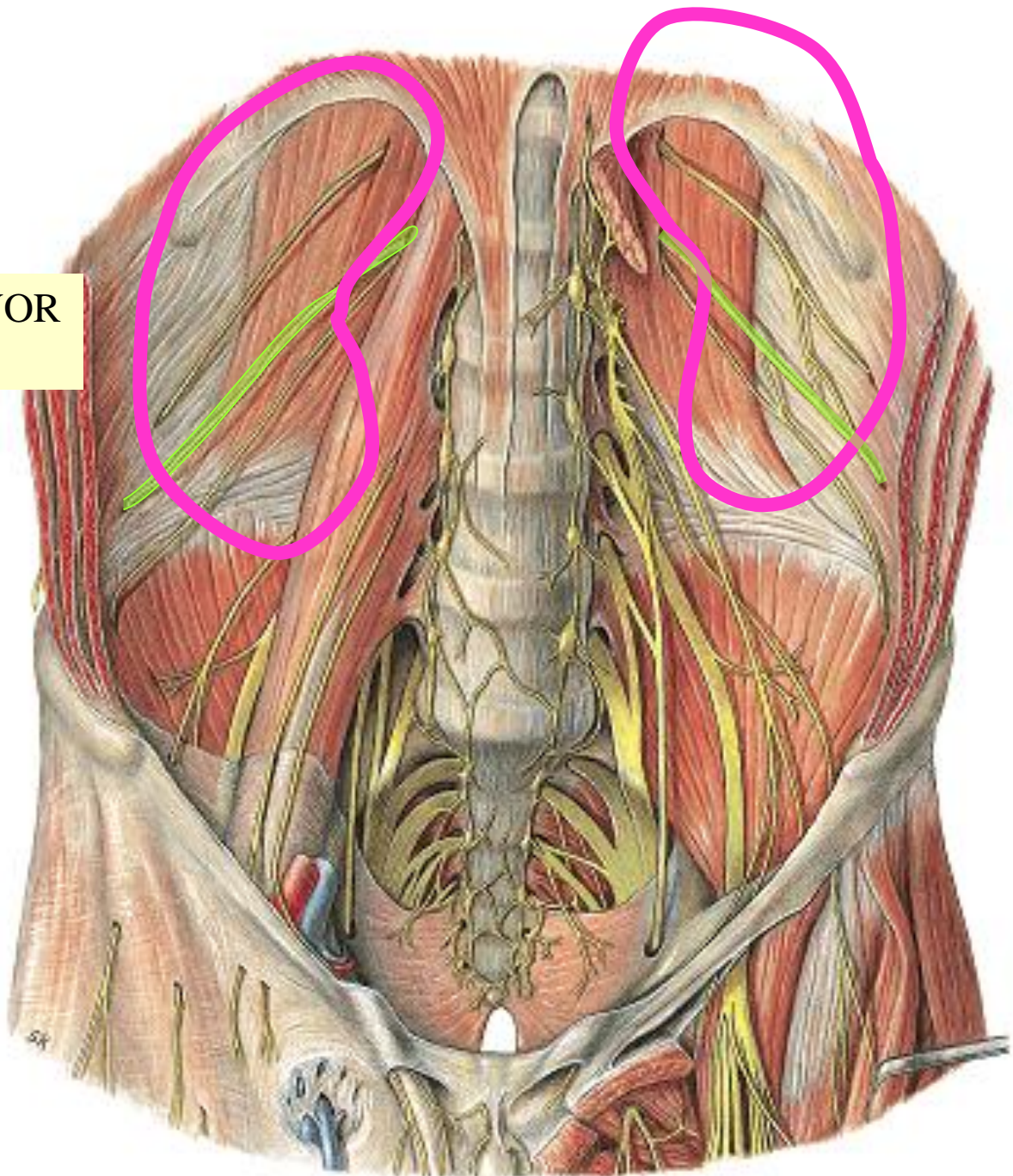
XII INTERCOSTAL
N. SUBCOSTALIS

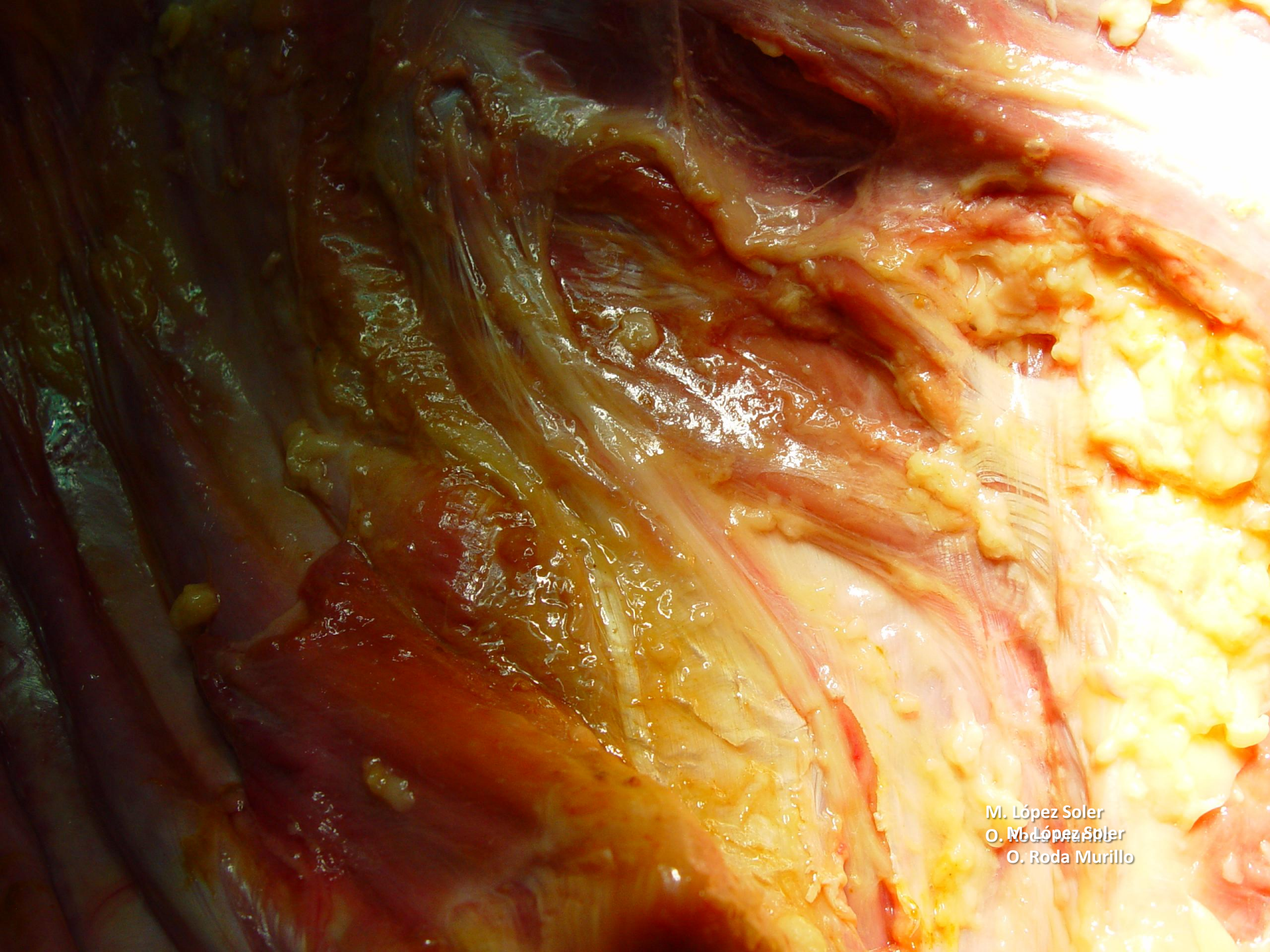


M. López Soler
O. Roda Murillo



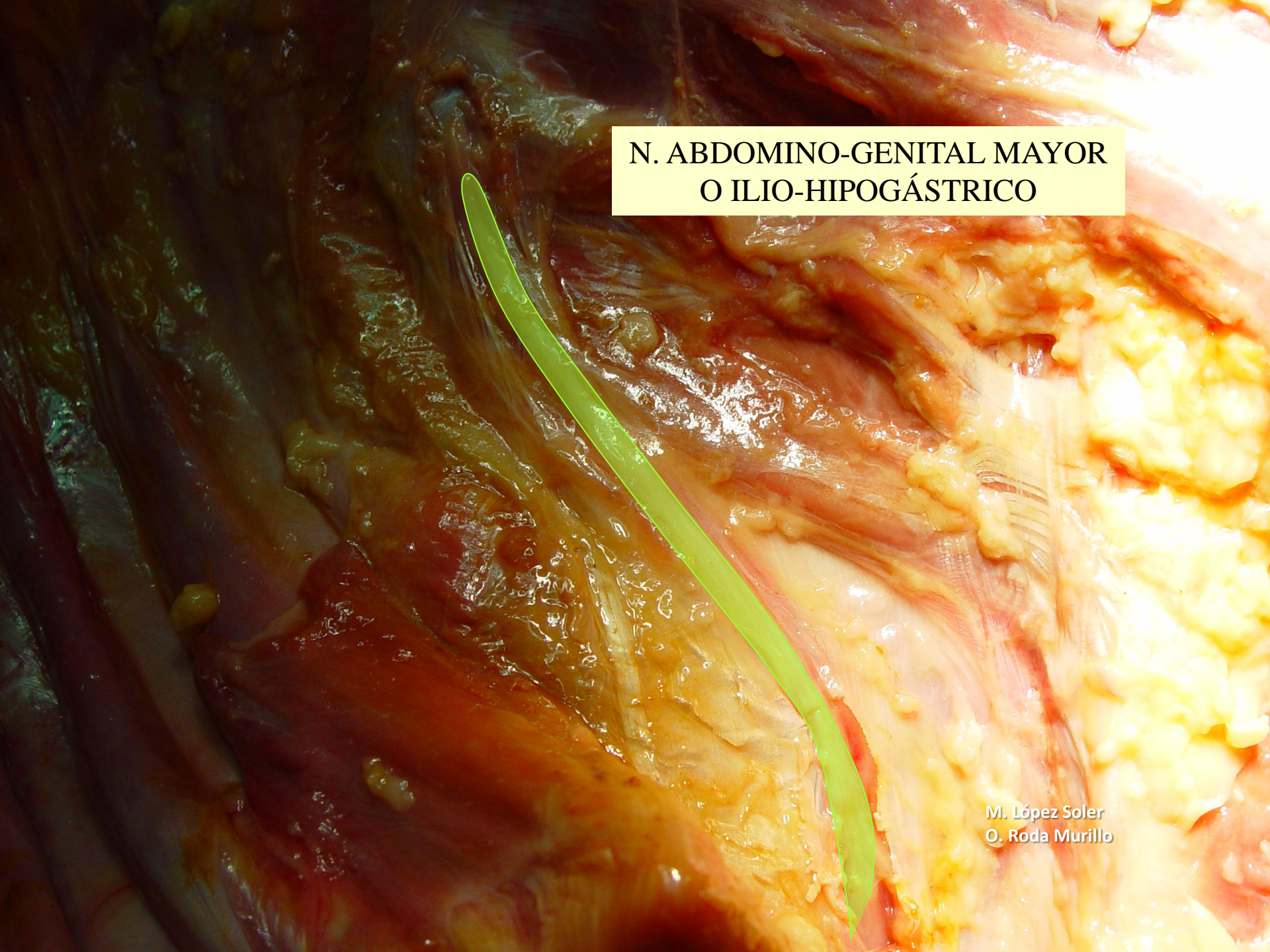
N. ABDOMINO-GENITAL MAYOR
O ILIO-HIPOGÁSTRICO



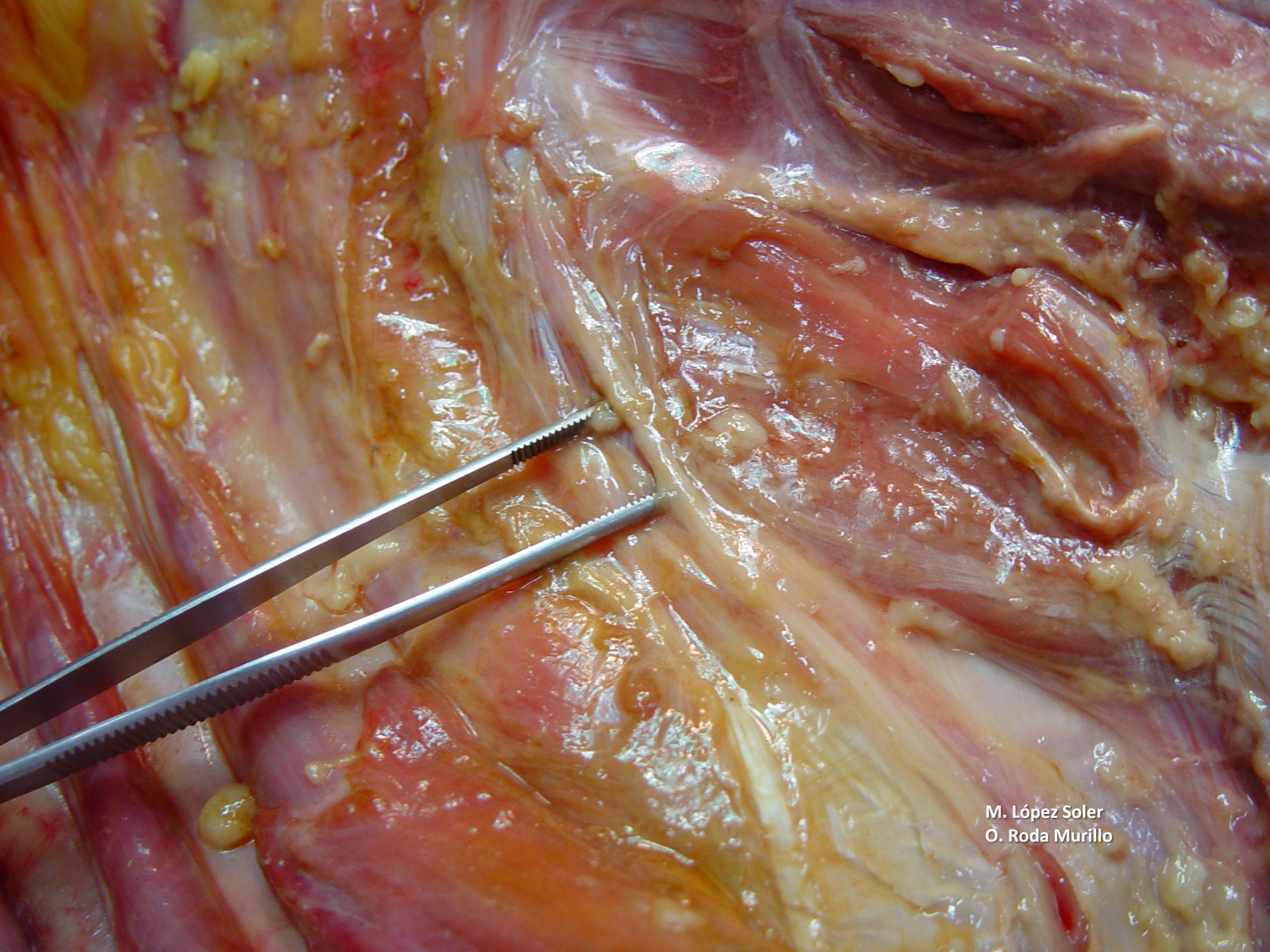


M. López Soler
O. Rodríguez Soler
O. Roda Murillo

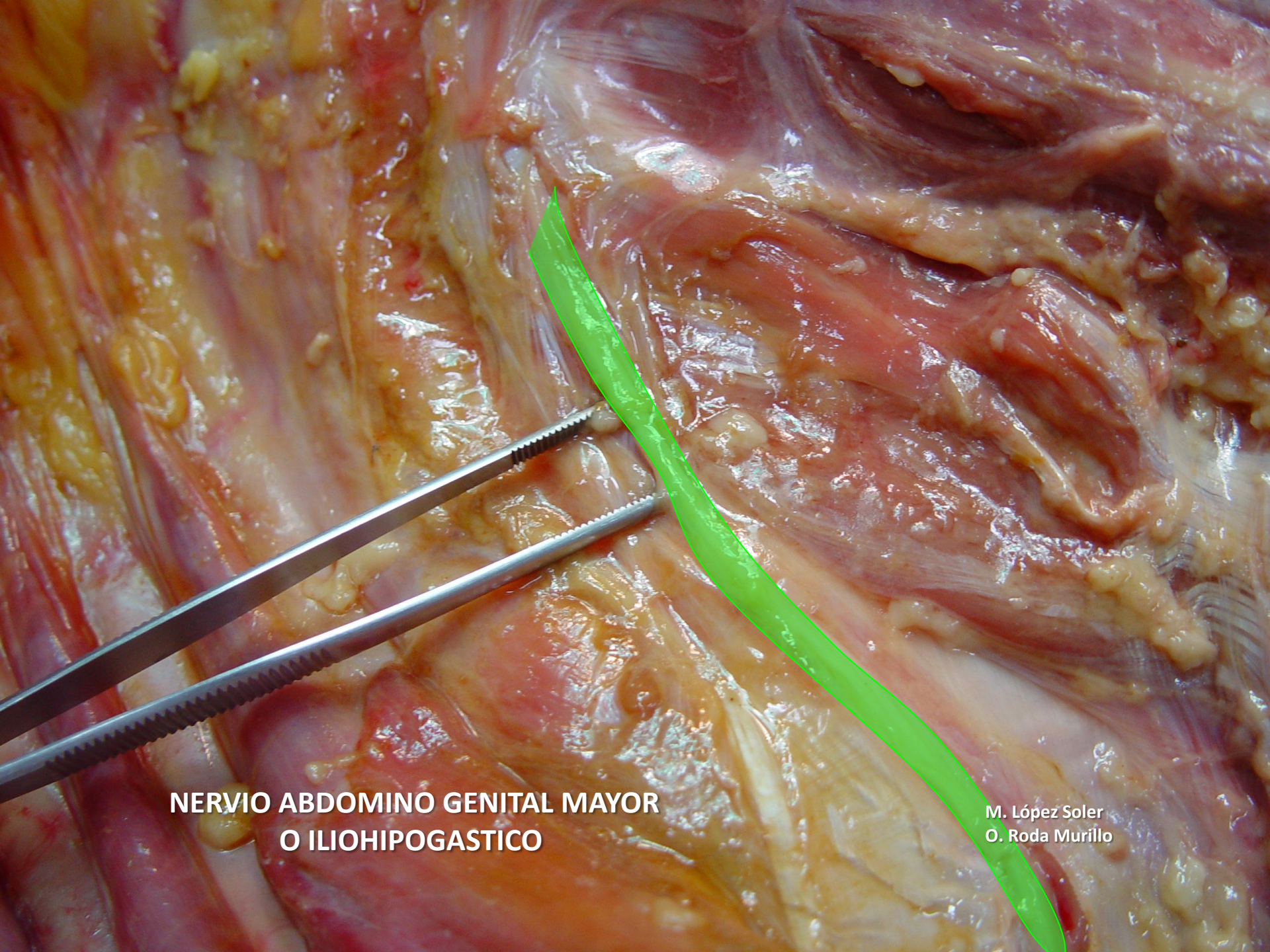
**N. ABDOMINO-GENITAL MAYOR
O ILIO-HIPOGÁSTRICO**



M. López Soler
O. Roda Murillo

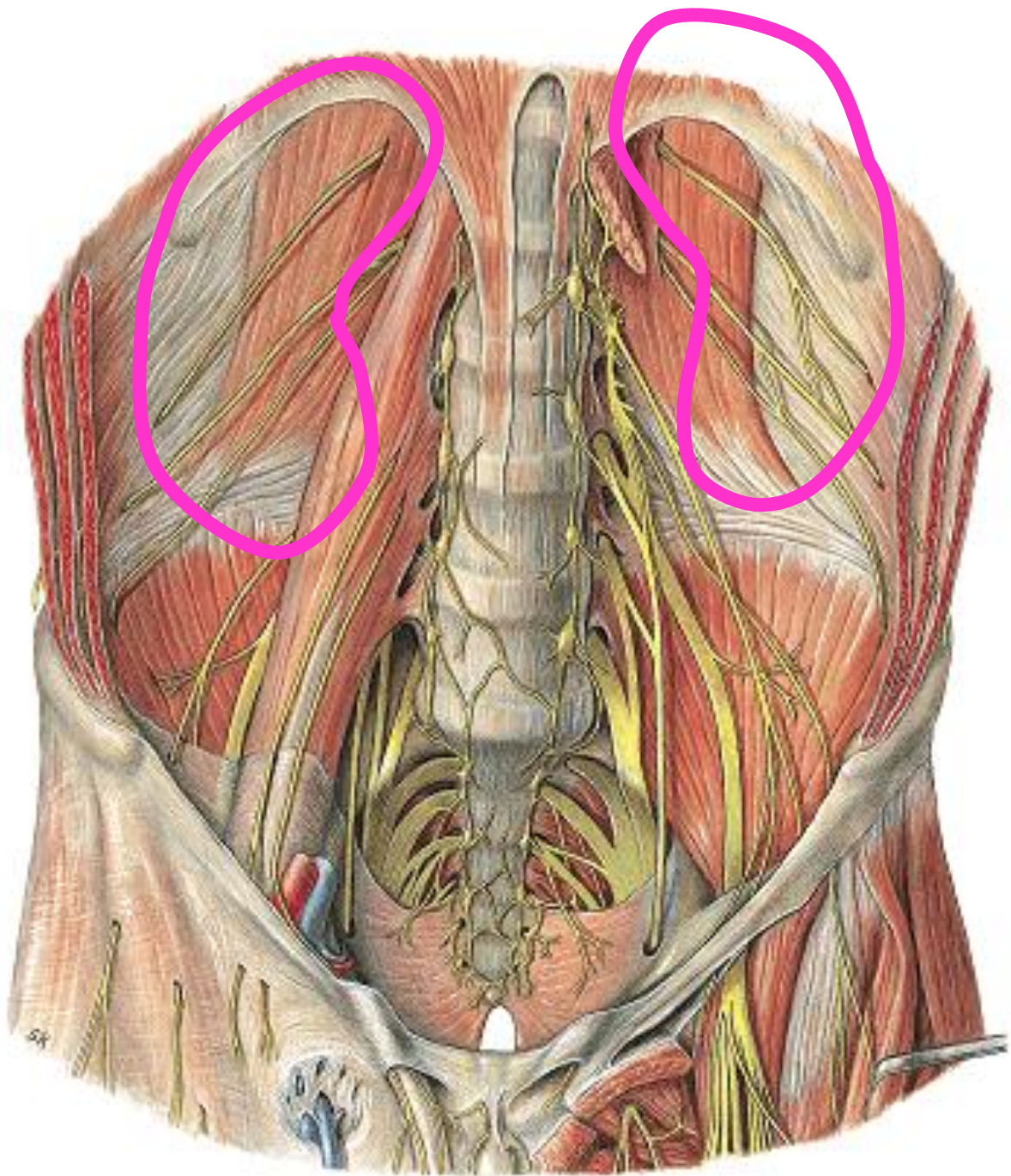


M. López Soler
Ó. Roda Murillo

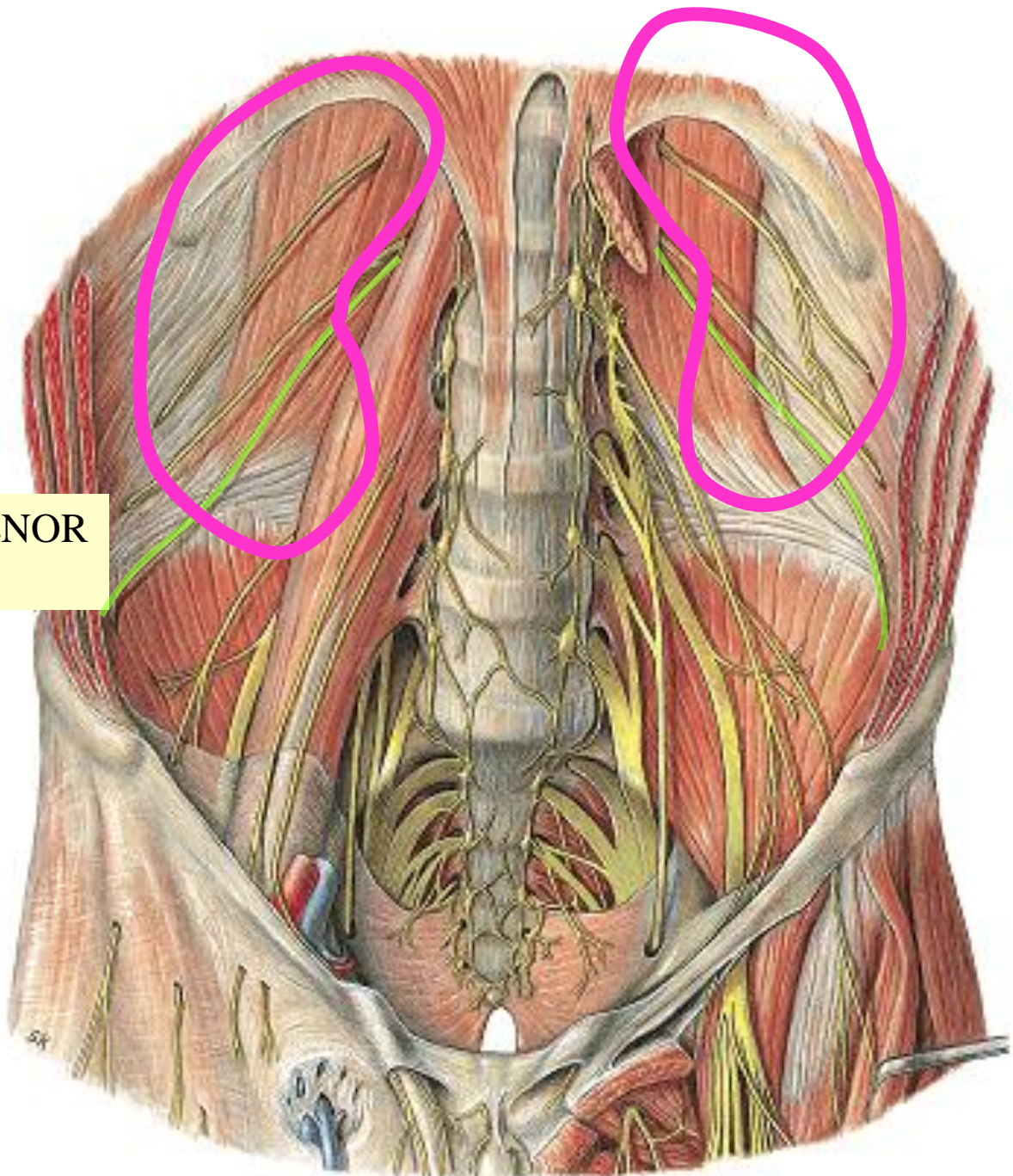


**NERVIO ABDOMINO GENITAL MAYOR
O ILIOHIPOGASTICO**

M. López Soler
O. Roda Murillo



N. ABDOMINO-GENITAL MENOR
O ILIO-INGUIAL

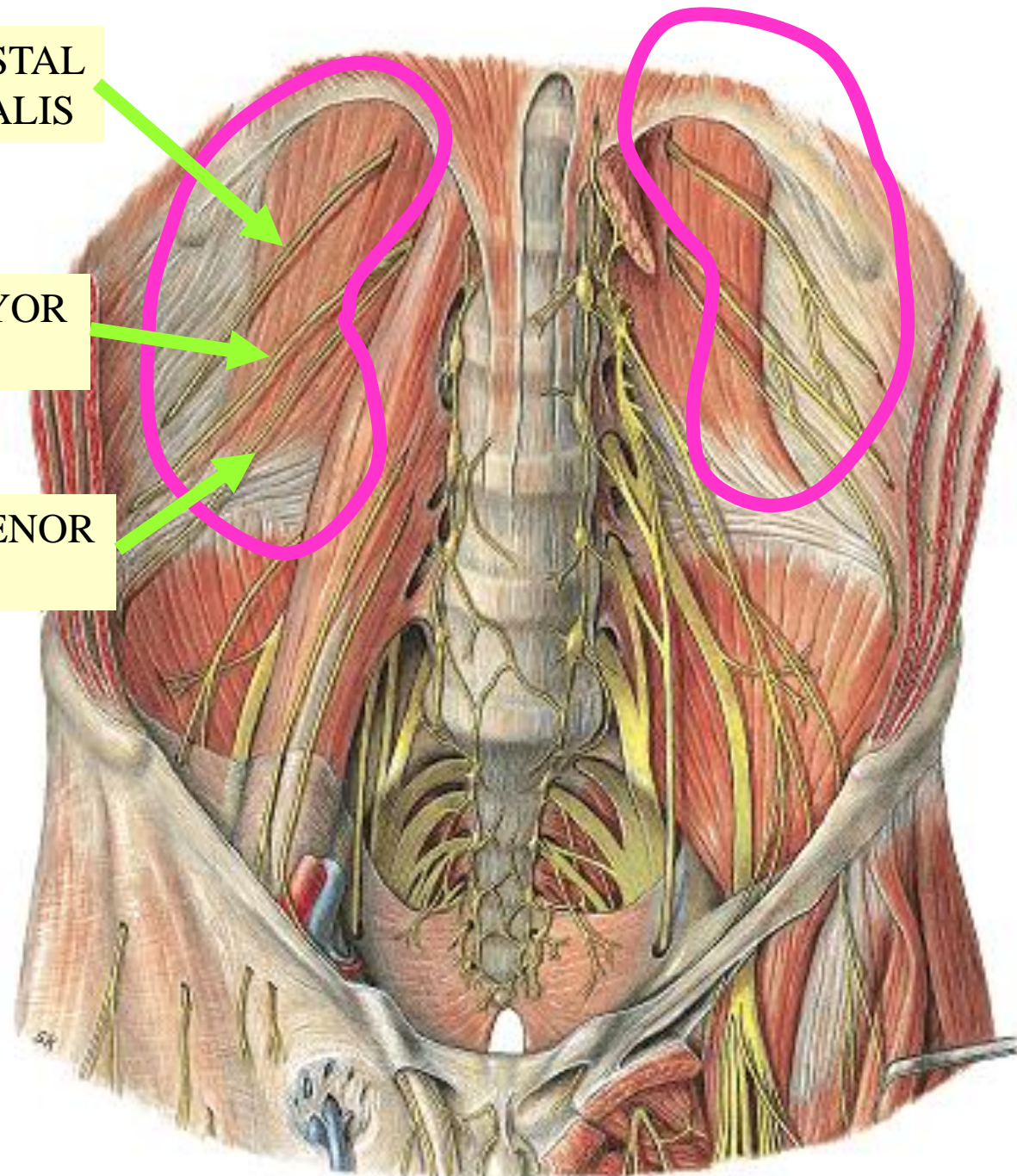


XII INTERCOSTAL
N. SUBCOSTALIS

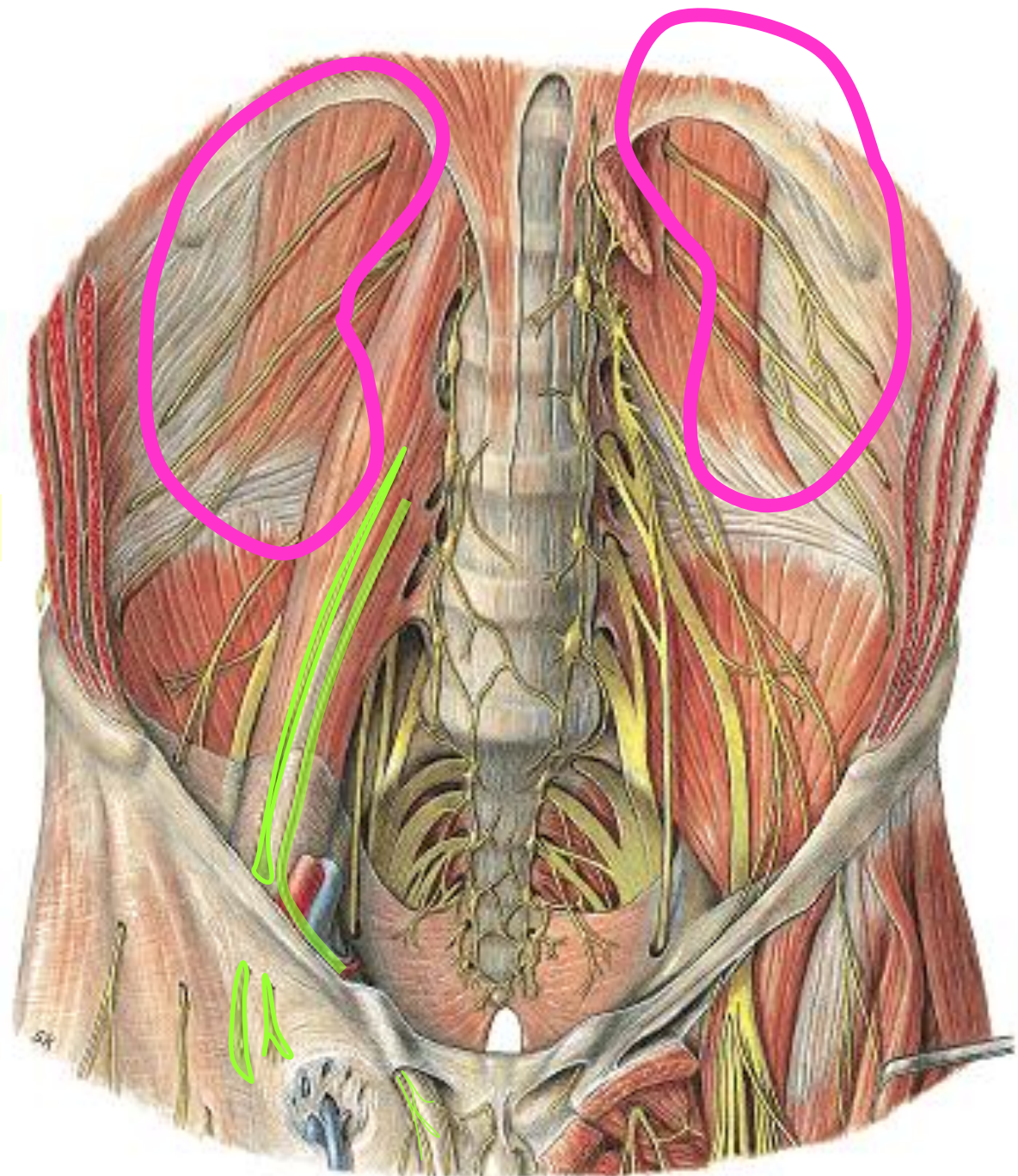
N. ABDOMINO-GENITAL MAYOR
O ILIO-HIPOGÁSTRICO

N. ABDOMINO-GENITAL MENOR
O ILIO-INGUIAL

**RELACIONES
DE LOS RIÑONES**

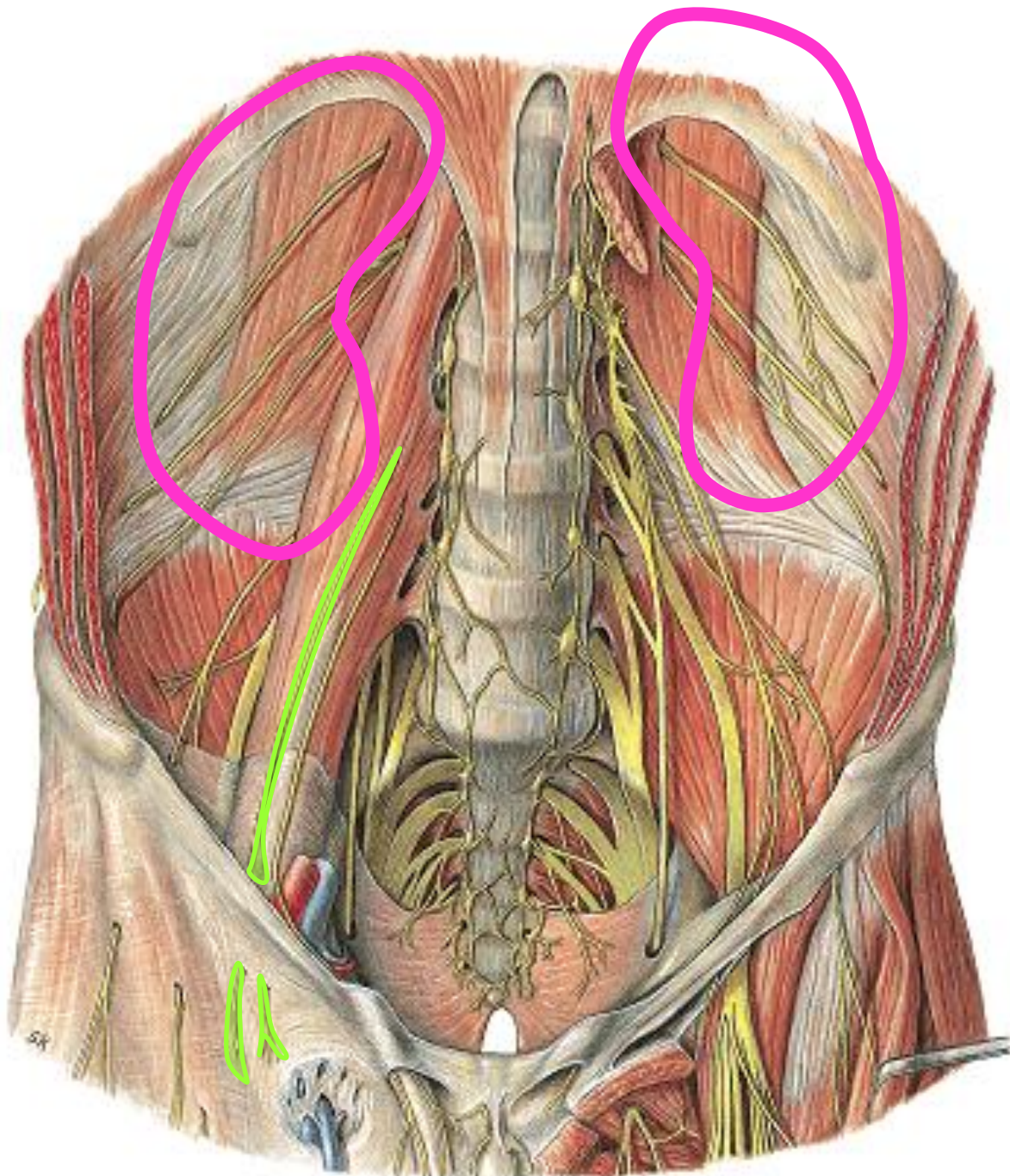


N. GENITOFEMORAL



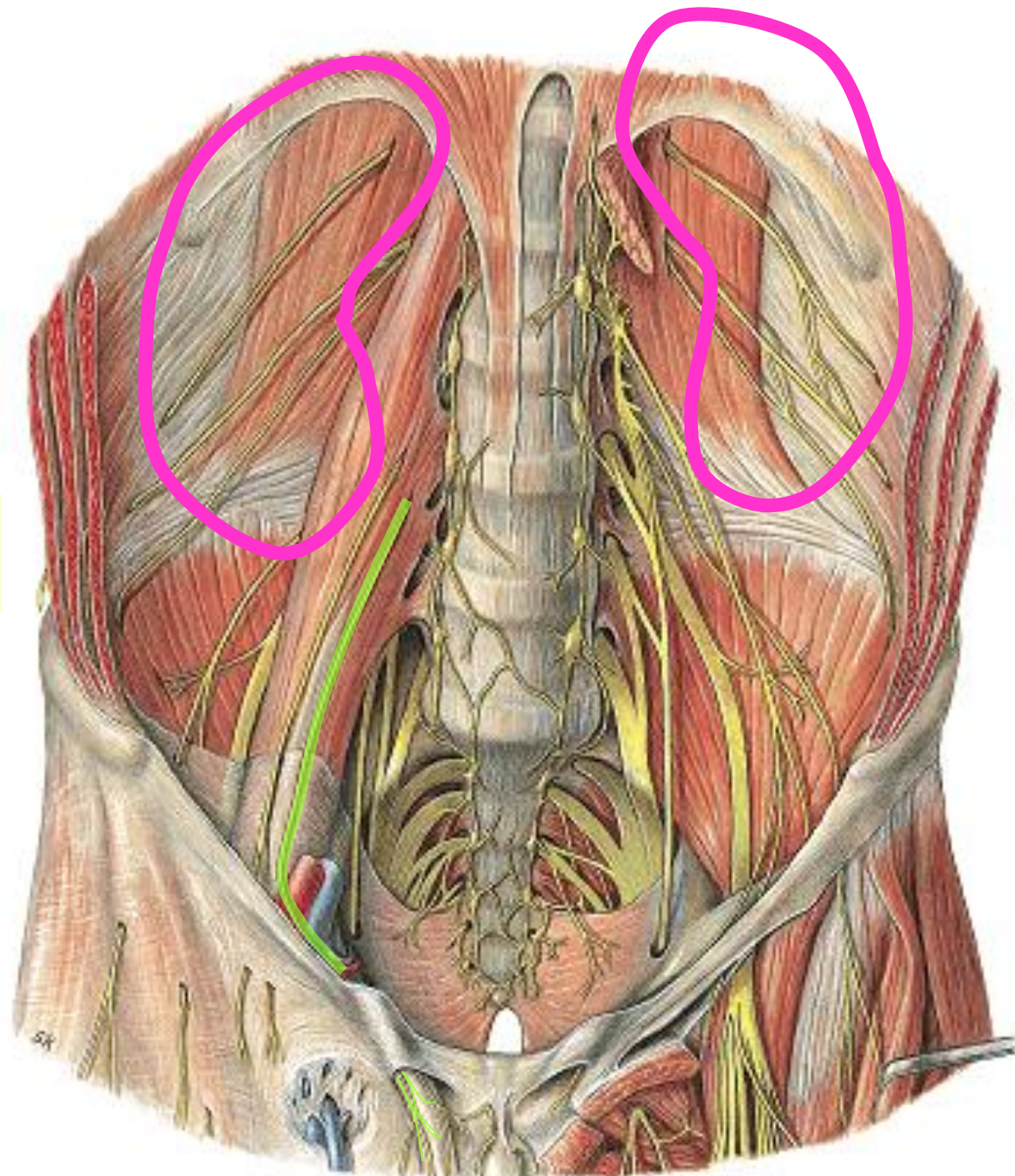
**N. GENITOFEMORAL
(RAMO FEMORAL)**

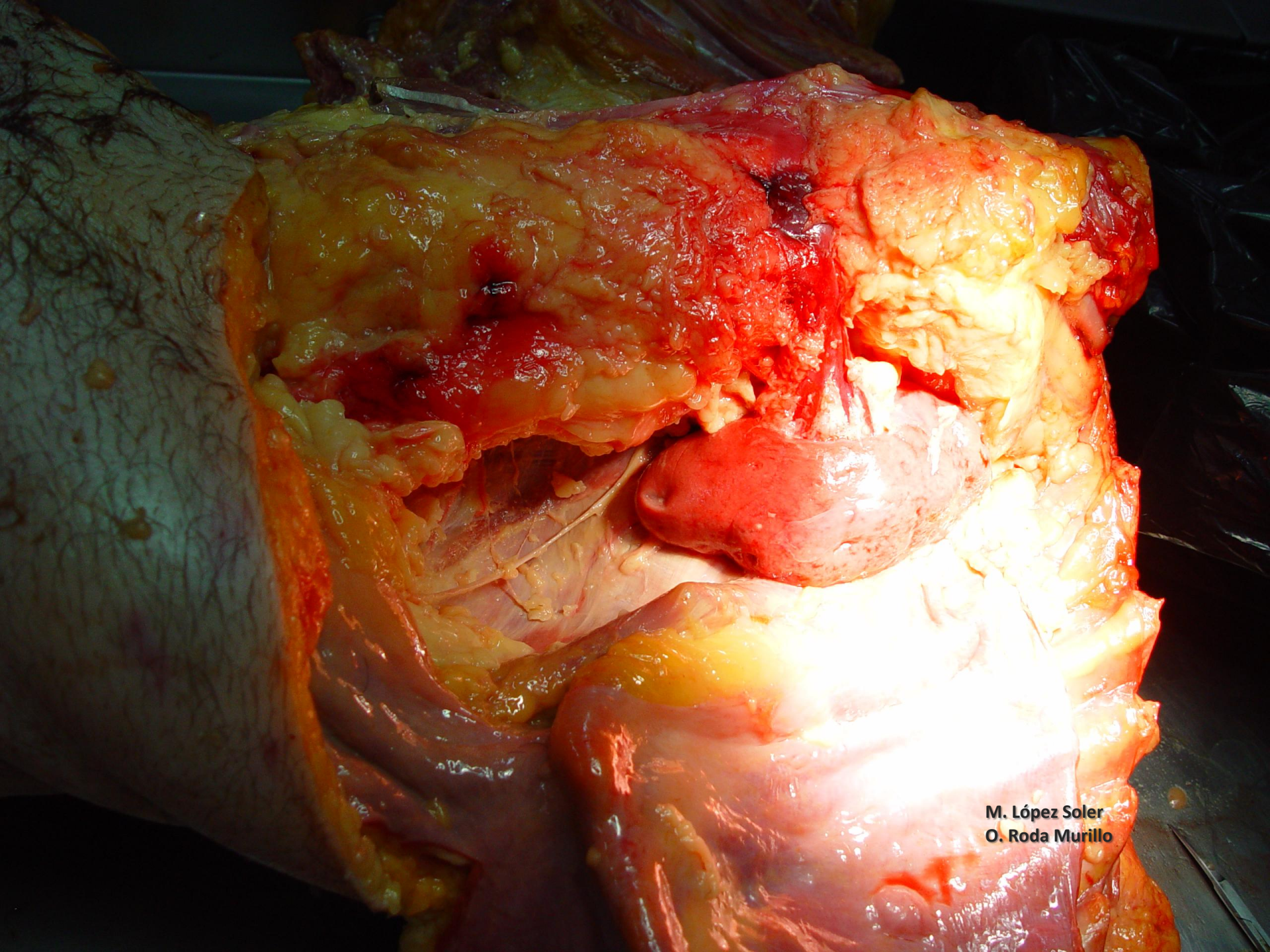
**RELACIONES
DE LOS RIÑONES**



**N. GENITOFEMORAL
(RAMO GENITAL)**

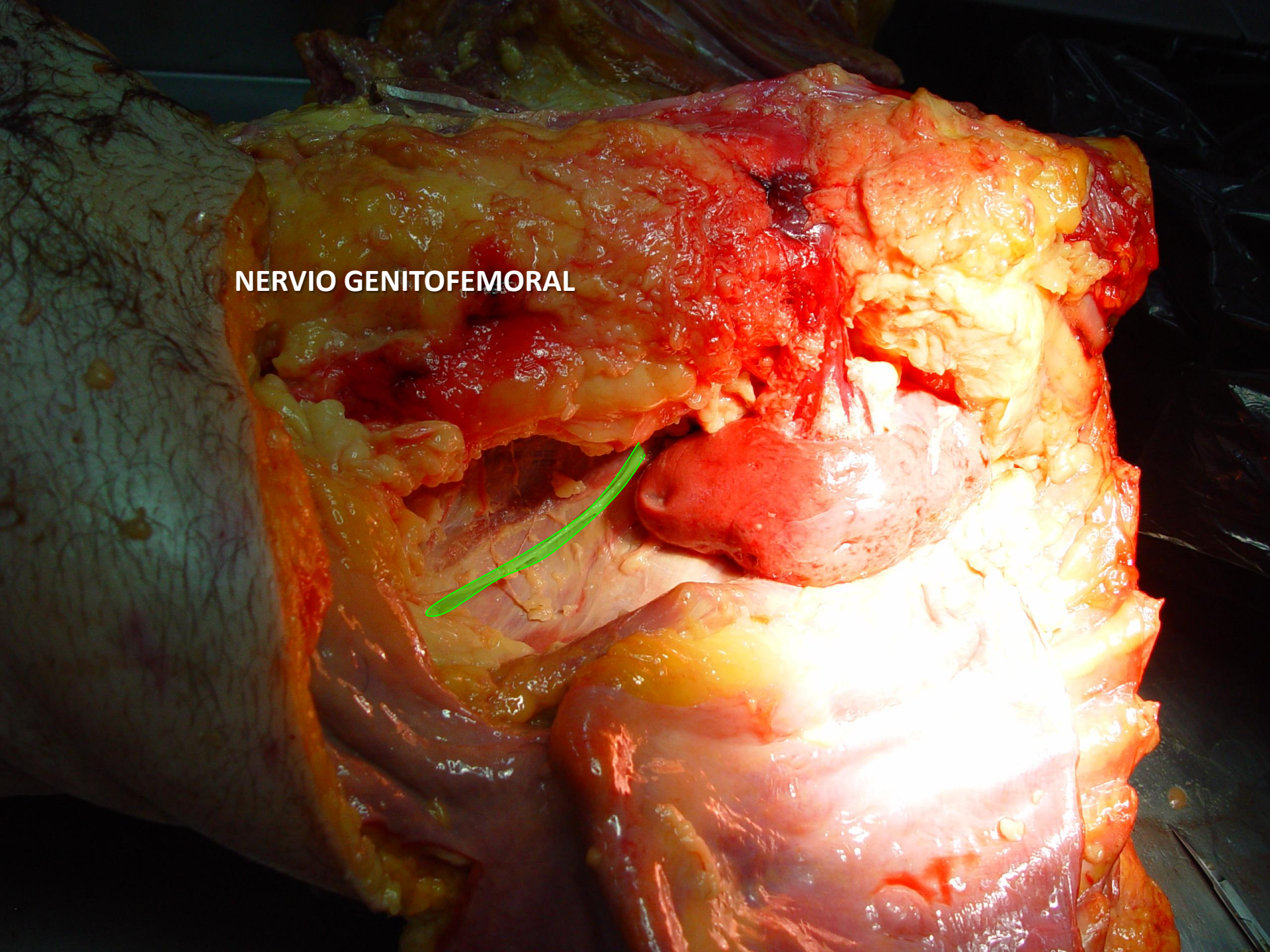
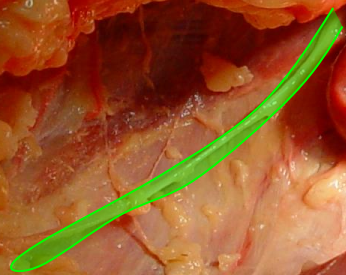
**RELACIONES
DE LOS RIÑONES**

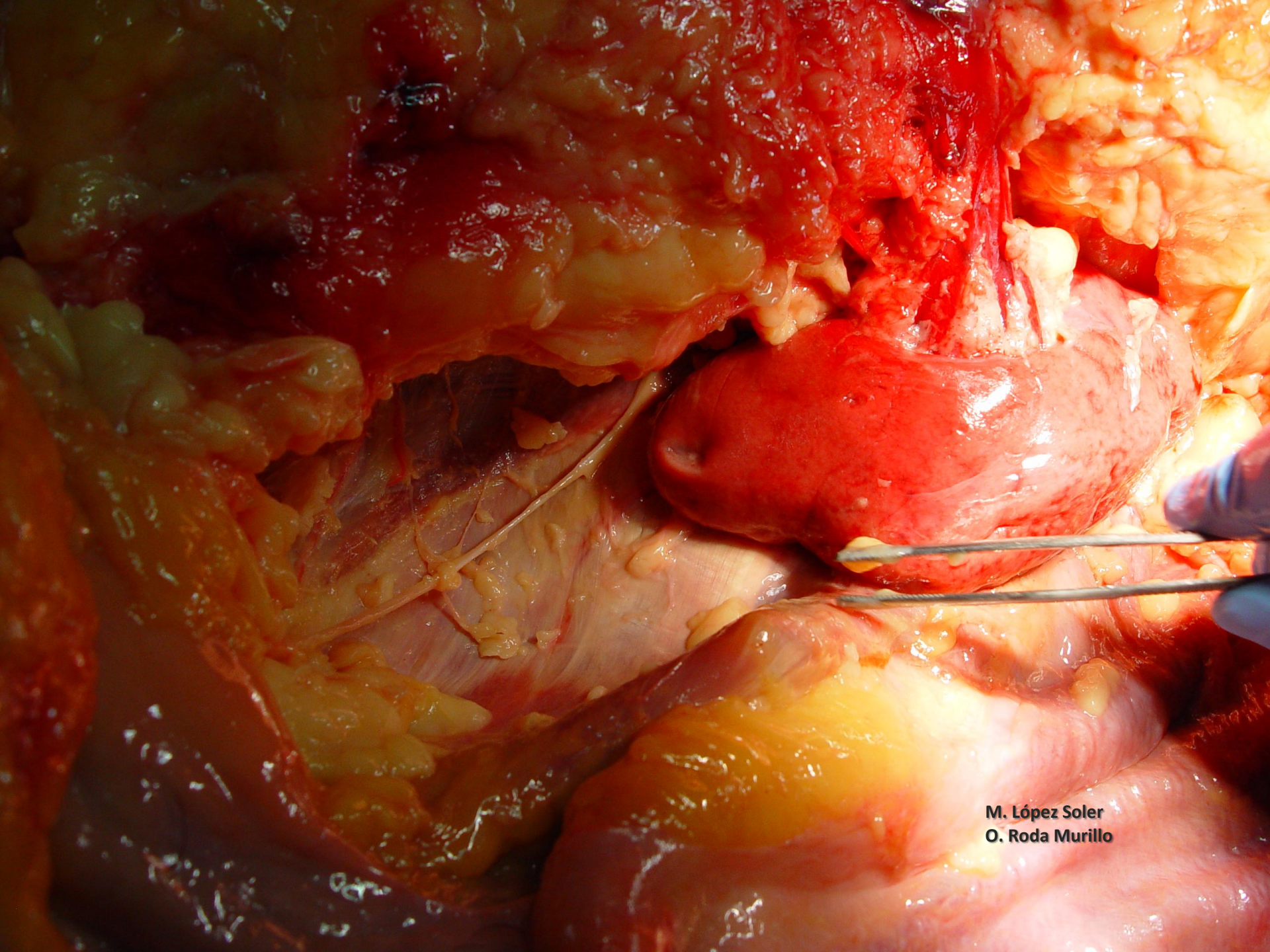




M. López Soler
O. Roda Murillo

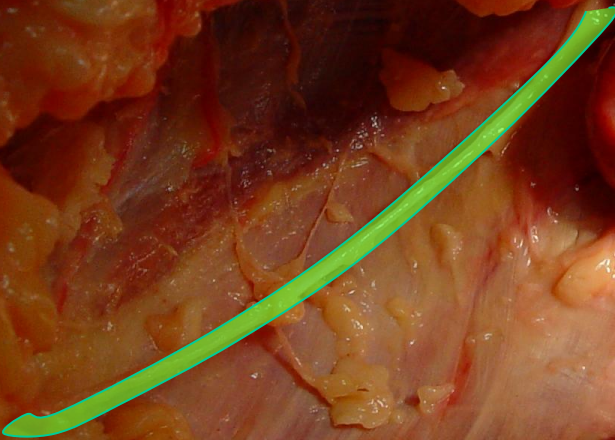
NERVIO GENITOFEMORAL



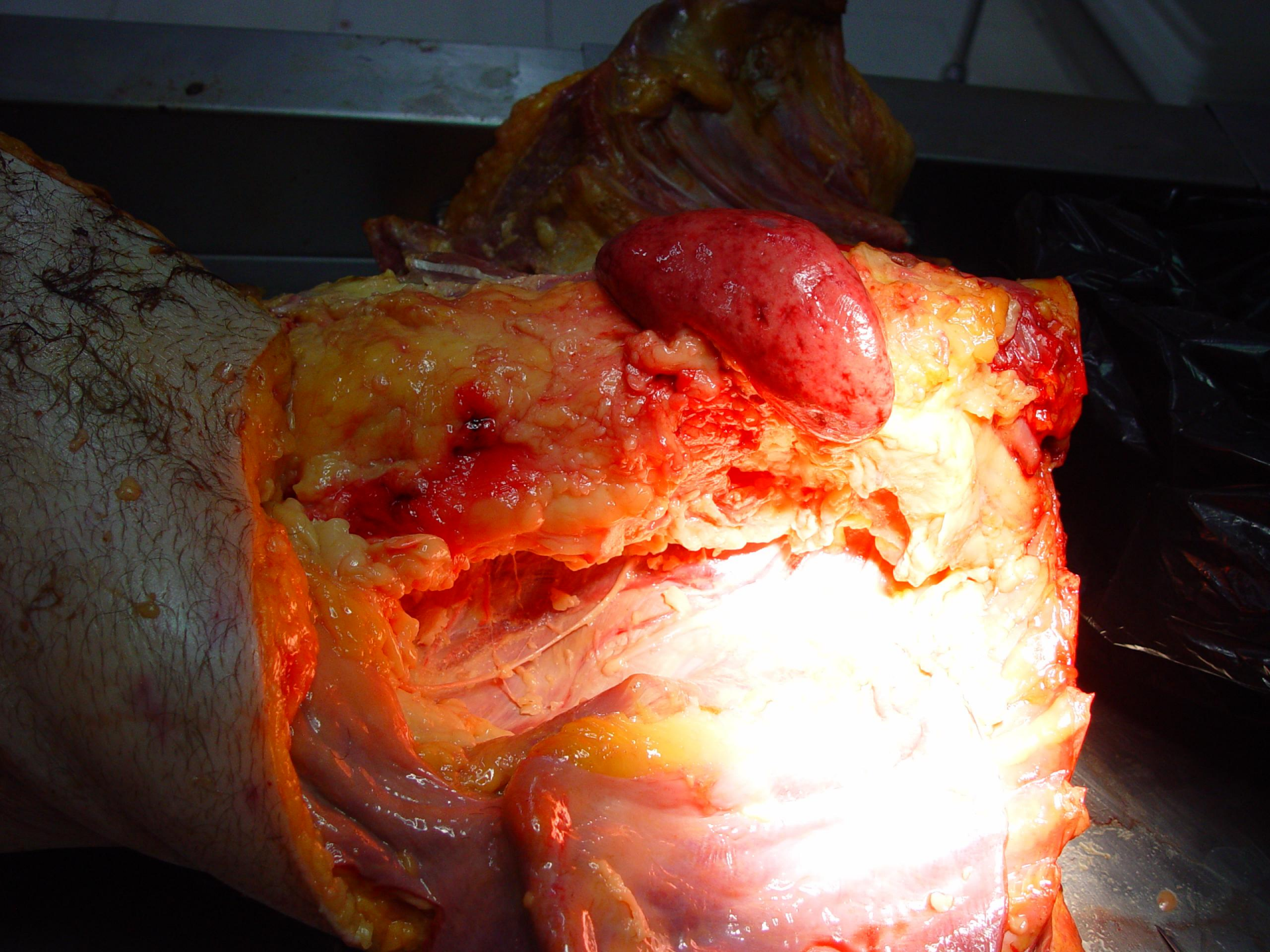


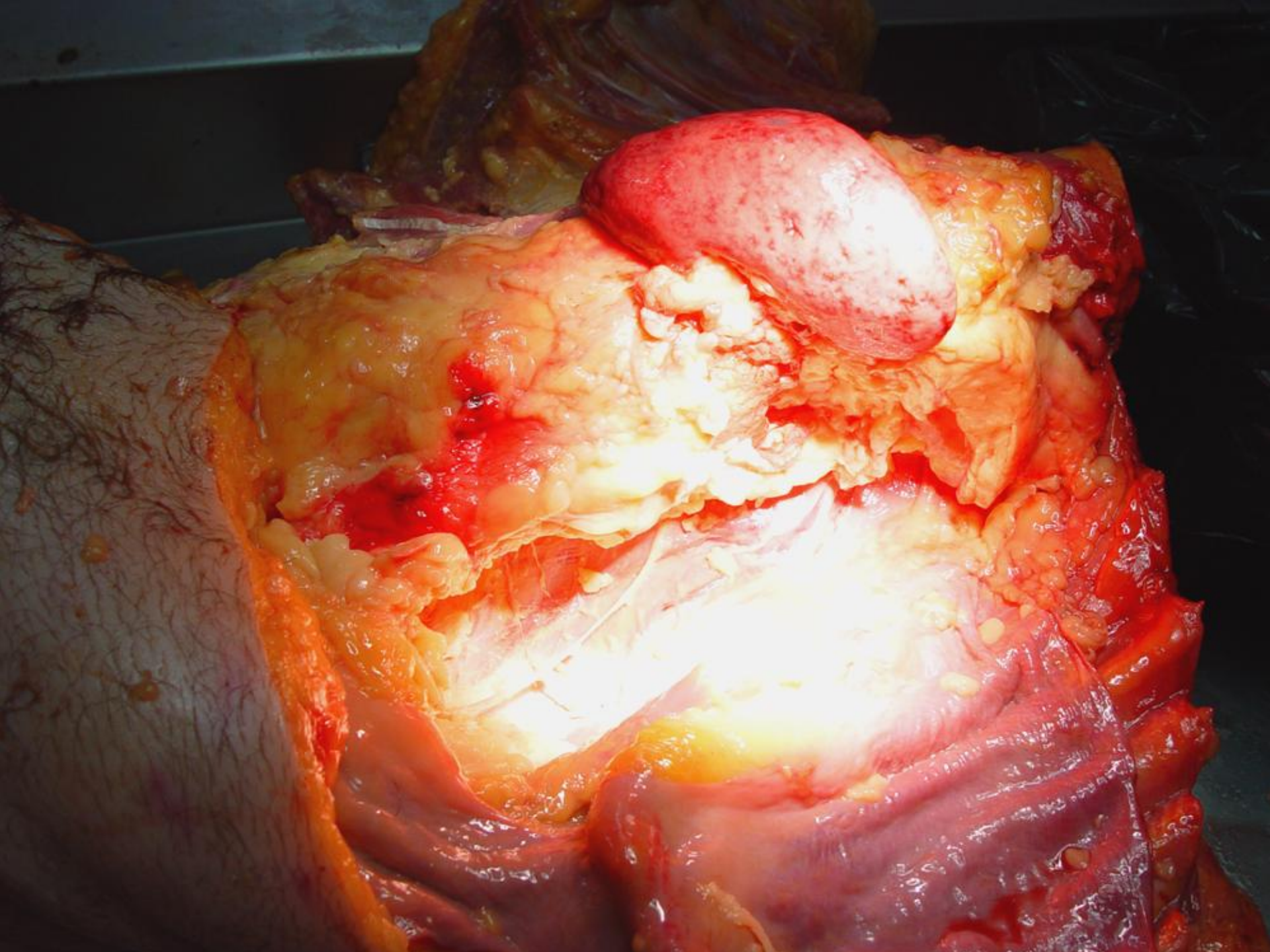
M. López Soler
O. Roda Murillo

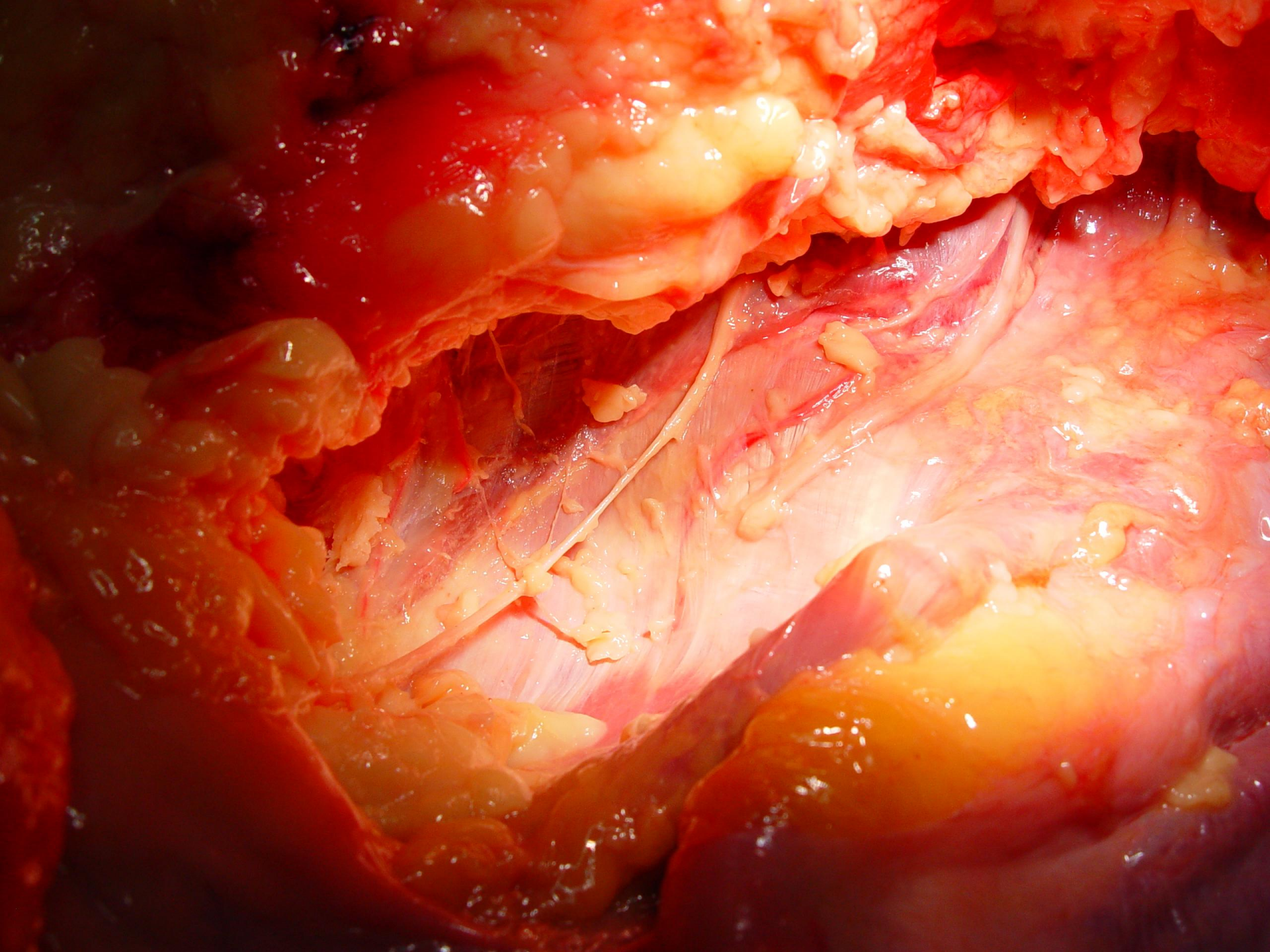
NERVIO GENITOFEMORAL



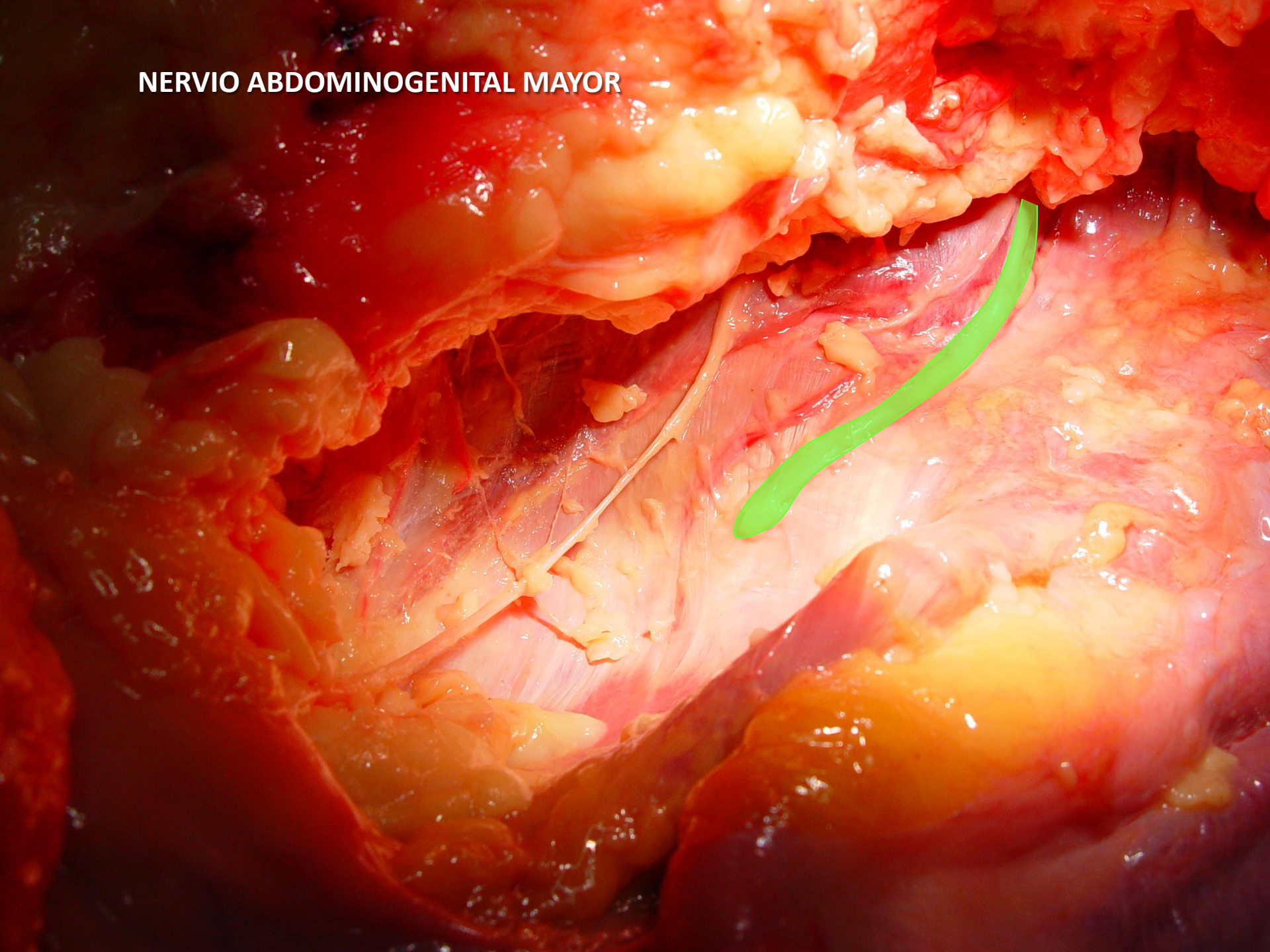
**M. López Soler
O. Roda Murillo**

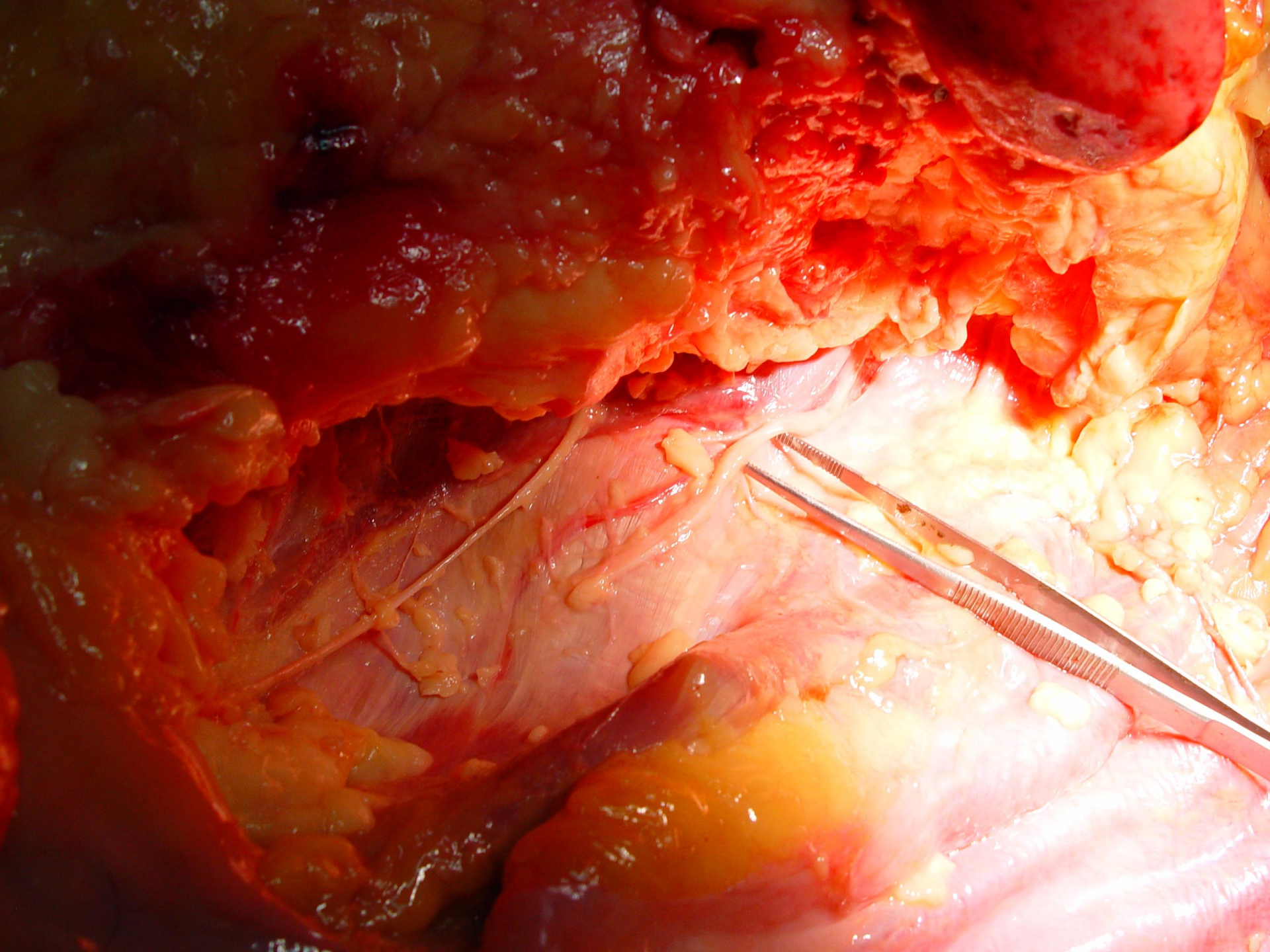




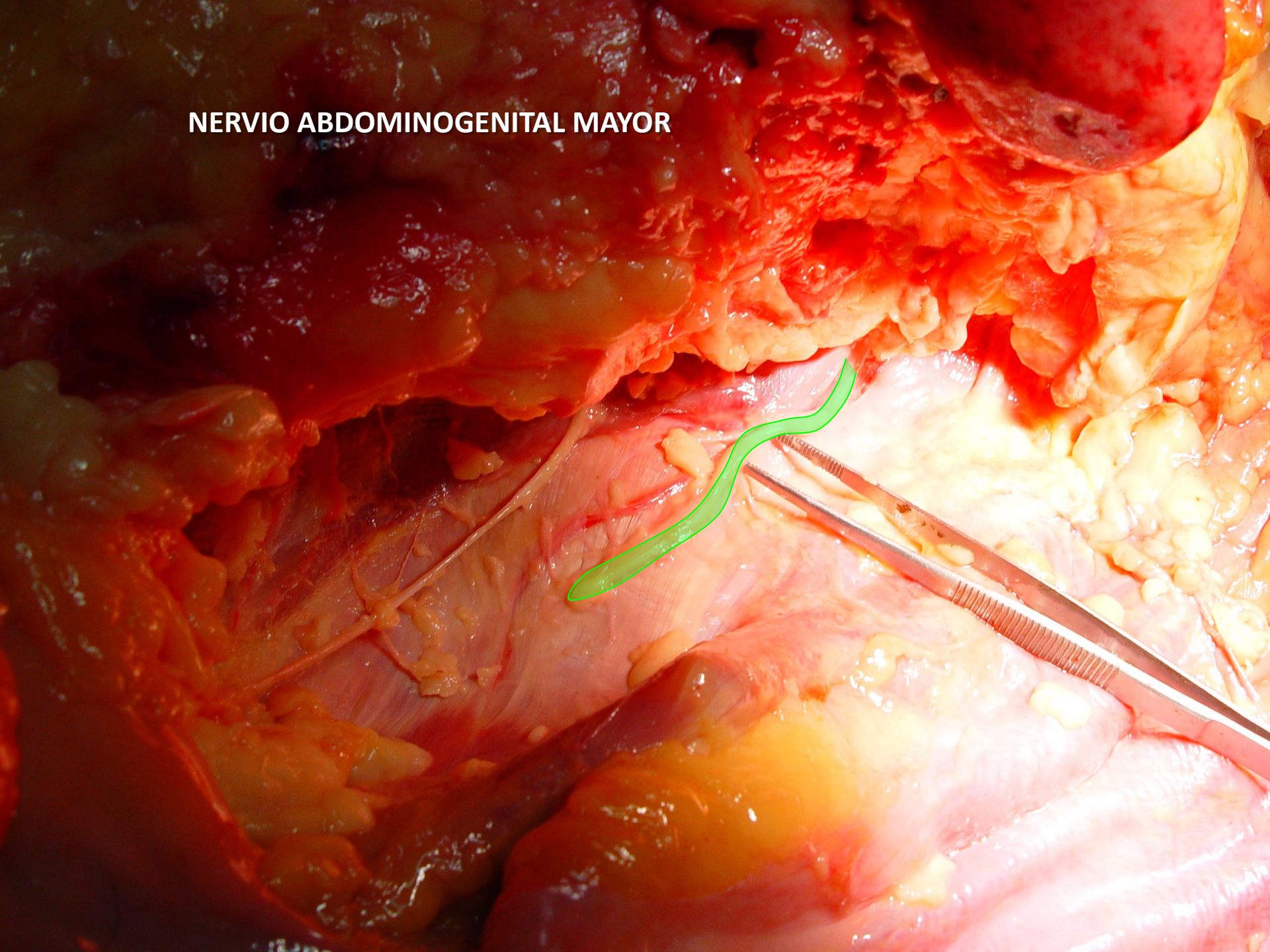


NERVIO ABDOMINOGENITAL MAYOR

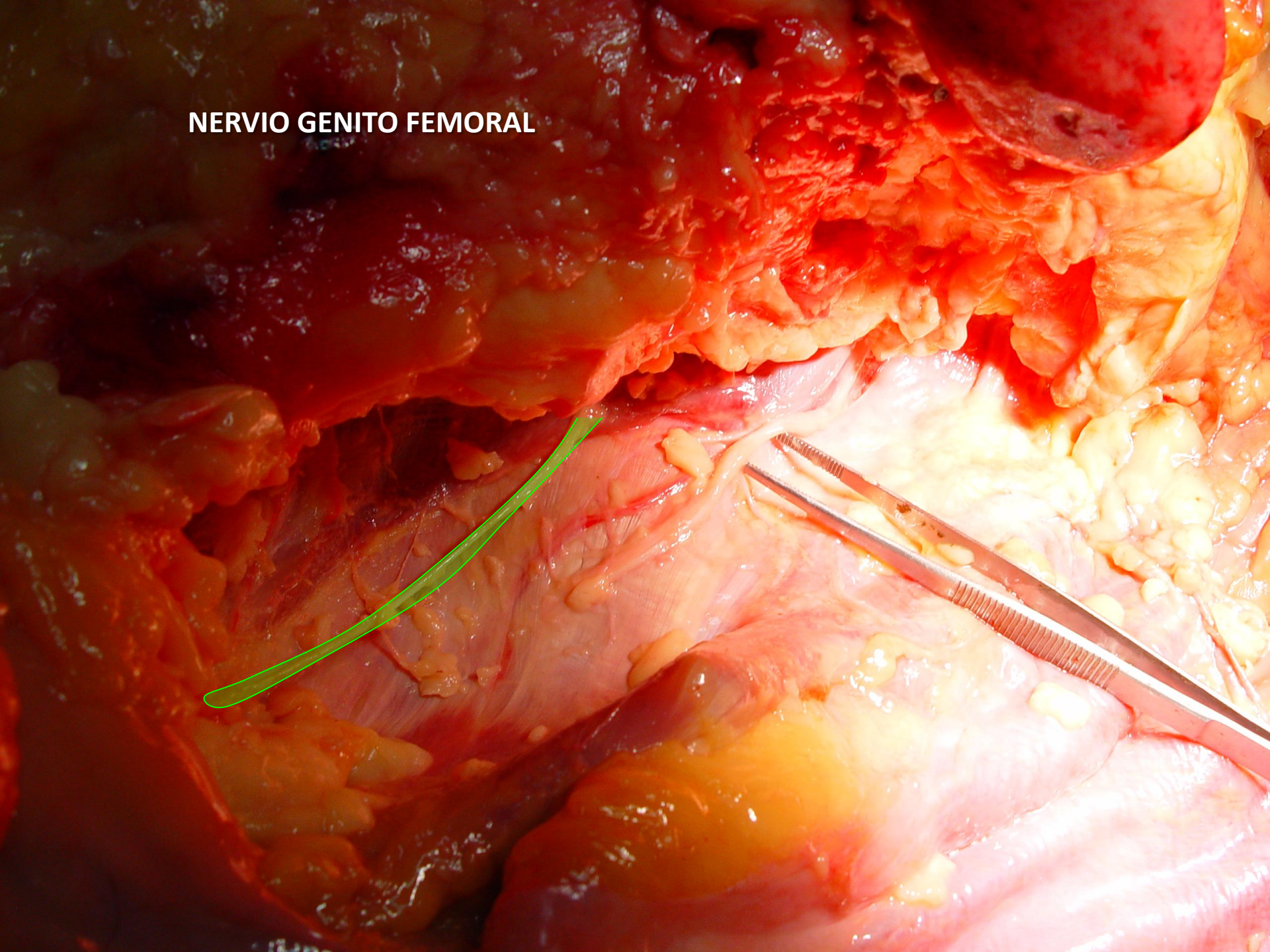


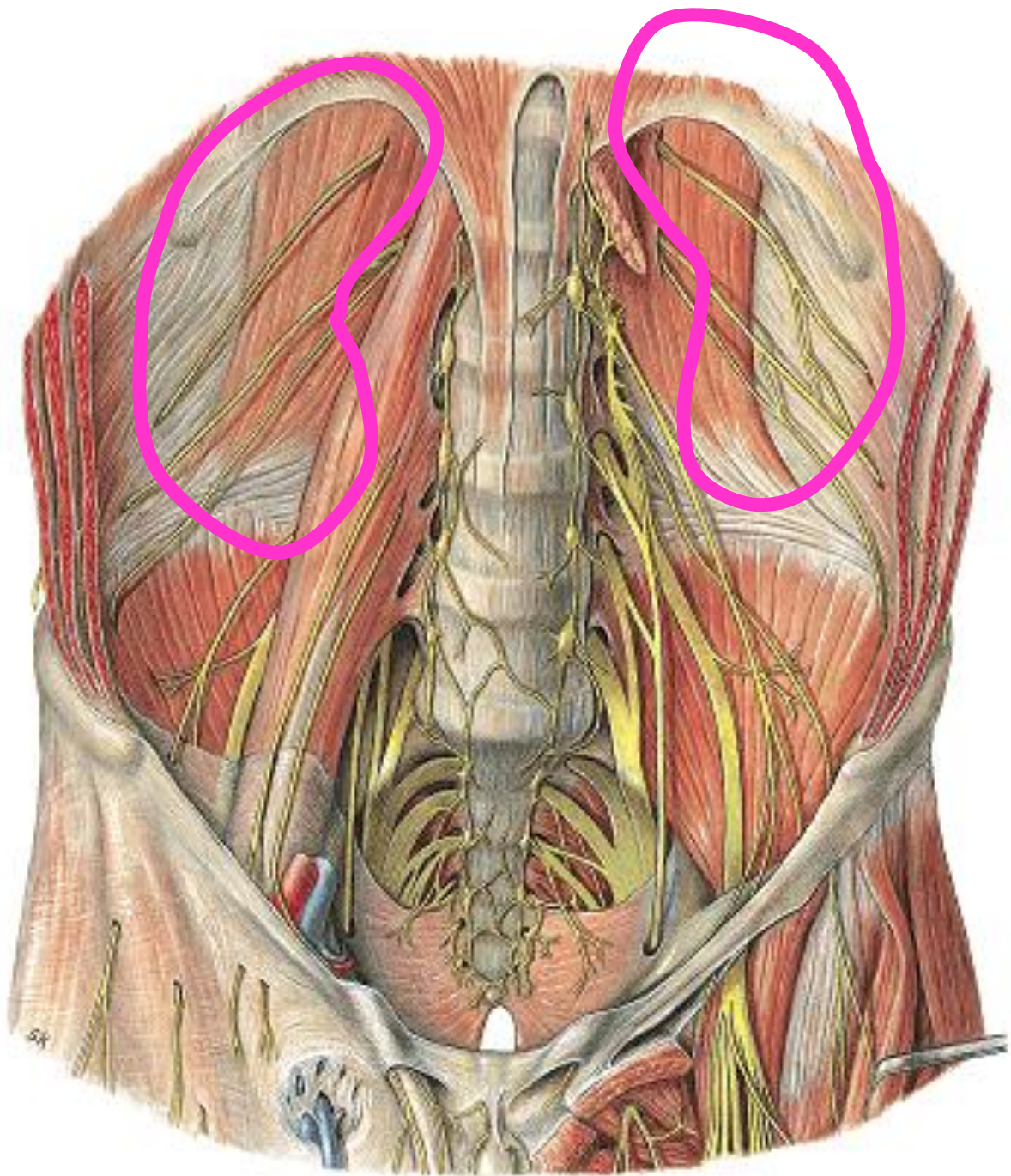


NERVIO ABDOMINOGENITAL MAYOR

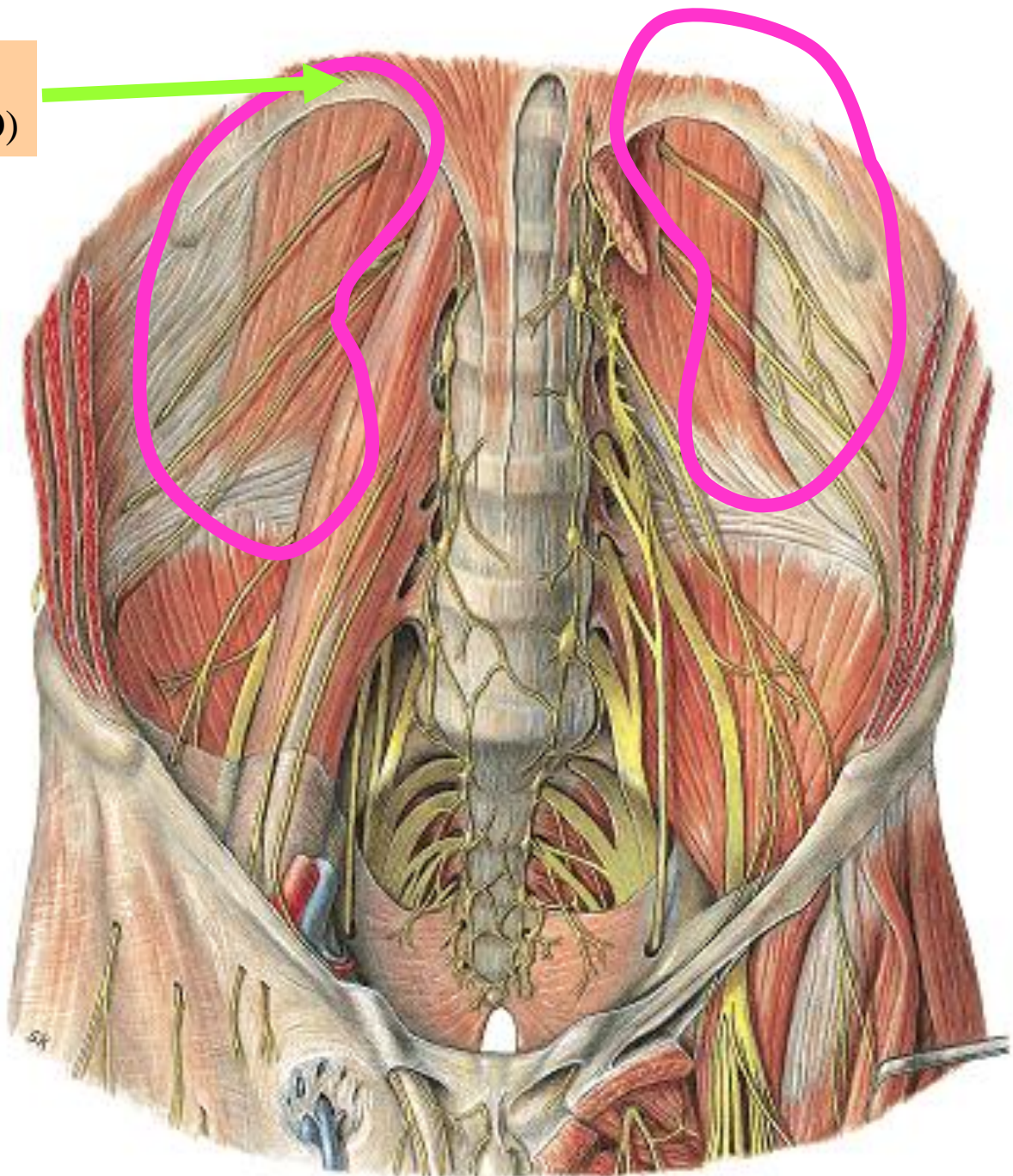


NERVIO GENITO FEMORAL

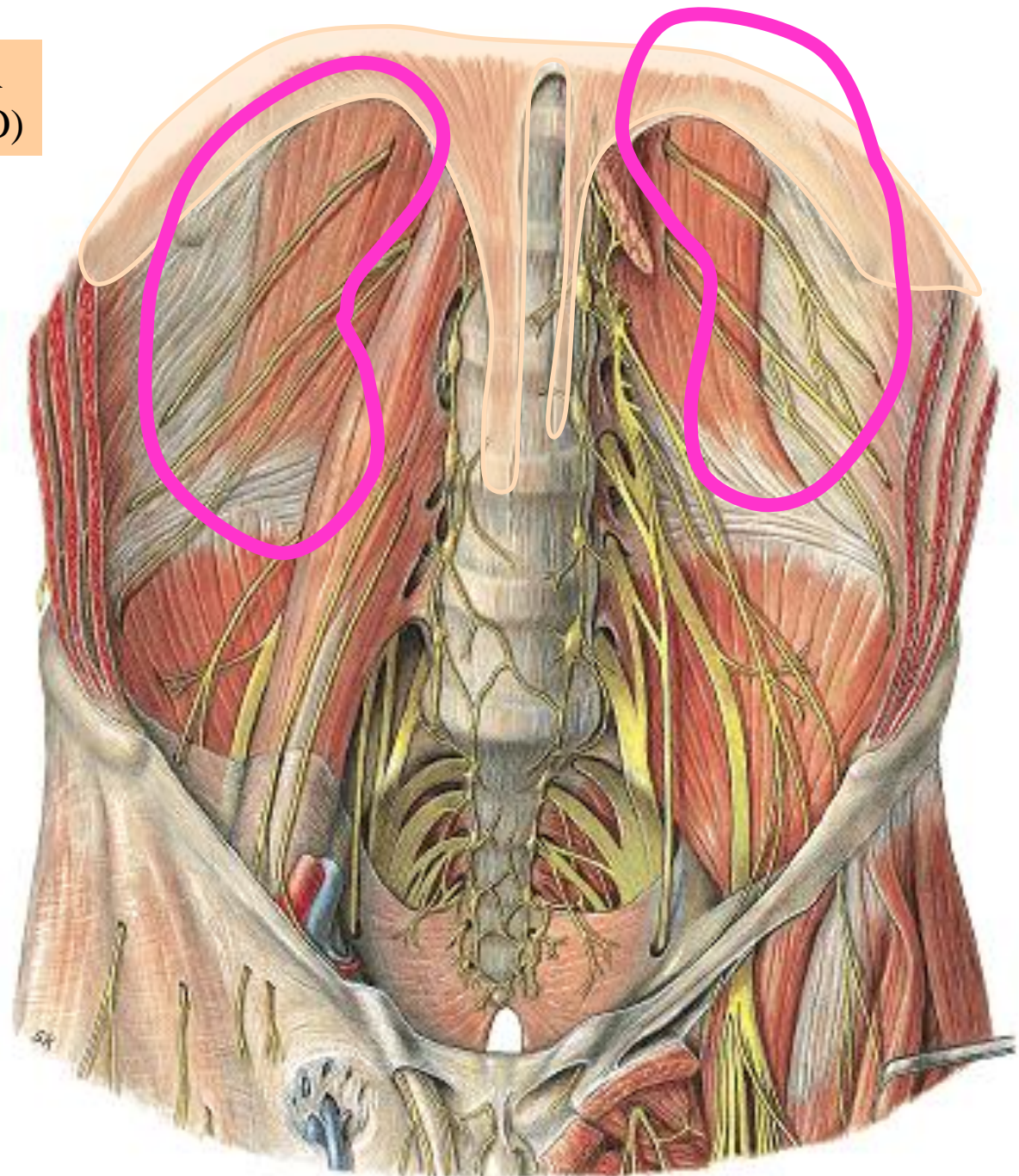




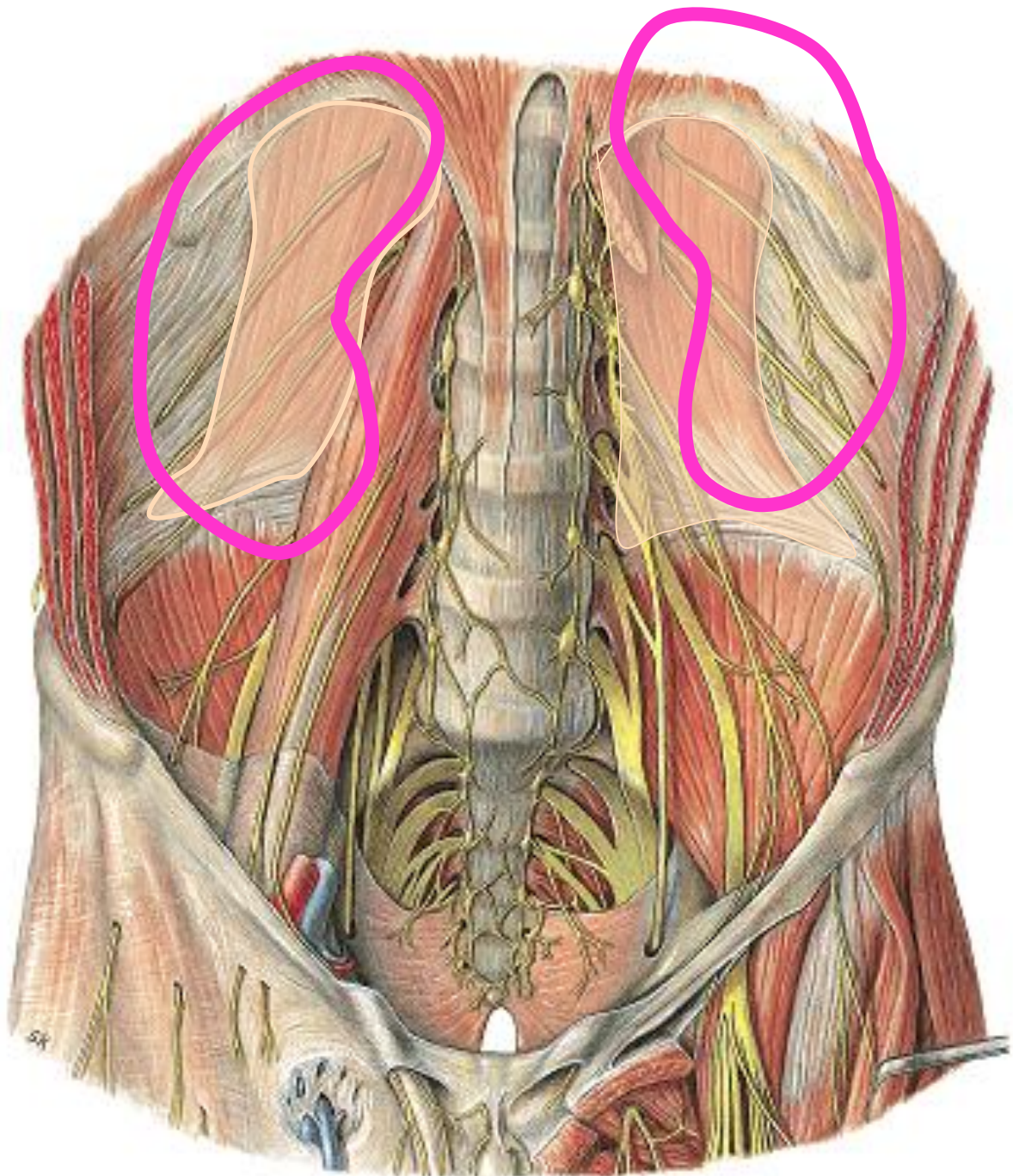
MÚSCULO DIAFRAGMA
(LIGAMENTO CIMBRADO)



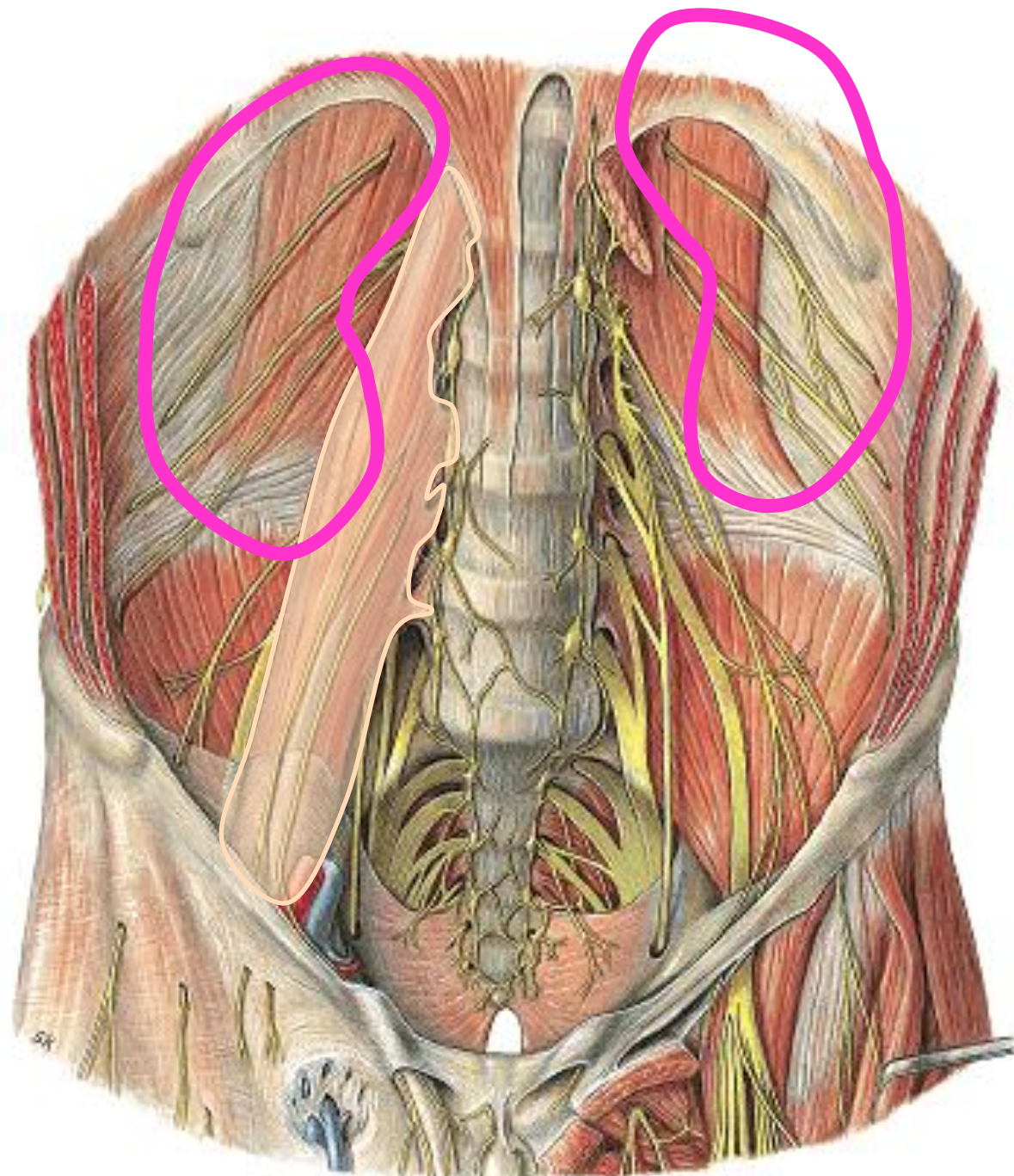
MÚSCULO DIAFRAGMA
(LIGAMENTO CIMBRADO)



MÚSCULO CUADRADO
DE LOS LOMOS



MÚSCULO PSOAS

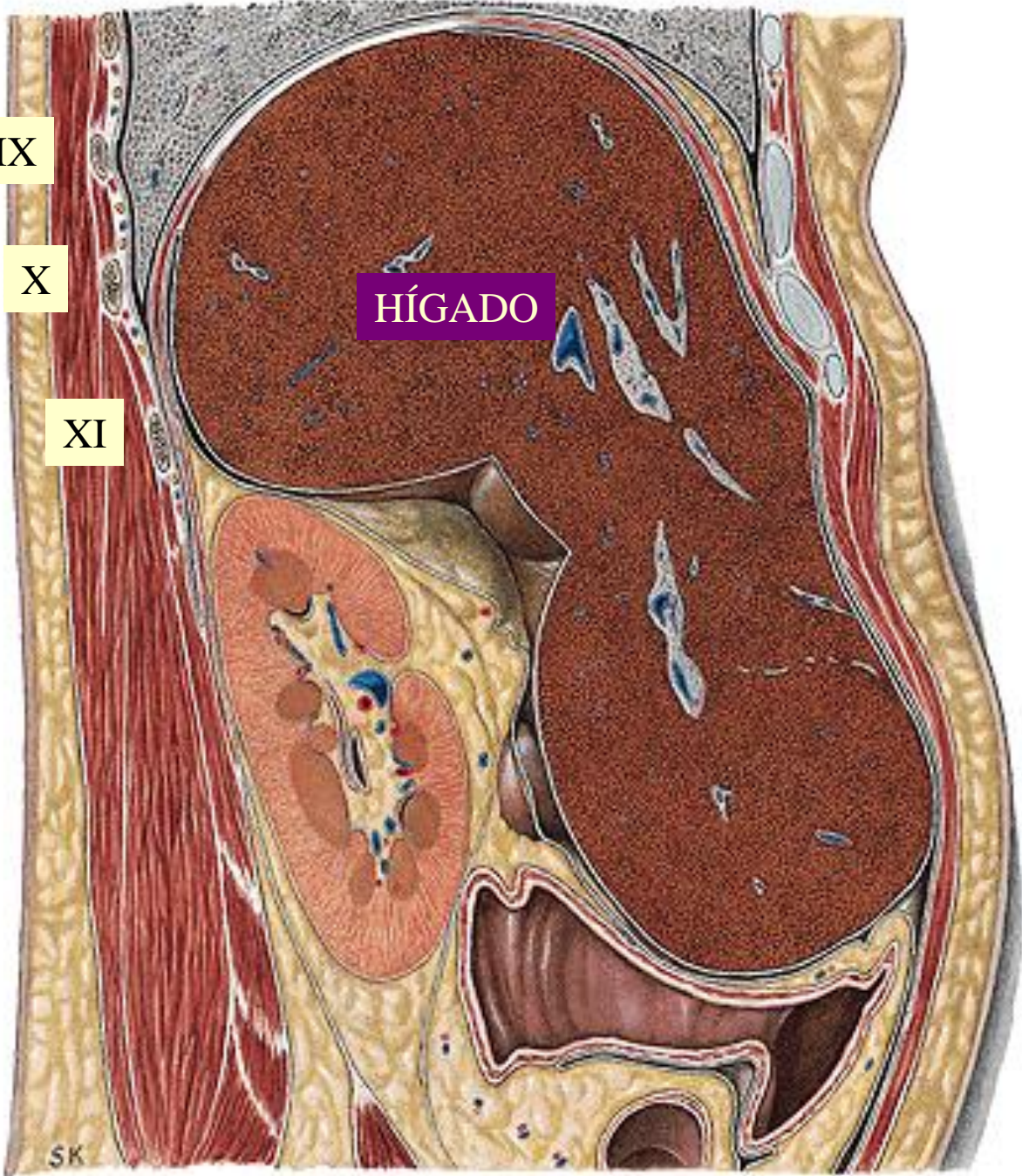


IX

X

XI

HÍGADO



SK

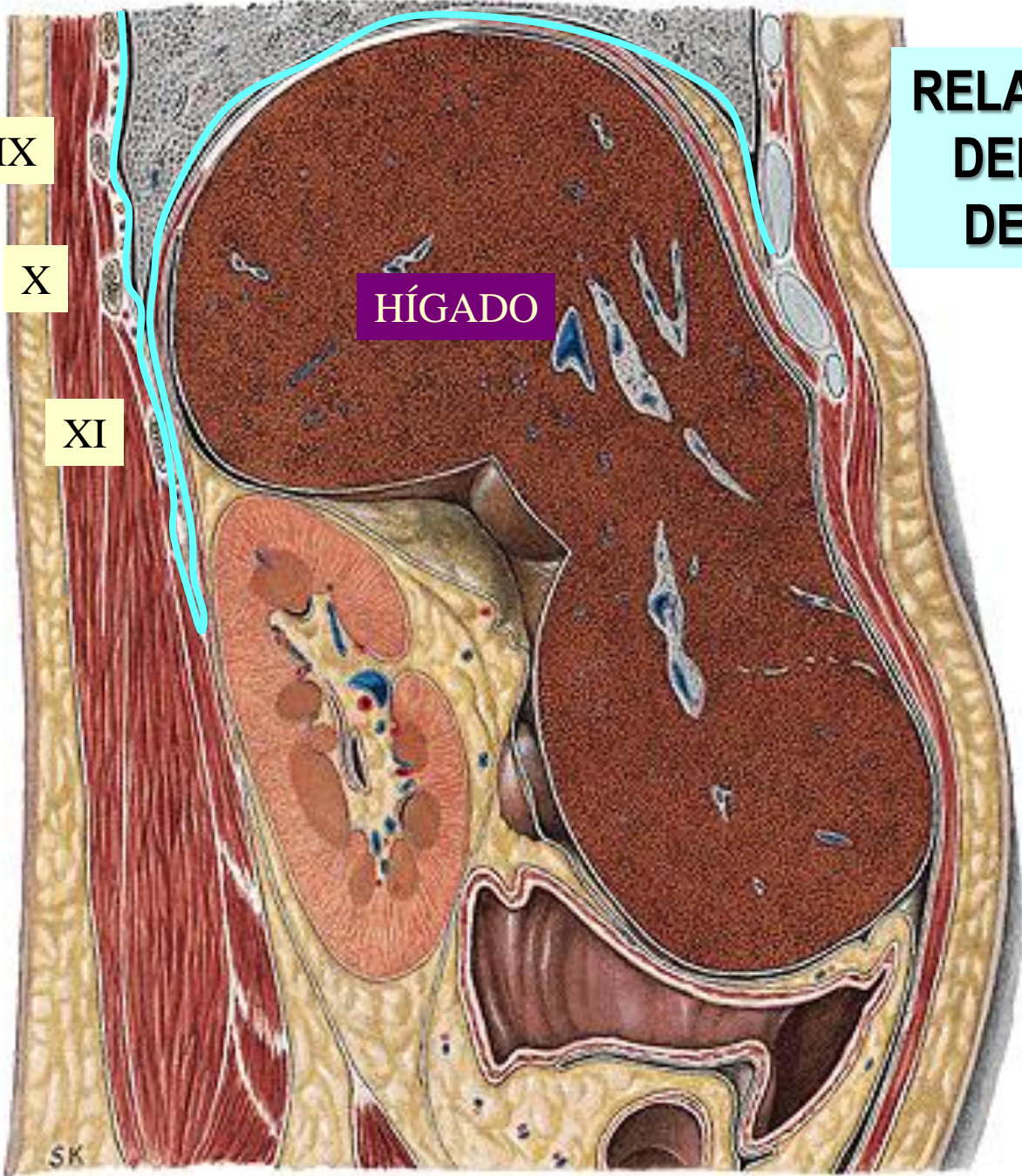
RELACIONES DEL RIÑÓN DERECHO

IX

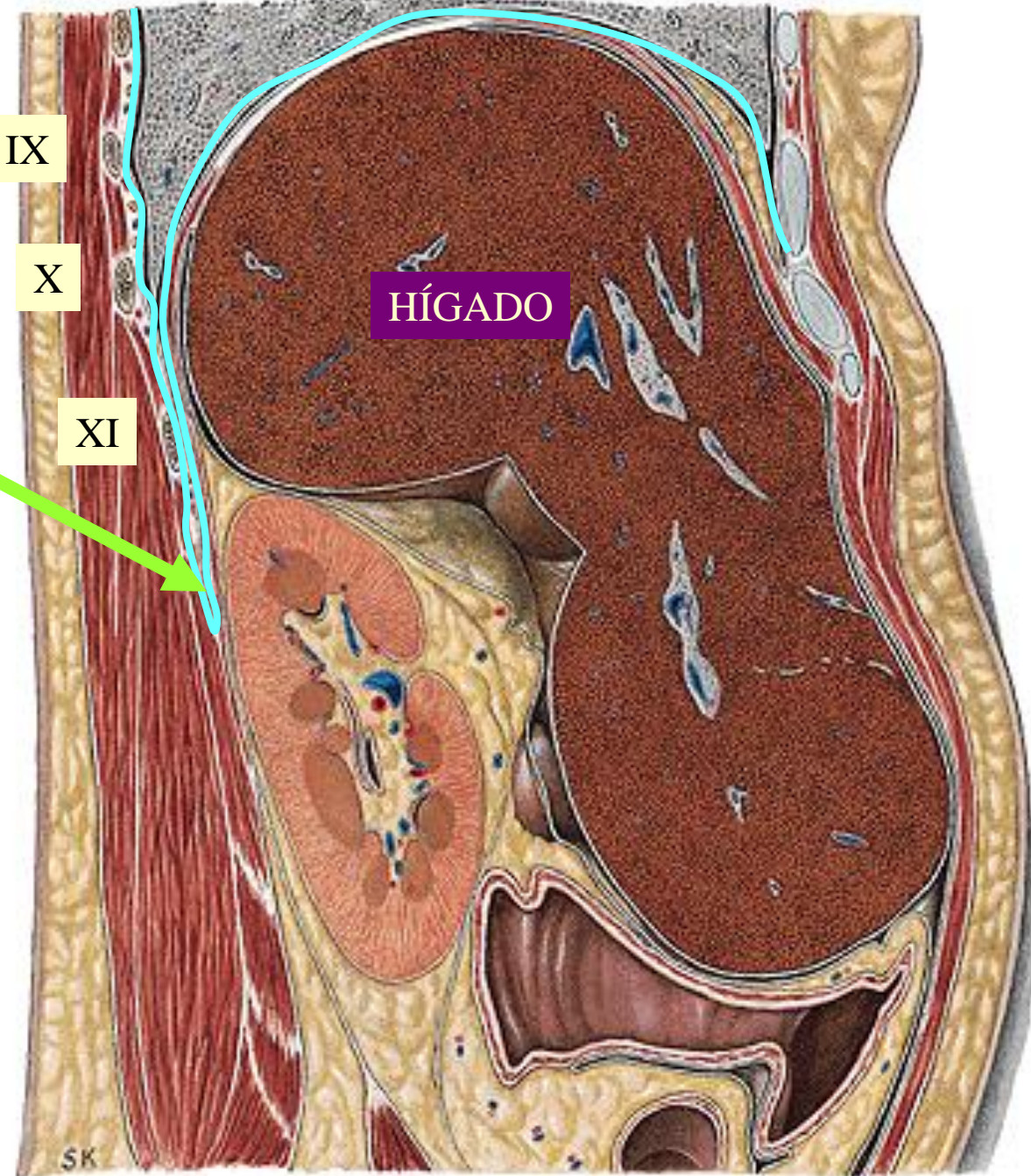
X

XI

HÍGADO



SK



IX

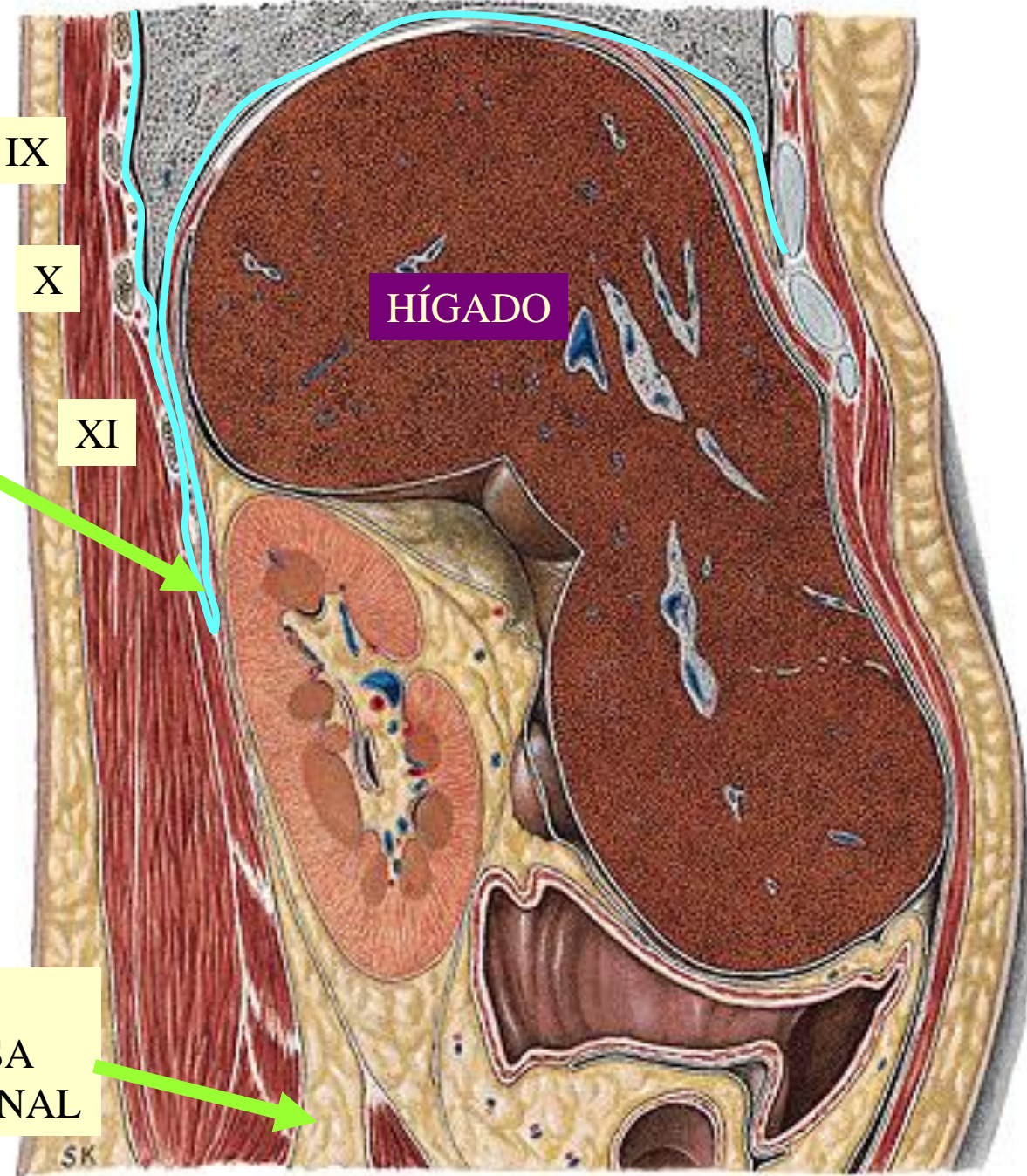
X

XI

HÍGADO

SENO
COSTO-
DIAFRAG-
MÁTICO

SK



IX

X

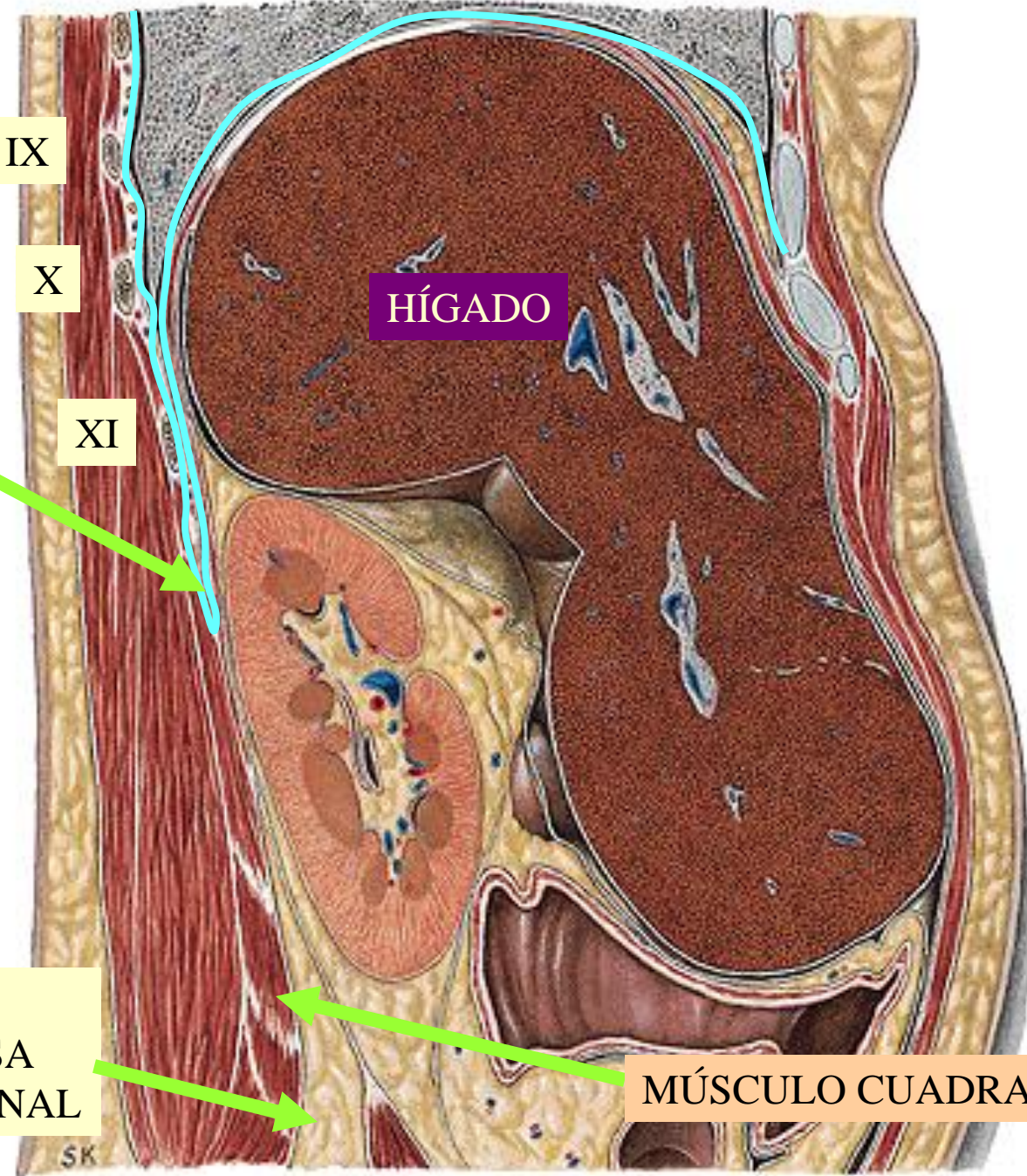
XI

HÍGADO

SENO
COSTO-
DIAFRAG-
MÁTICO

CAPA
ADIPOSA
PARARENAL

SK



IX

X

XI

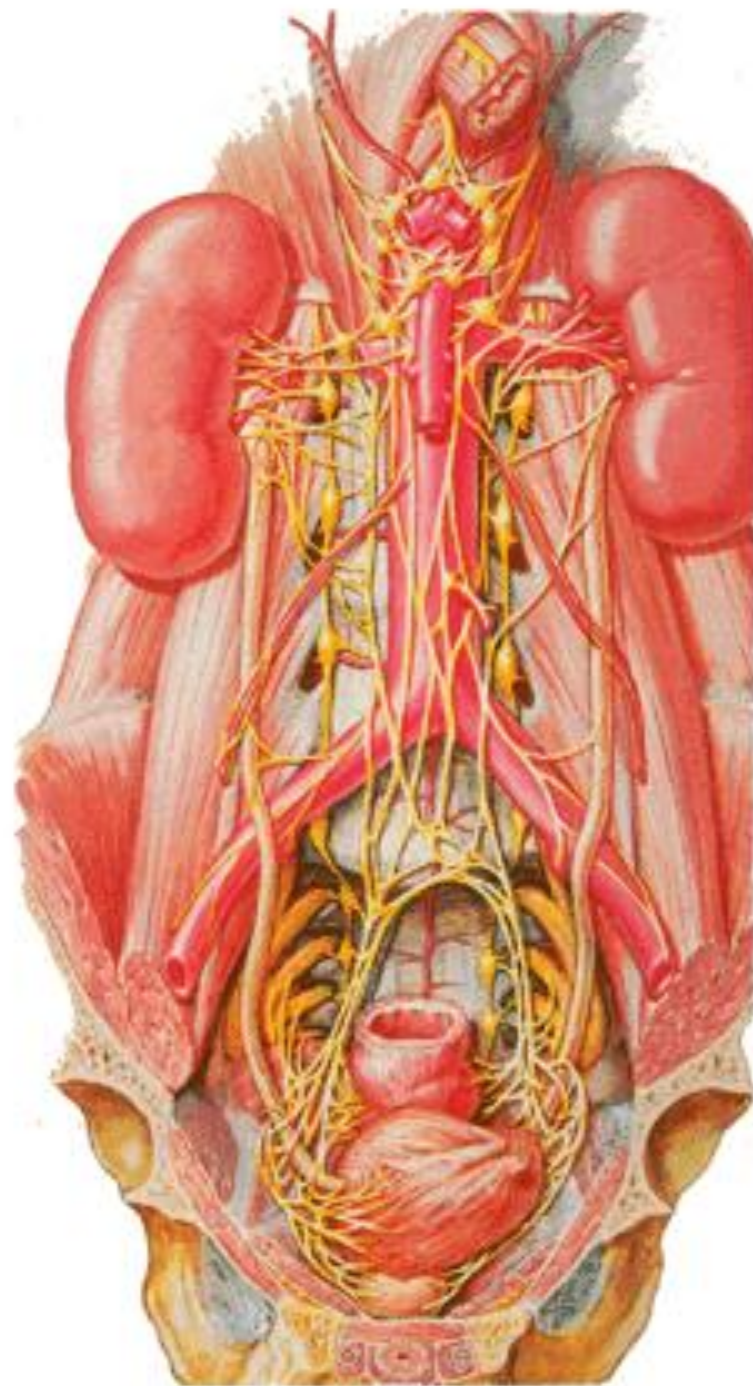
HÍGADO

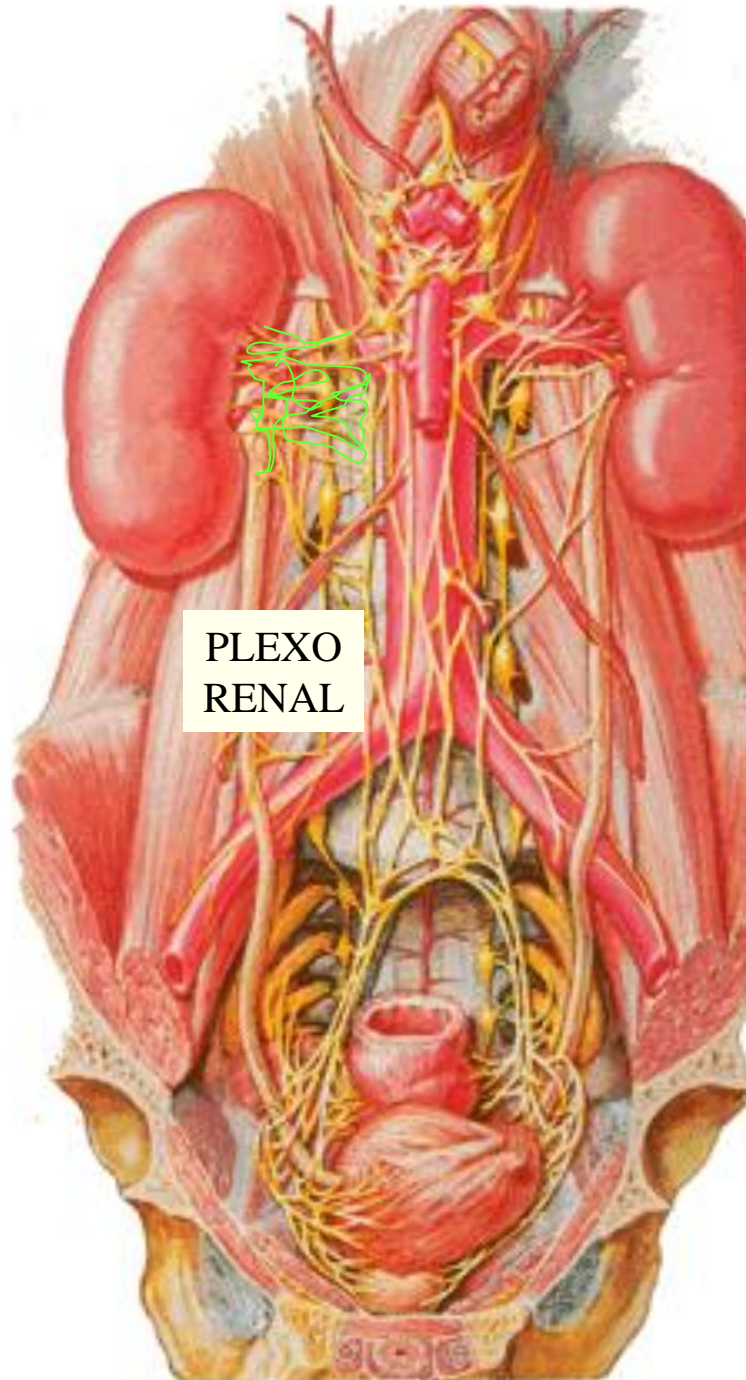
SENO
COSTO-
DIAFRAG-
MÁTICO

CAPA
ADIPOSA
PARARRENAL

MÚSCULO CUADRADO LUMBAR

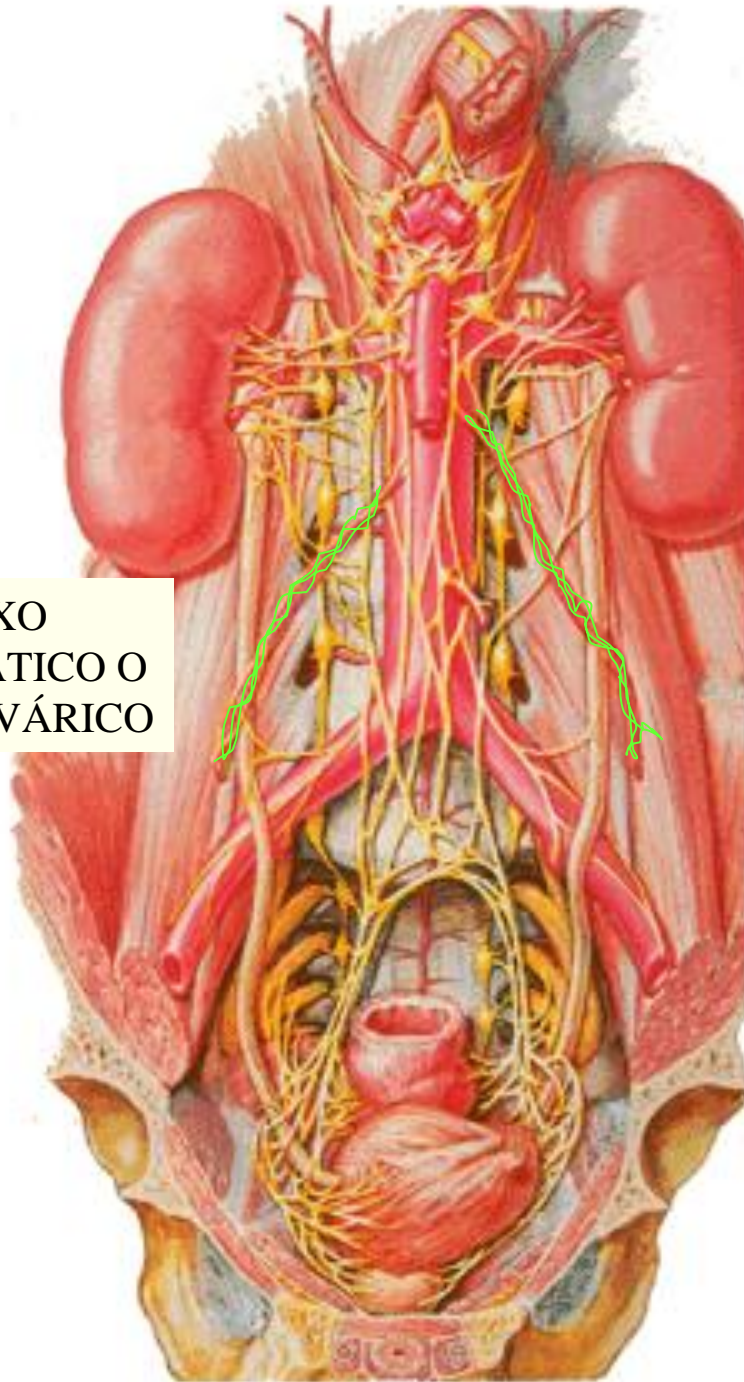
SK



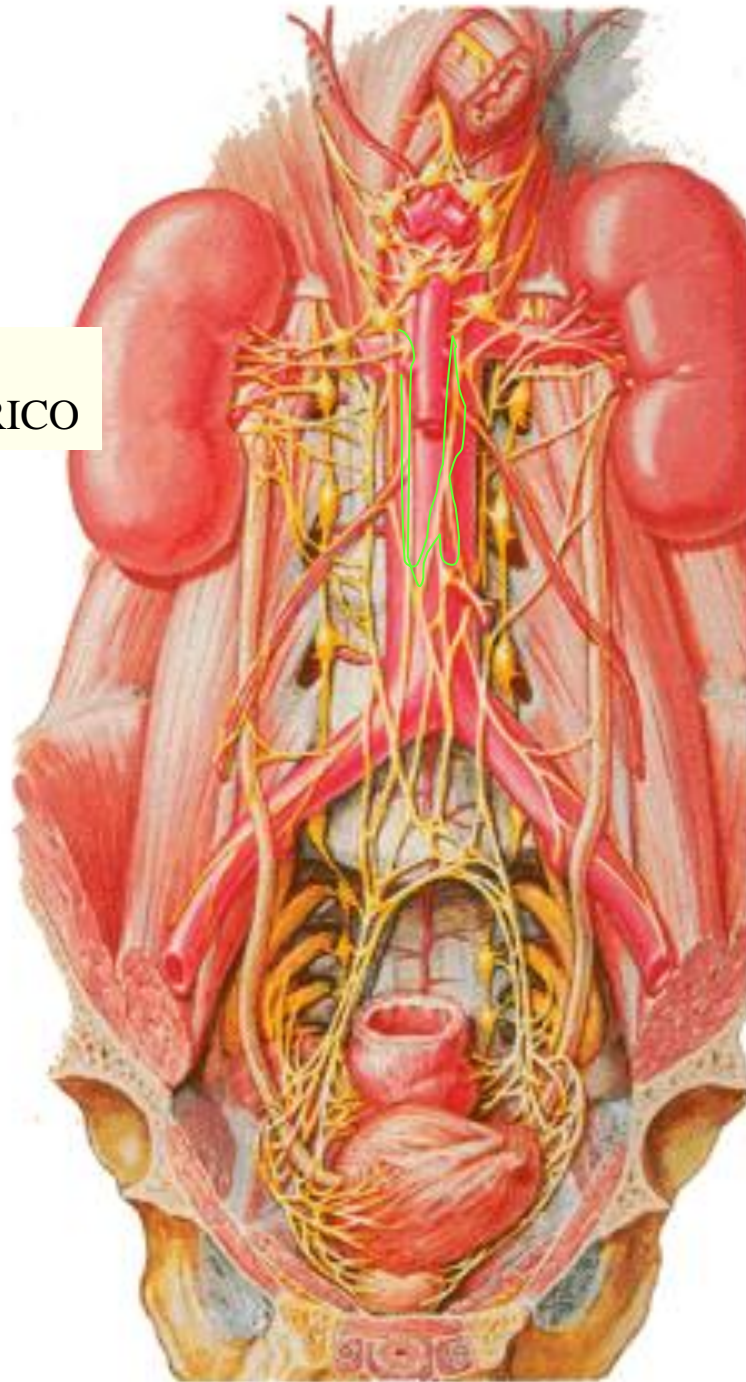

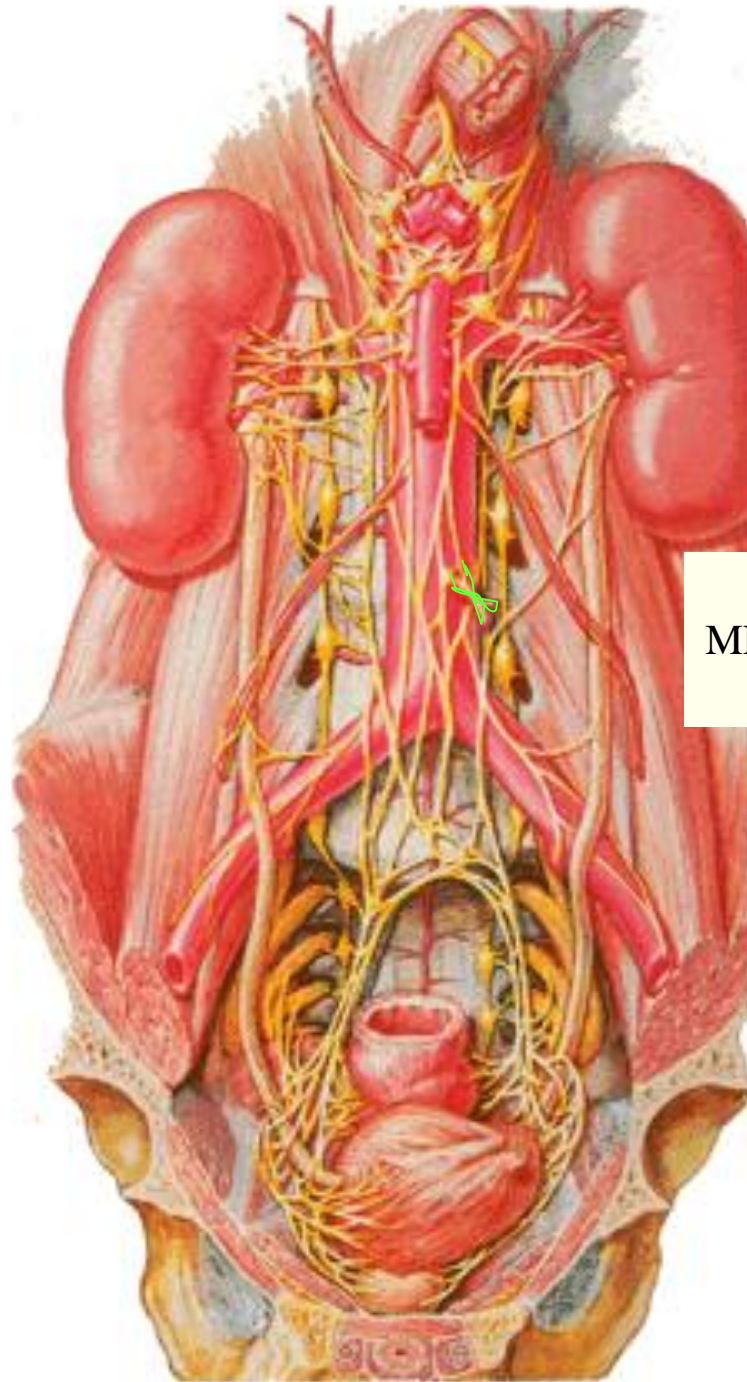
PLEXO
RENAL

PLEXO
ESPERMÁTICO O
ÚTERO-OVÁRICO



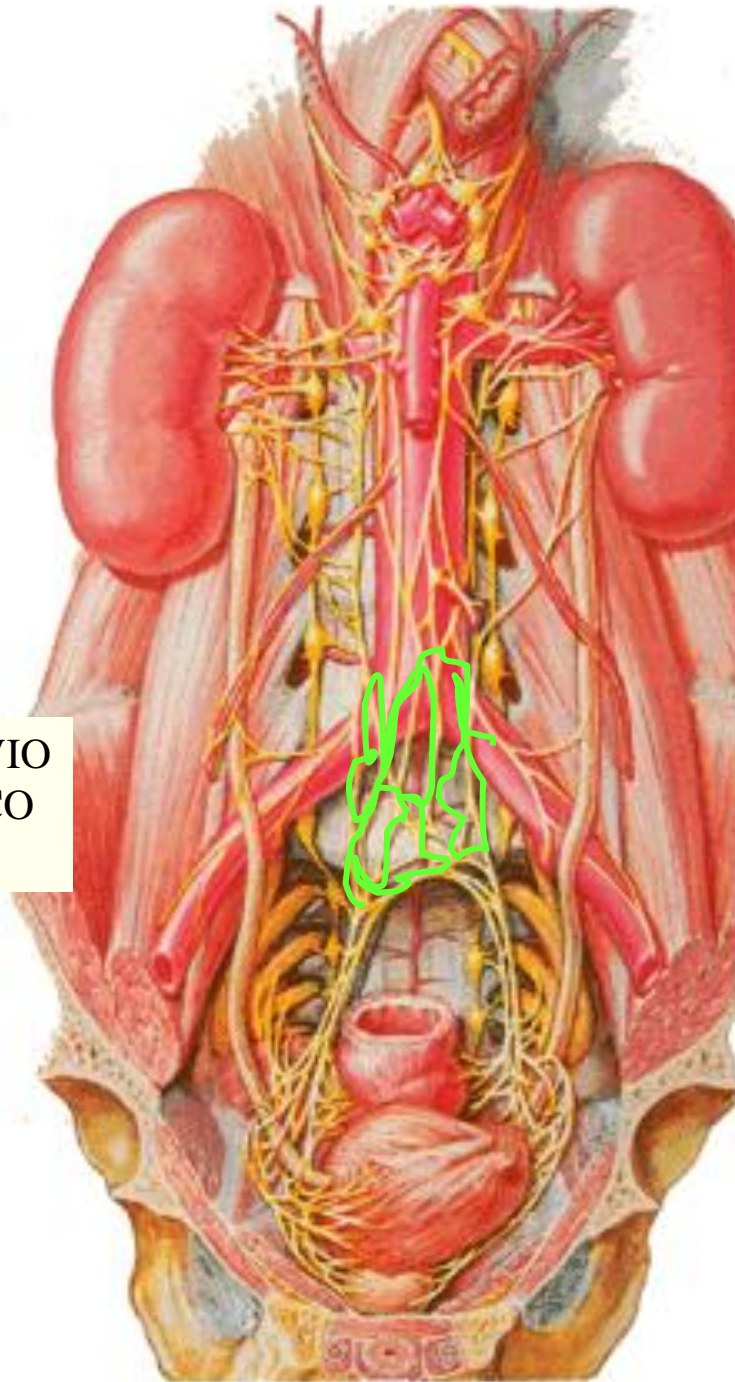
PLEXO
INTERMESENTÉRICO



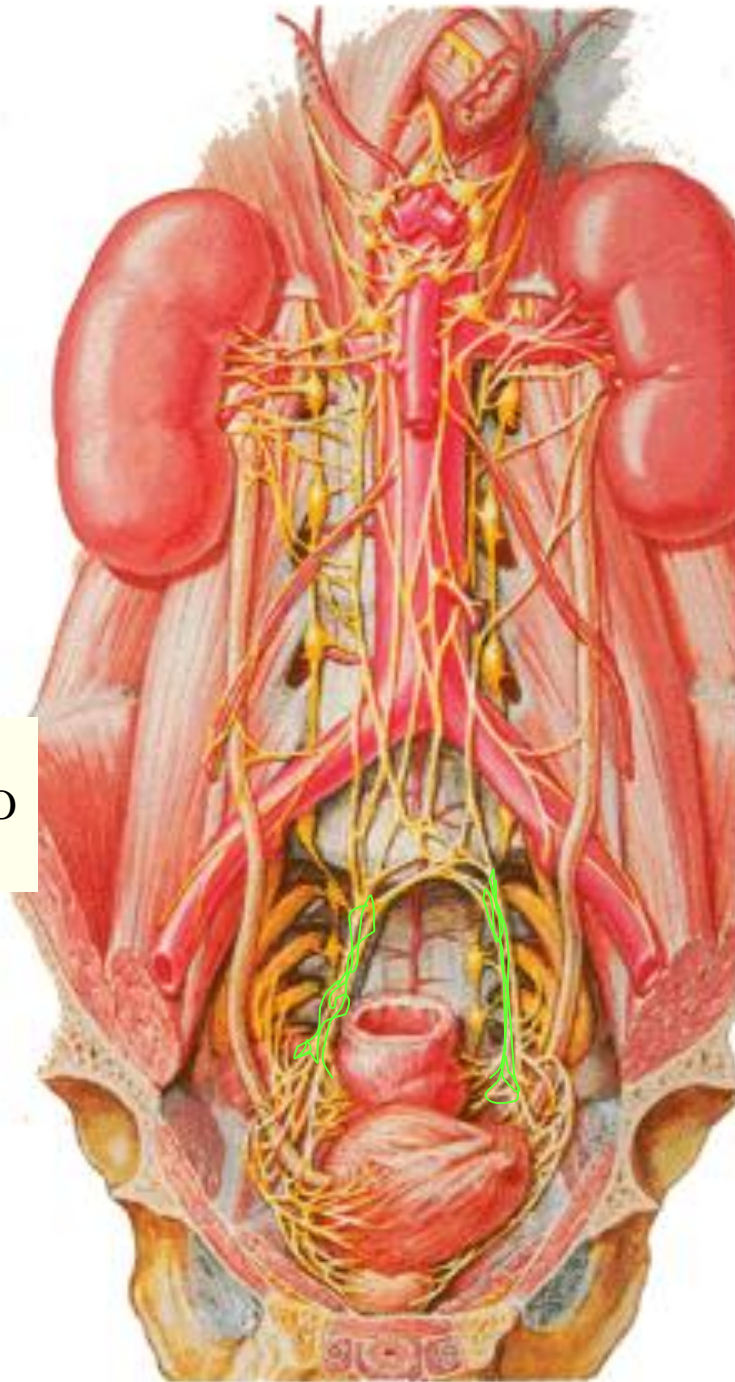


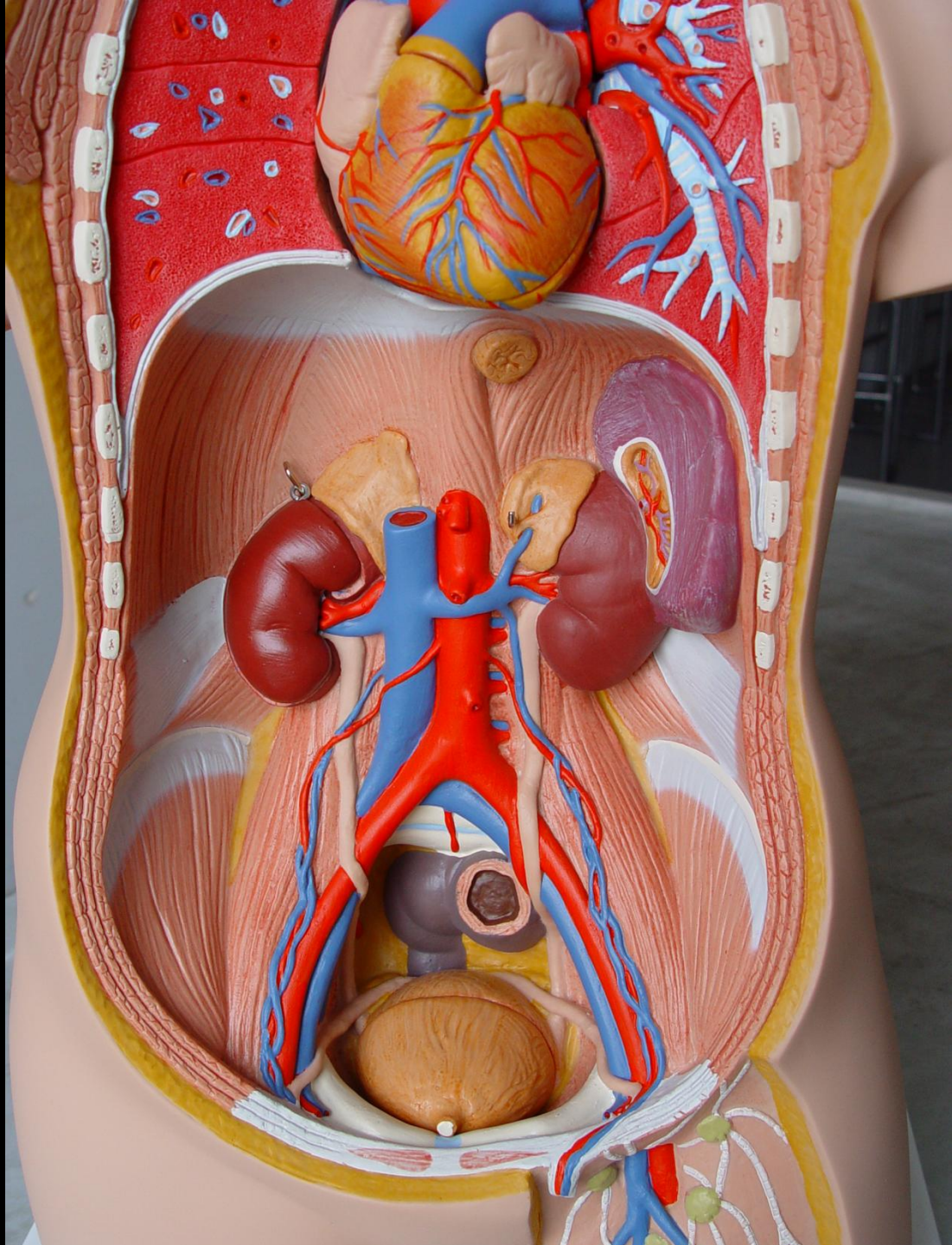
PLEXO
MESENTÉRICO
INFERIOR

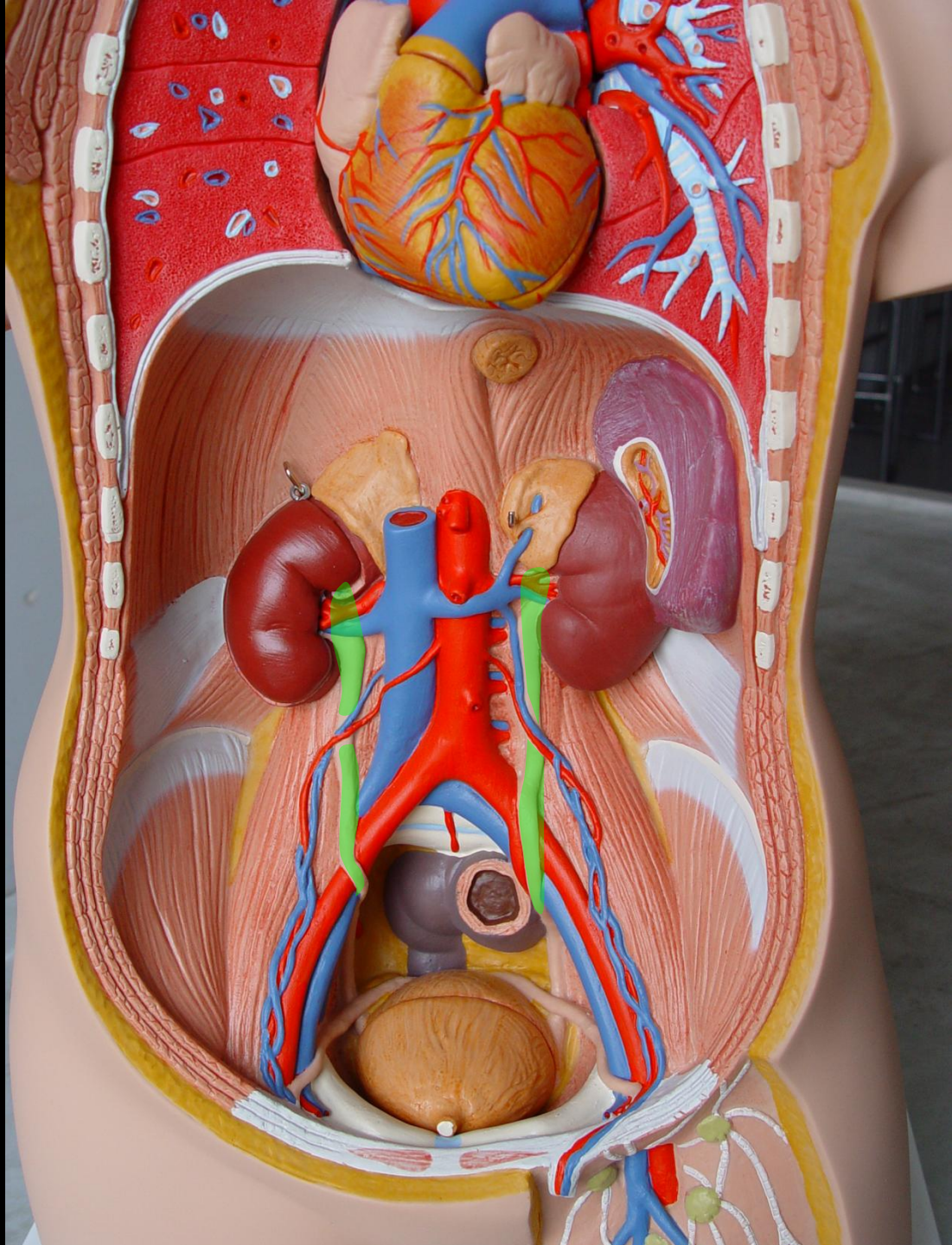
PLEXO O NERVIO
HIPOGÁSTRICO
SUPERIOR

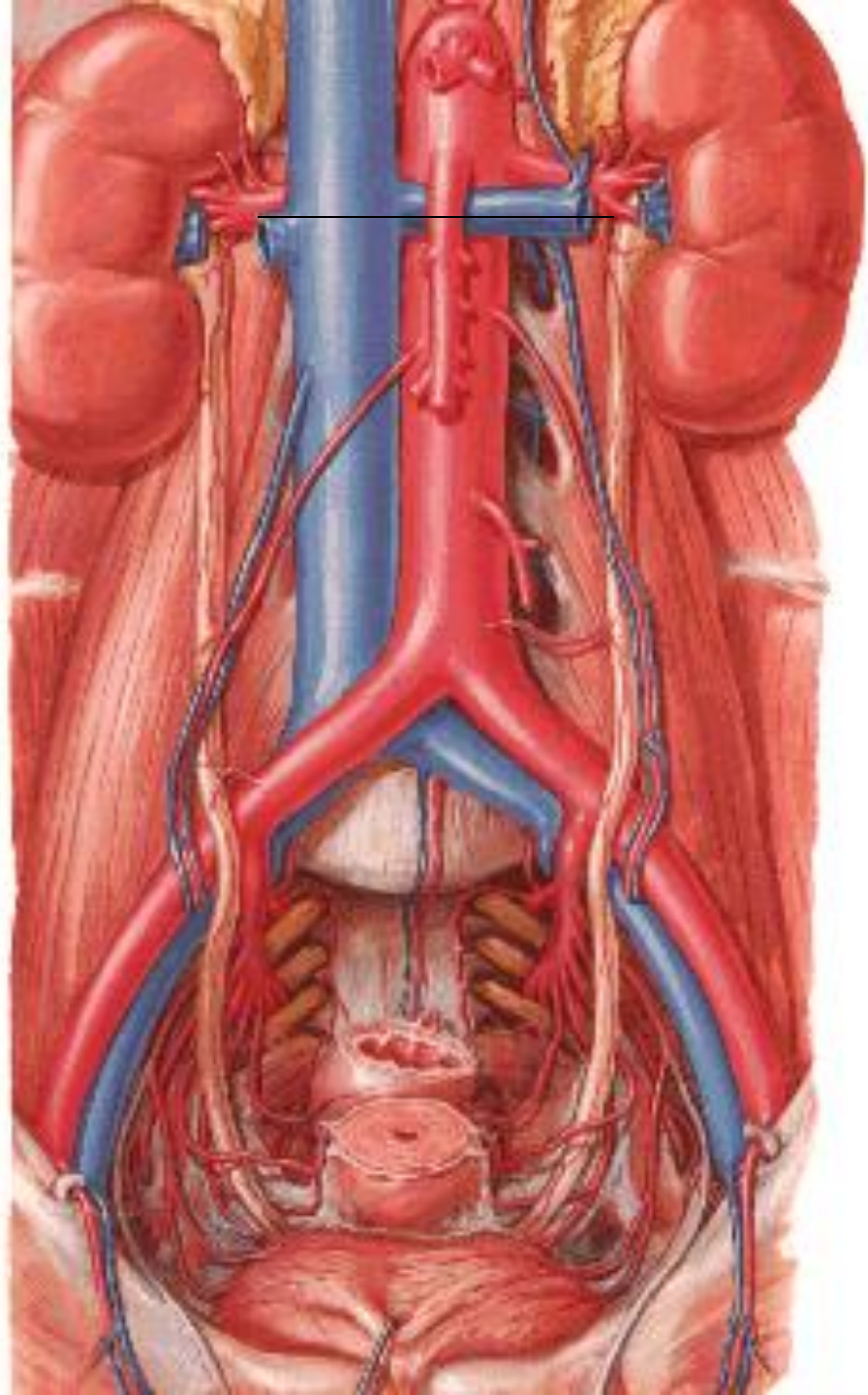


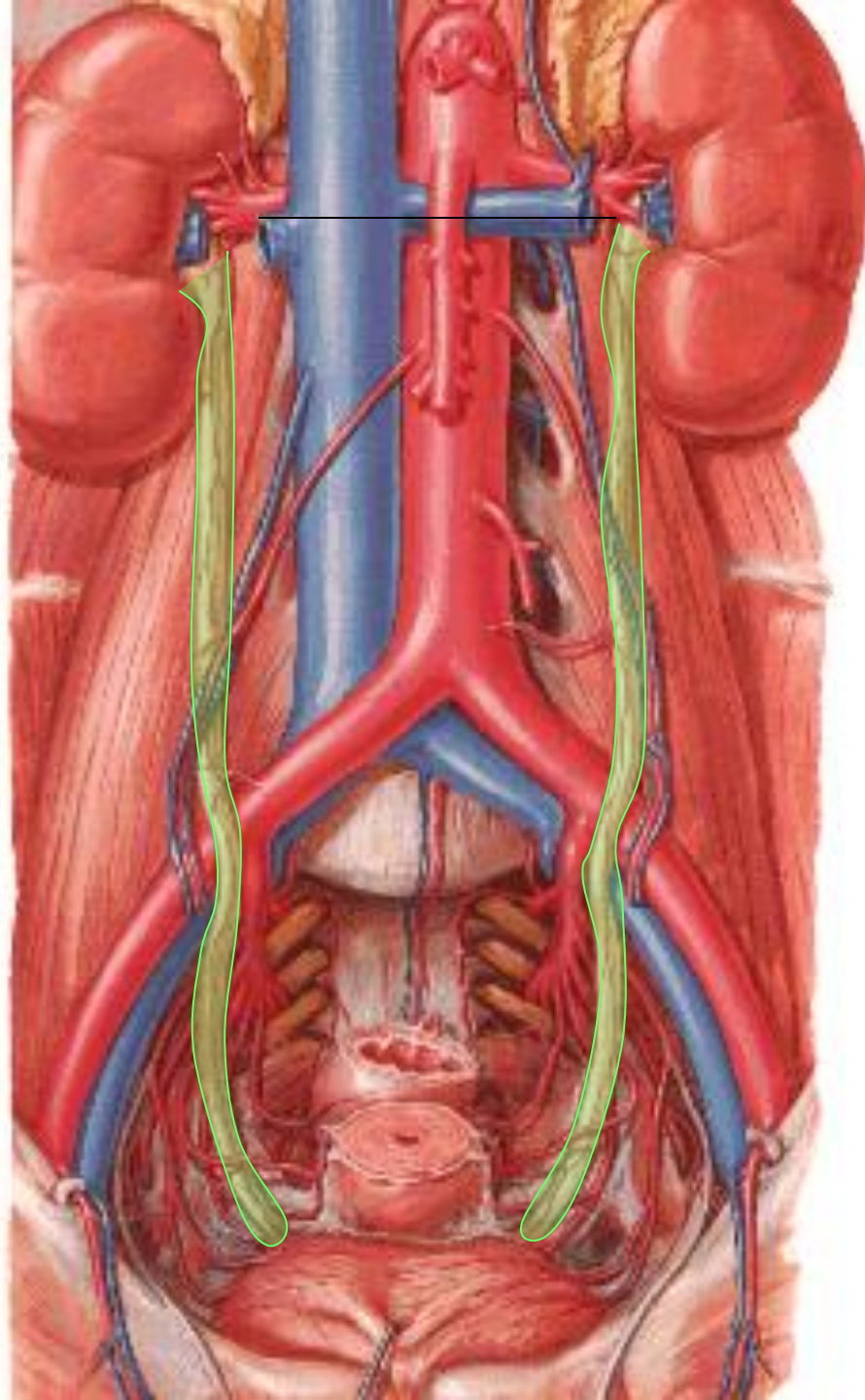
NERVIO
HIPOGÁSTRICO
INFERIOR



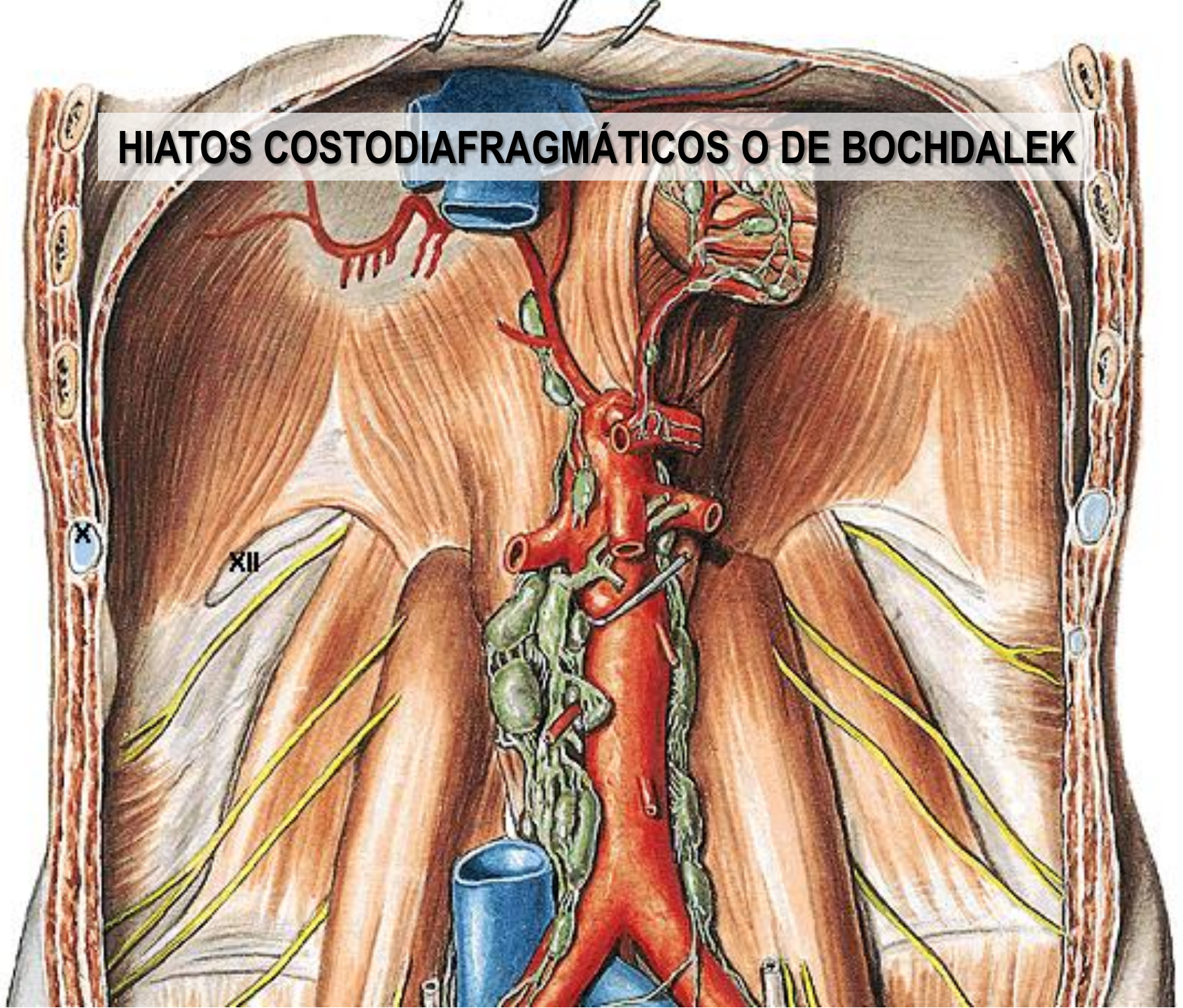




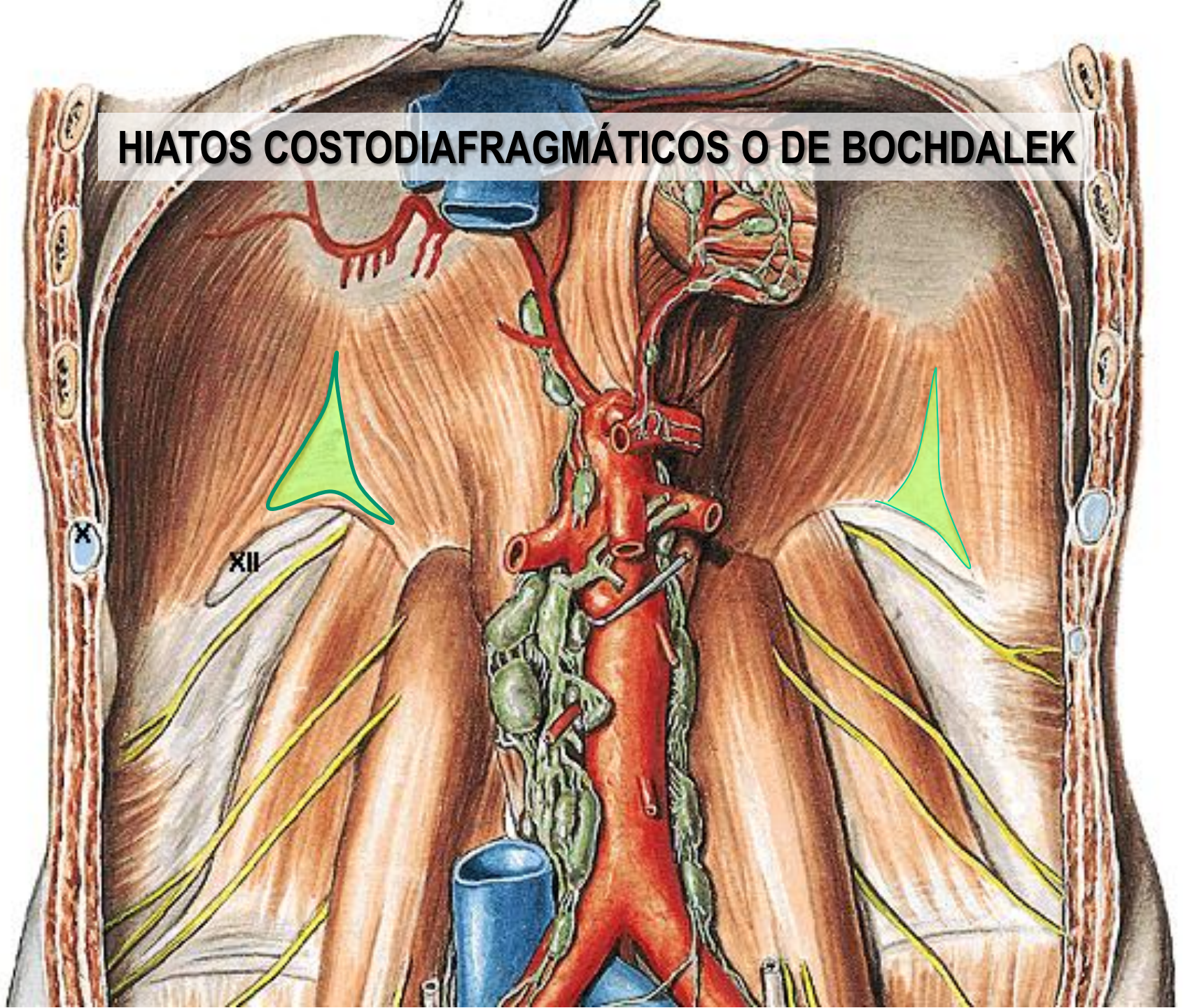


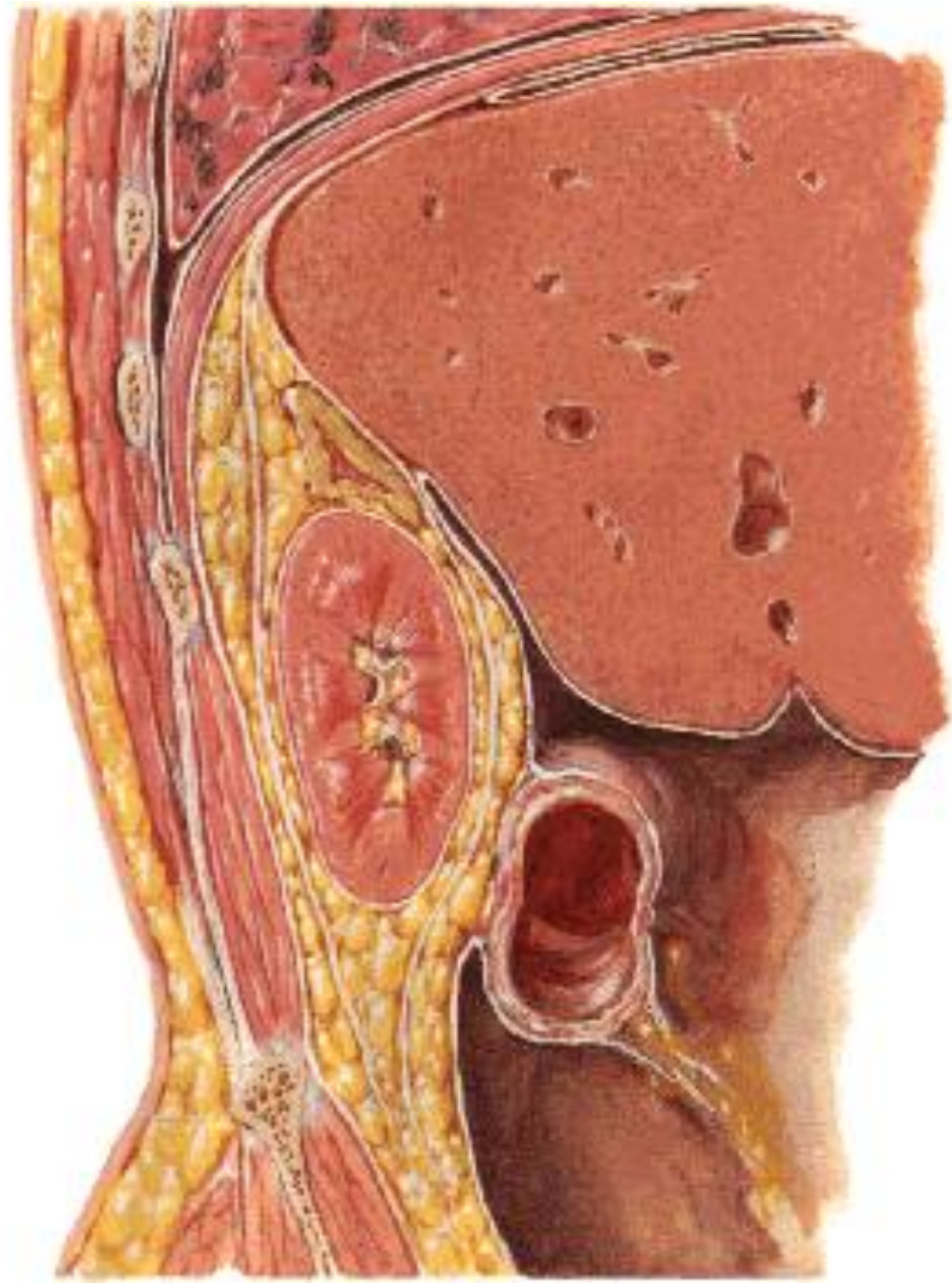


HIATOS COSTODIAFRAGMÁTICOS O DE BOCHDALEK

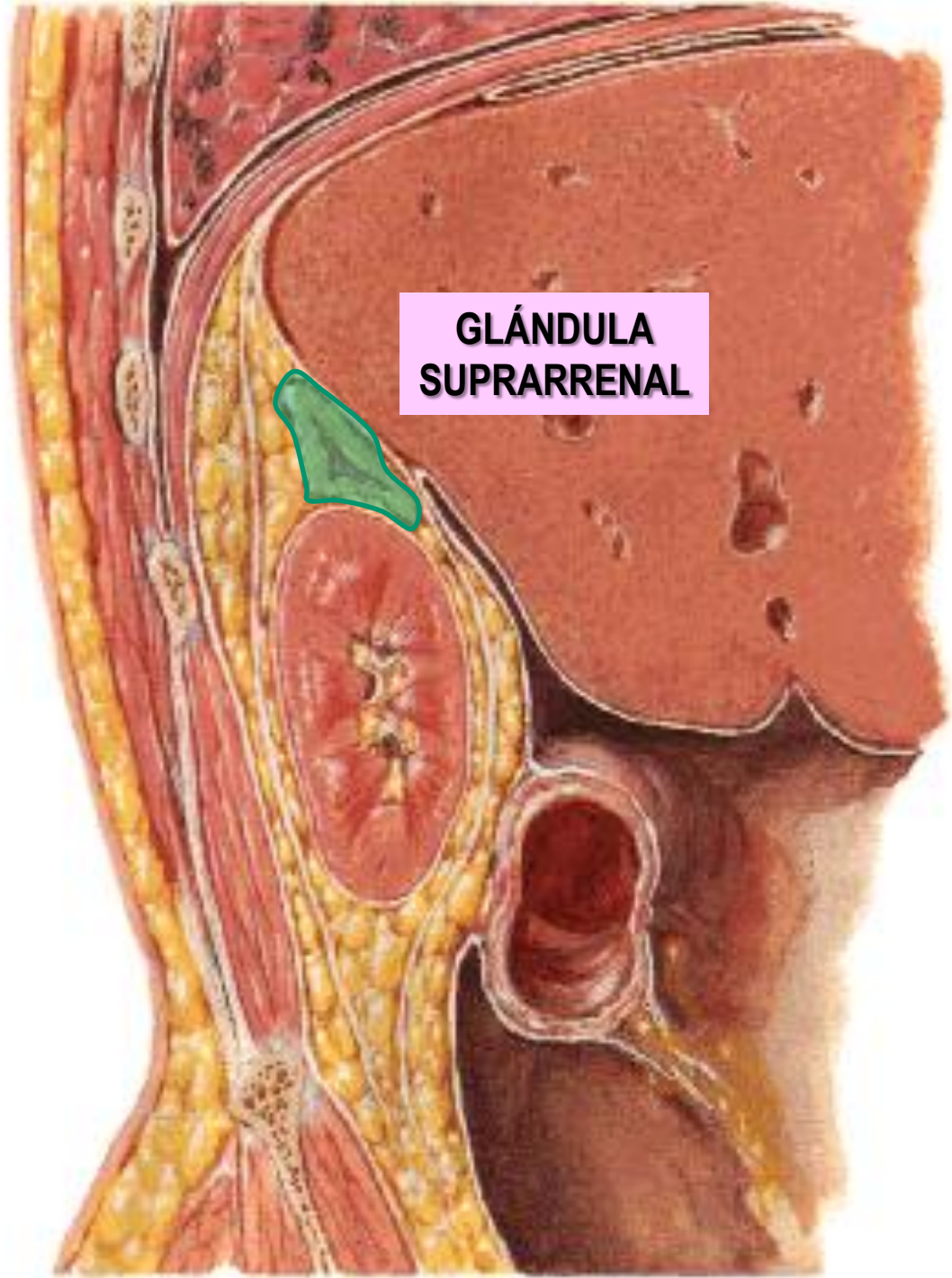


HIATOS COSTODIAFRAGMÁTICOS O DE BOCHDALEK

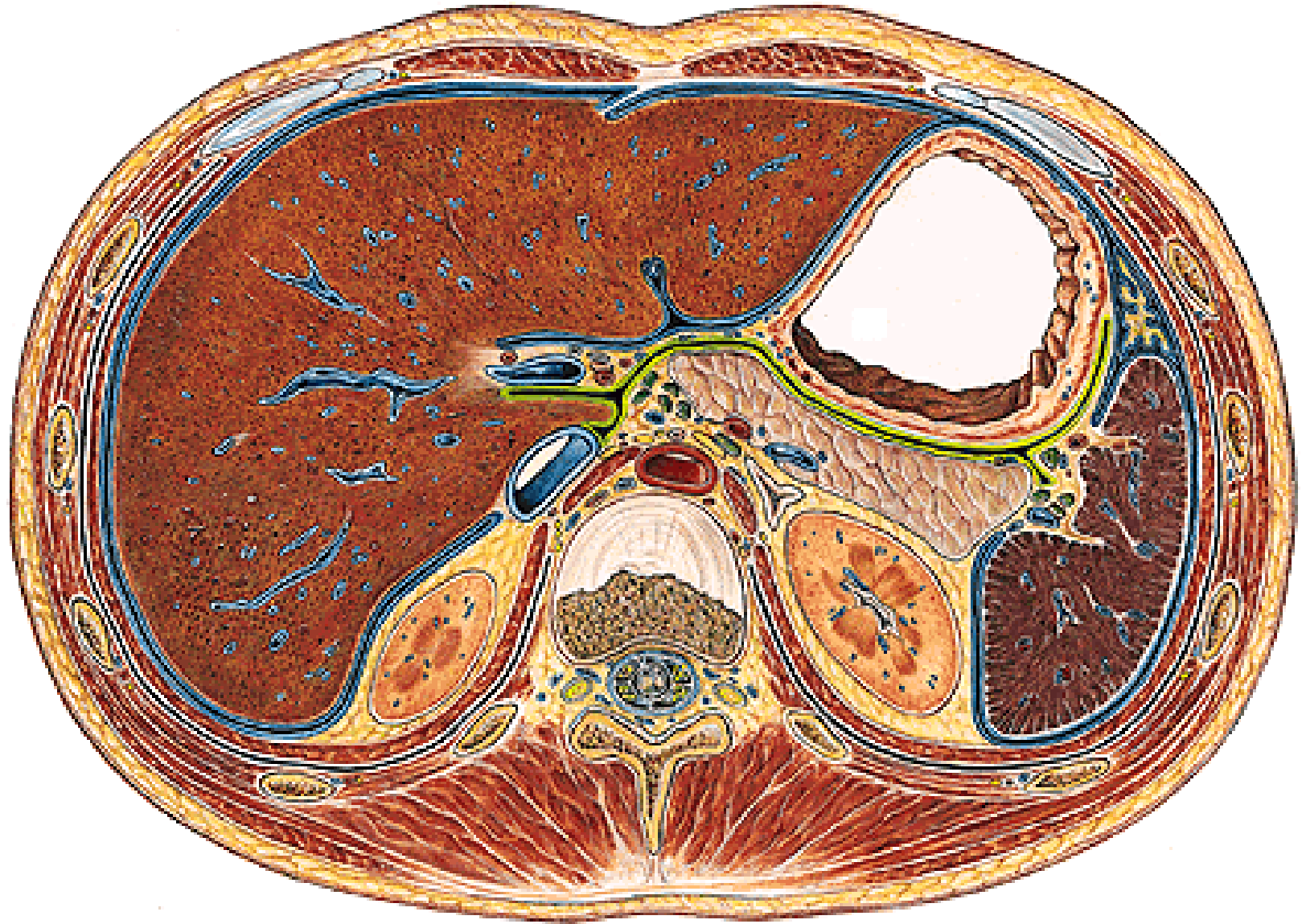




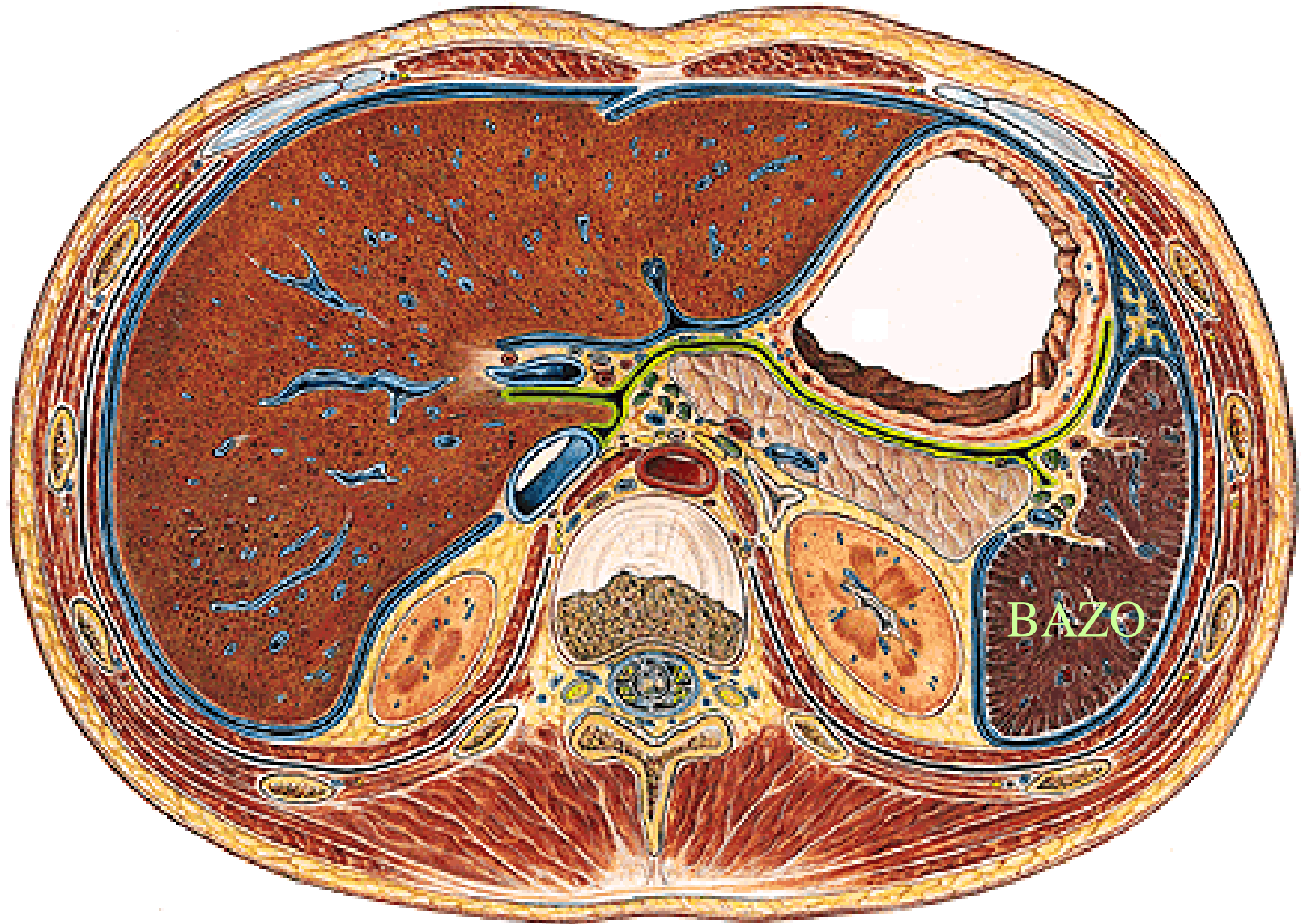
**GLÁNDULA
SUPRARRENAL**



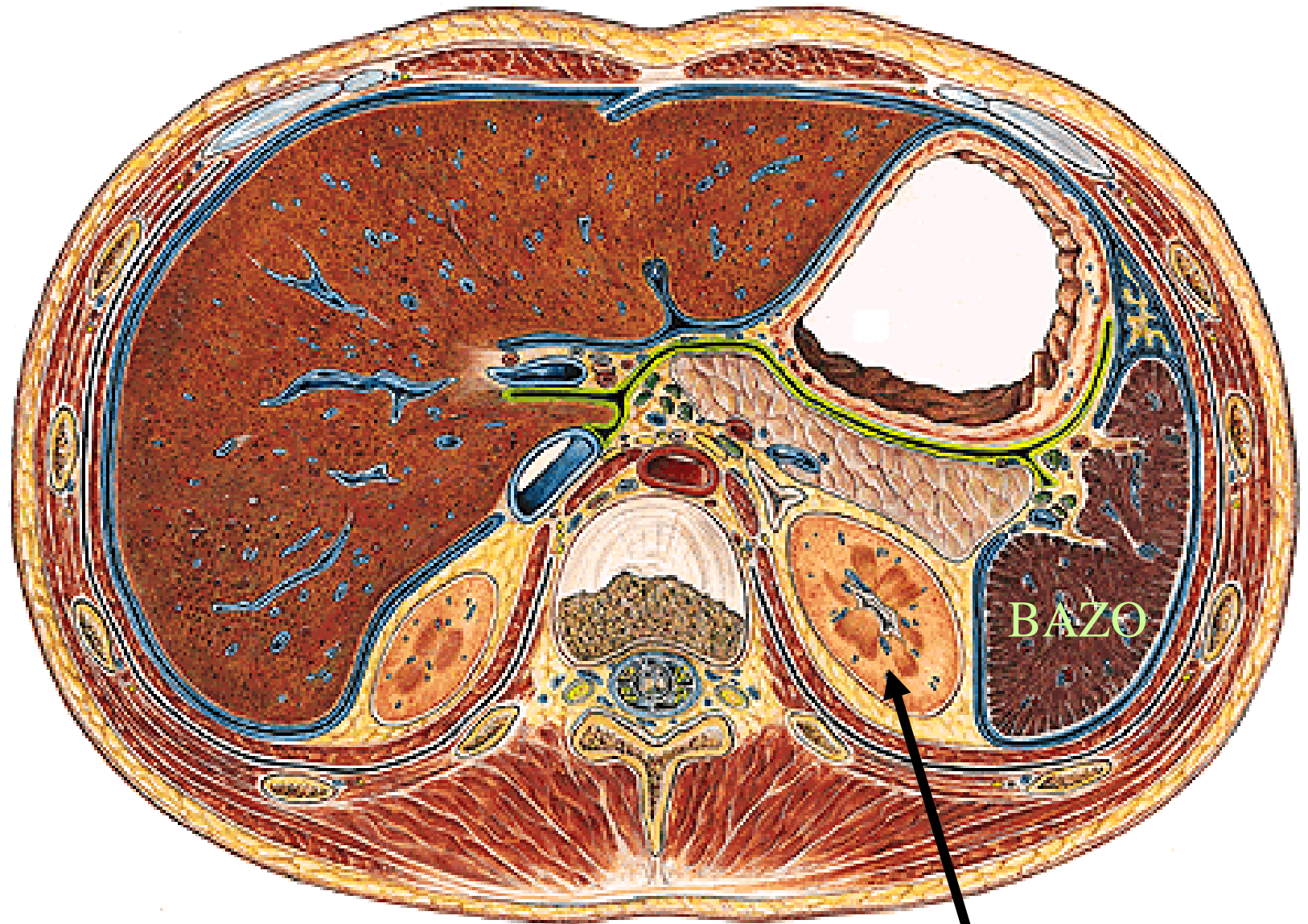
CORTE CAUDAL A NIVEL DEL BAZO



CORTE CAUDAL A NIVEL DEL BAZO

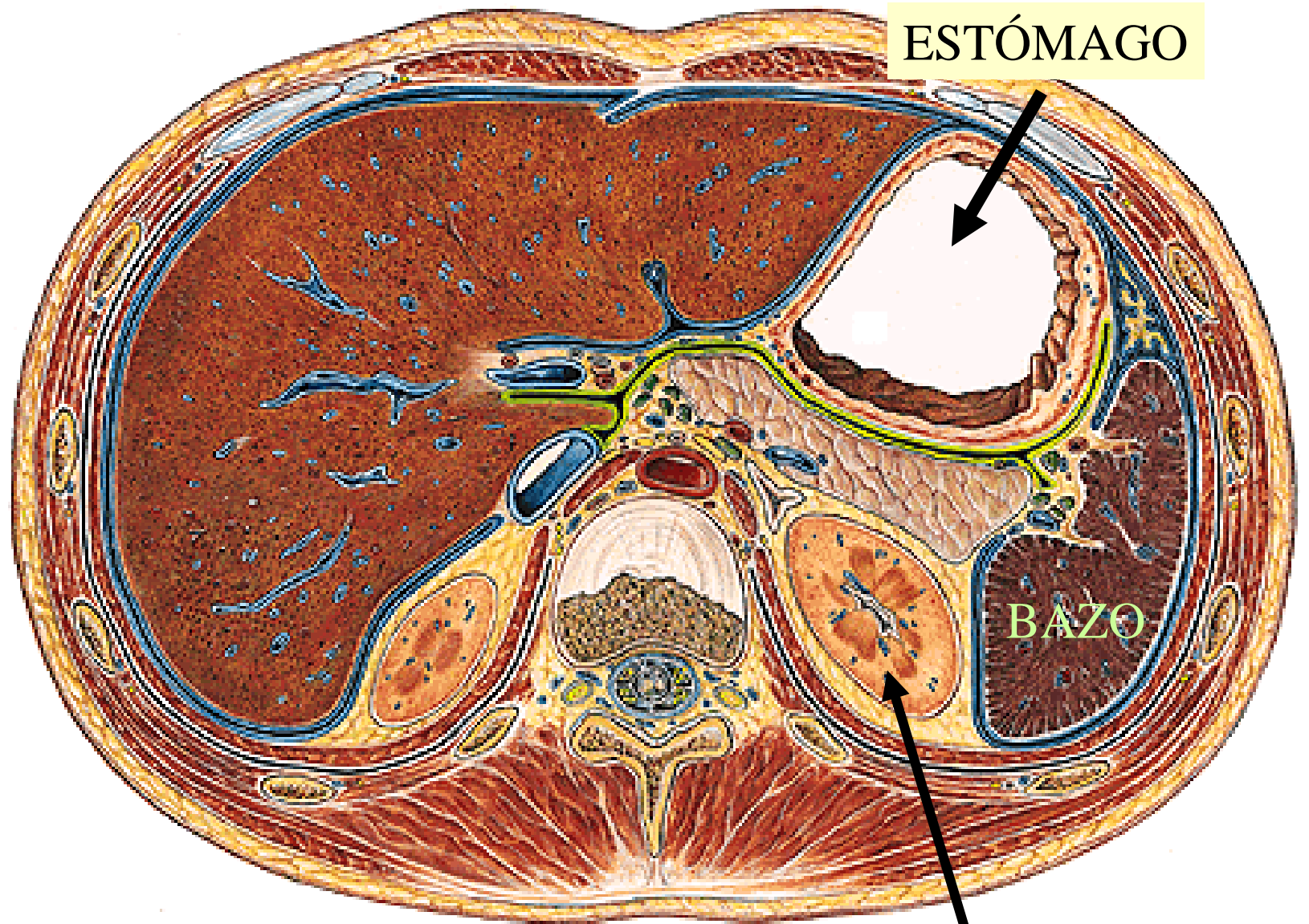


CORTE CAUDAL A NIVEL DEL BAZO



RIÑÓN IZQUIERDO

CORTE CAUDAL A NIVEL DEL BAZO

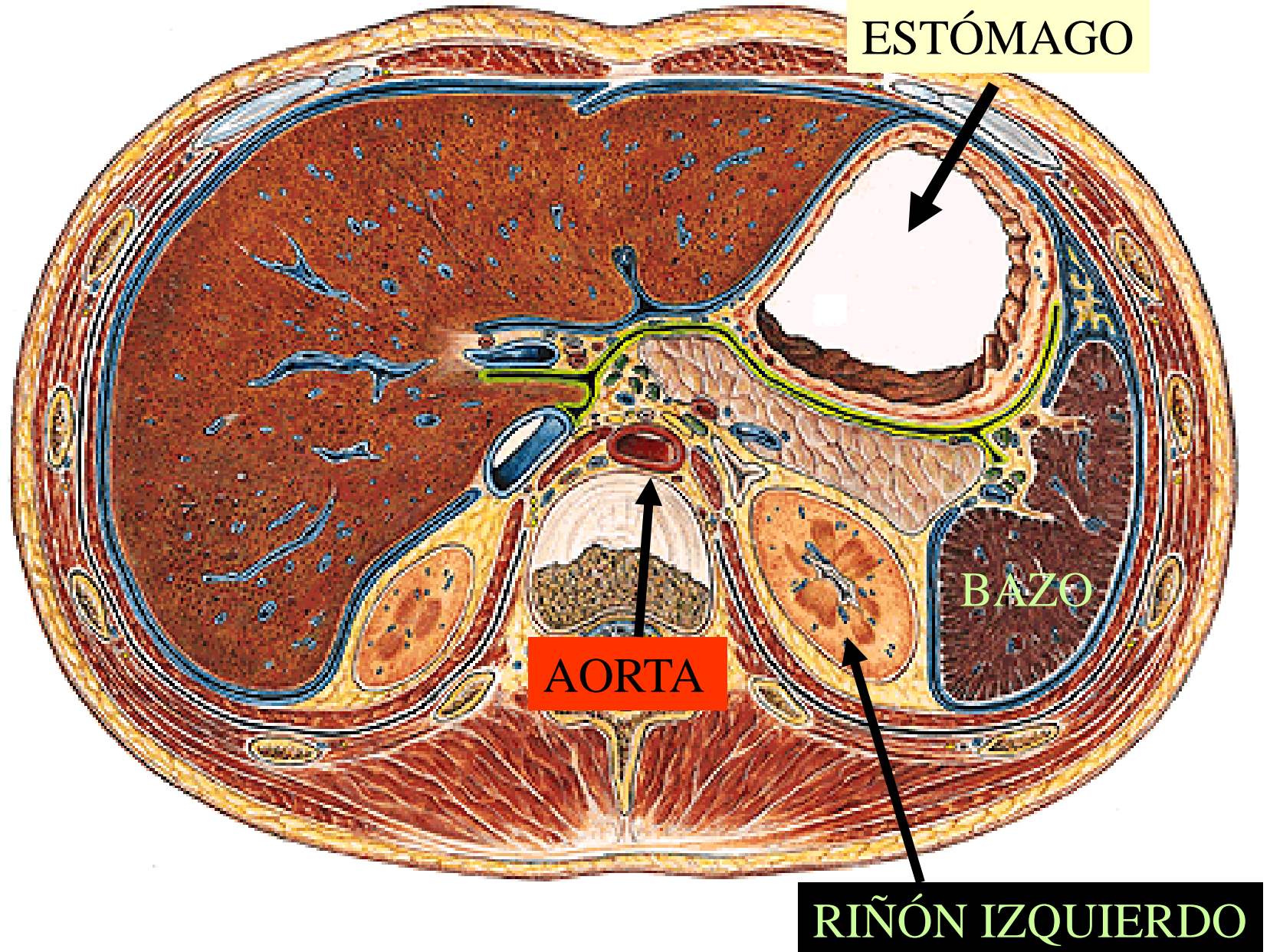


ESTÓMAGO

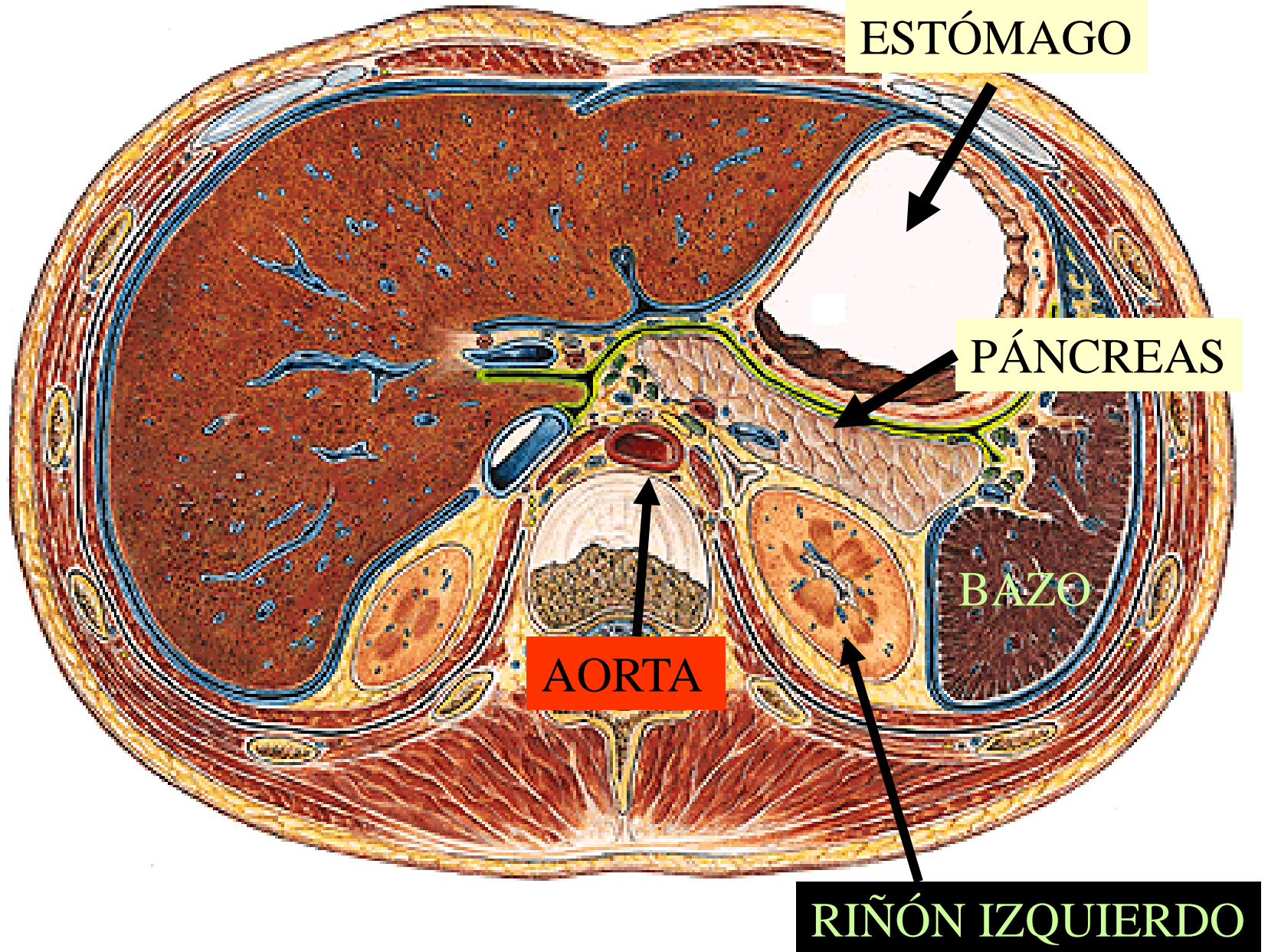
BAZO

RIÑÓN IZQUIERDO

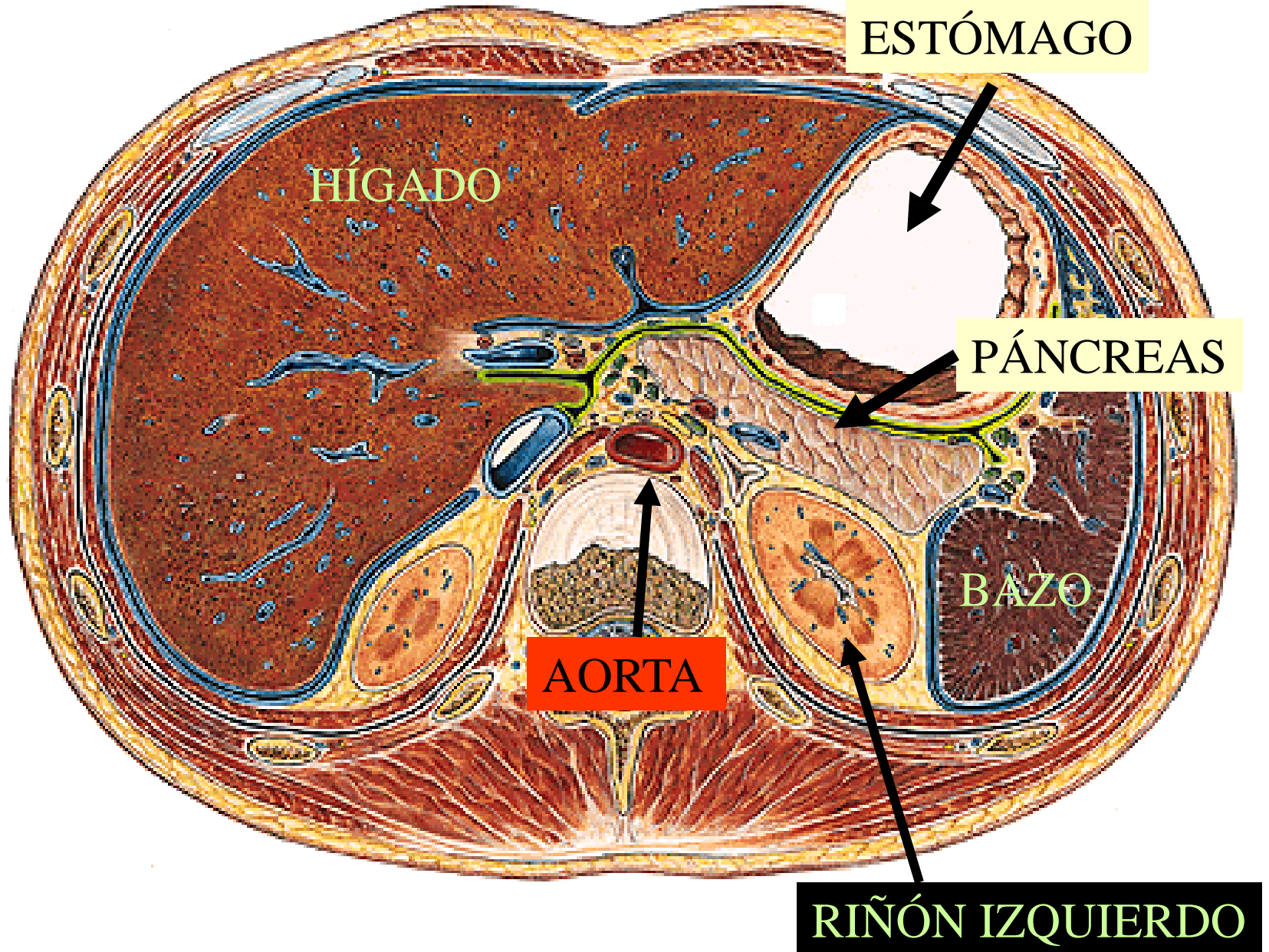
CORTE CAUDAL A NIVEL DEL BAZO



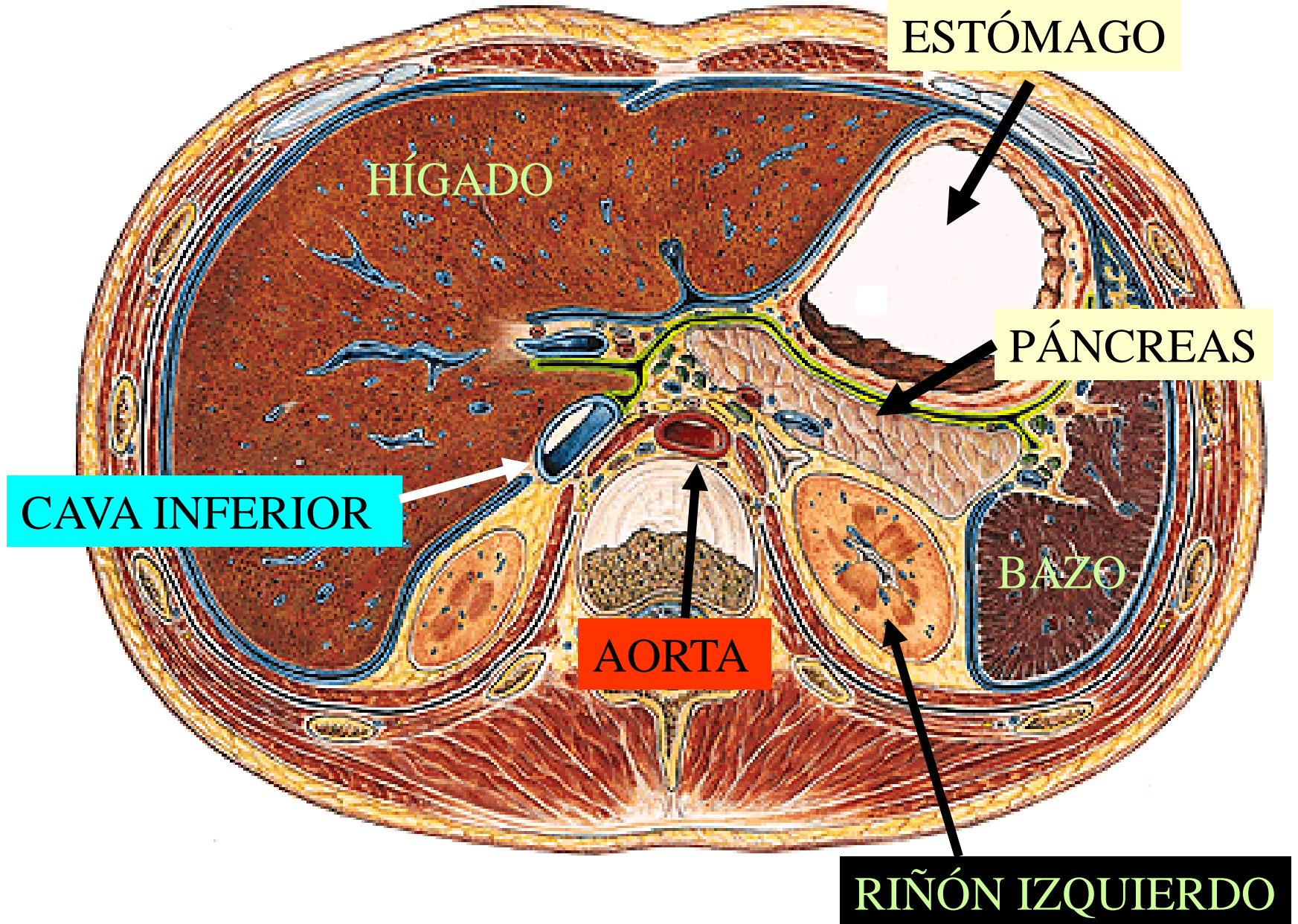
CORTE CAUDAL A NIVEL DEL BAZO



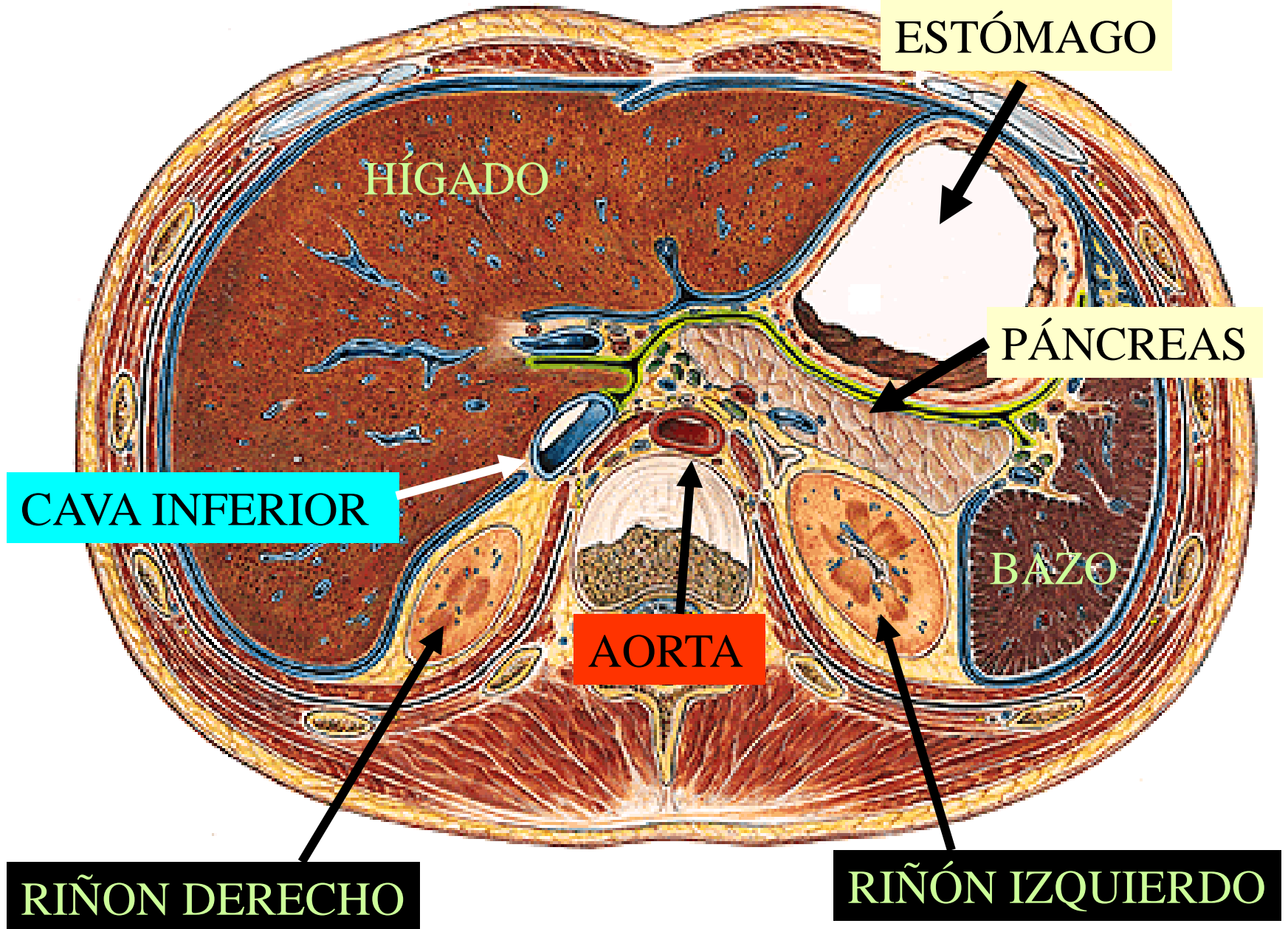
CORTE CAUDAL A NIVEL DEL BAZO

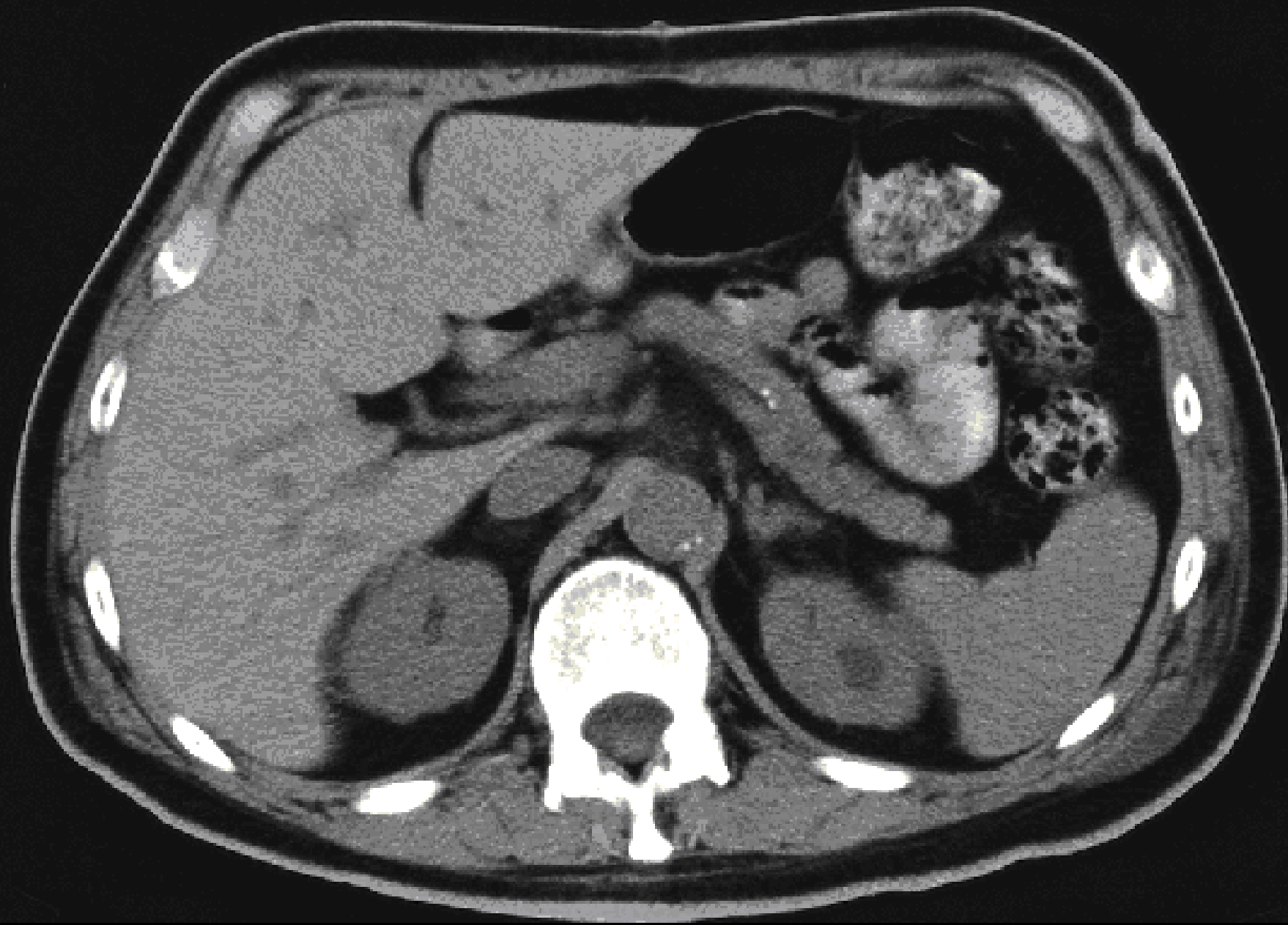

CORTE CAUDAL A NIVEL DEL BAZO



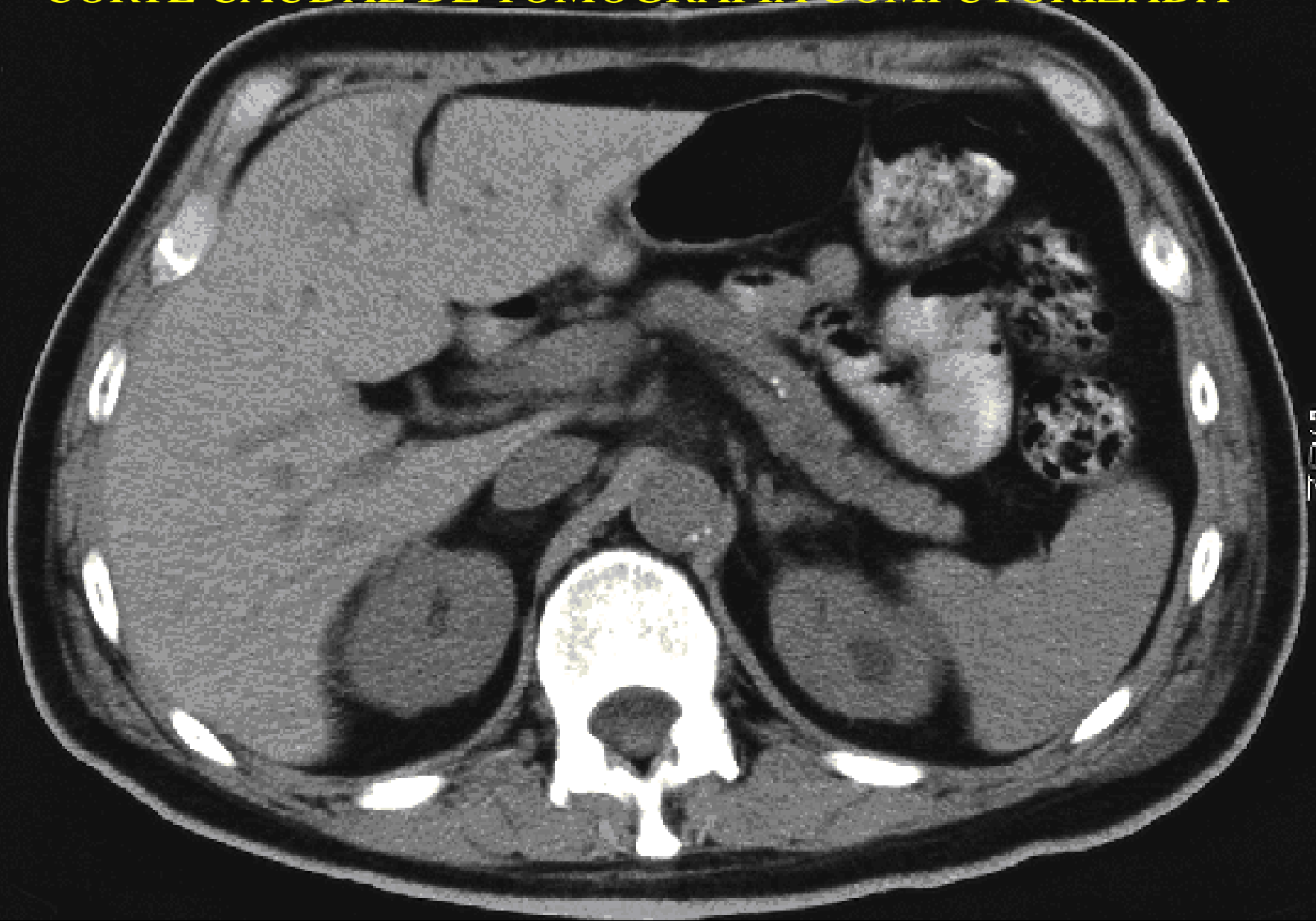
CORTE CAUDAL A NIVEL DEL BAZO



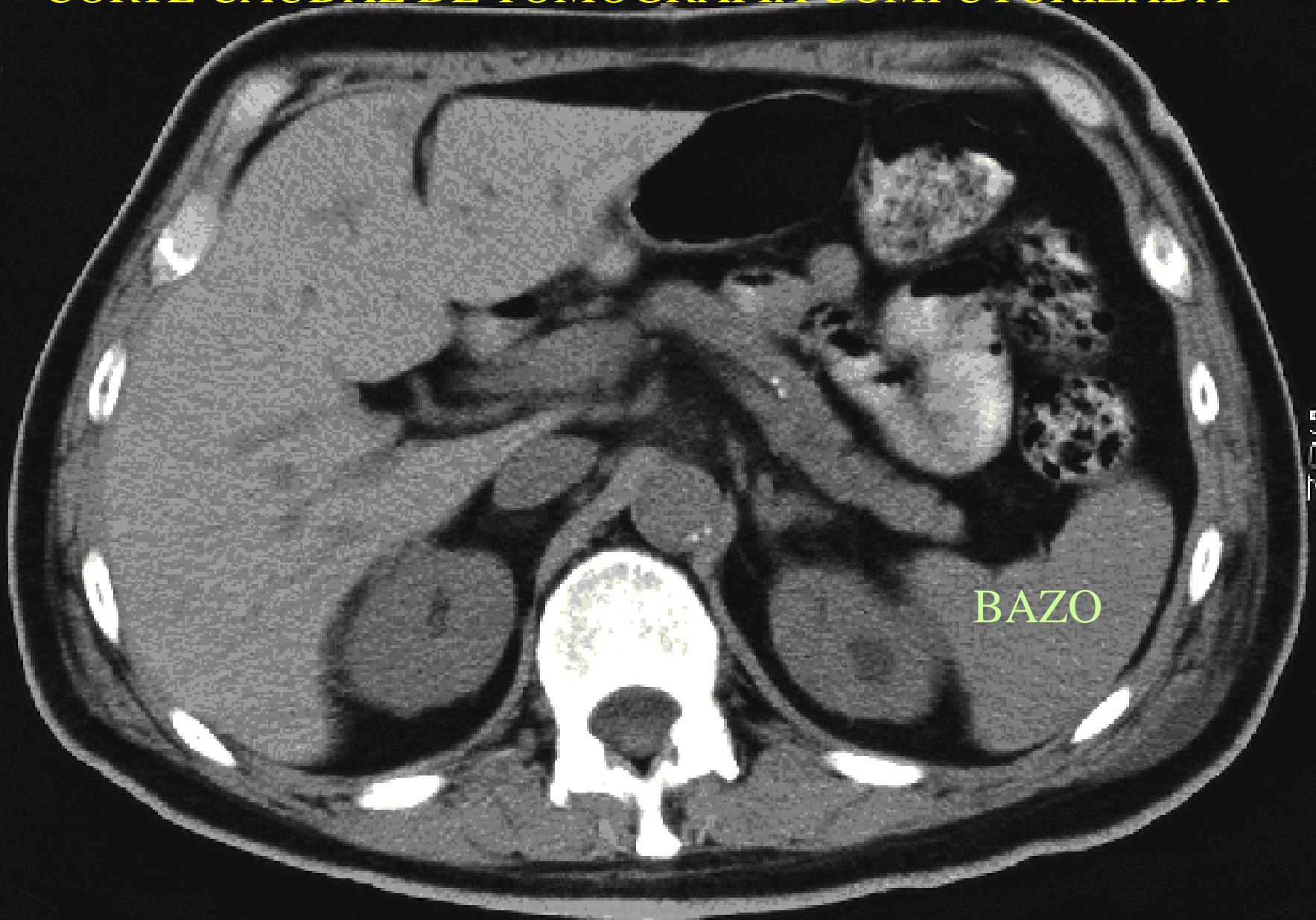


0102

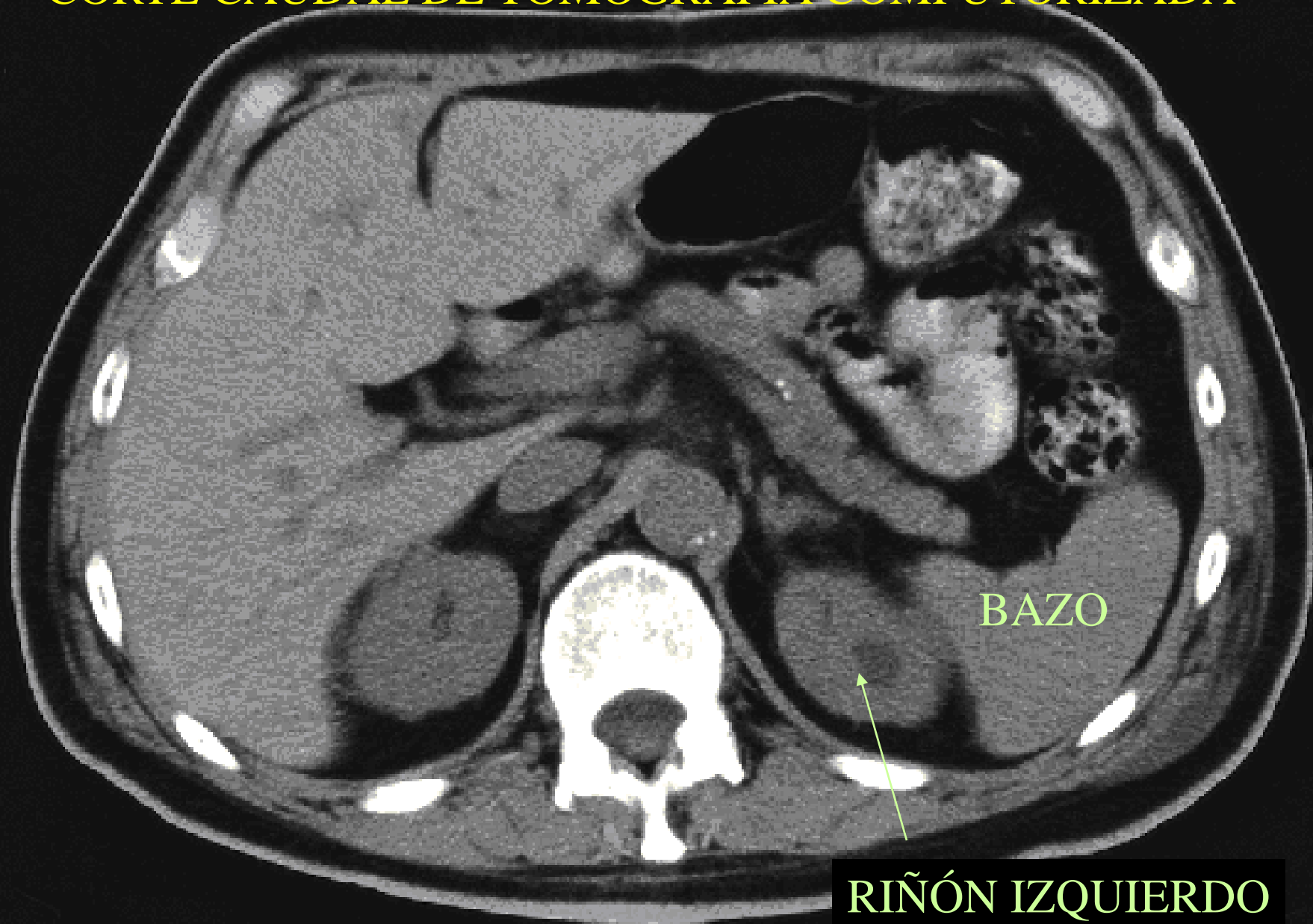
CORTE CAUDAL DE TOMOGRAFIA COMPUTORIZADA



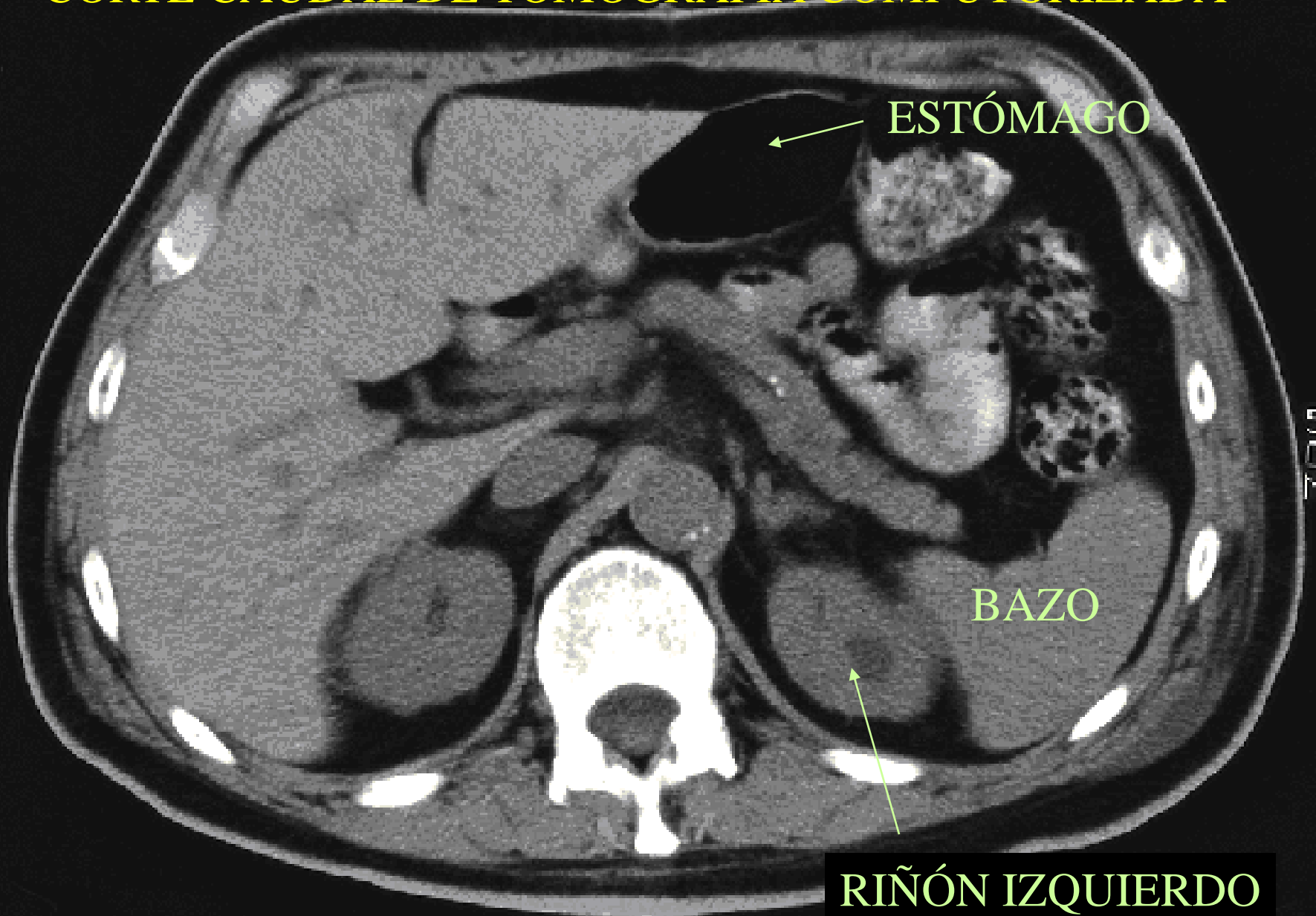
CORTE CAUDAL DE TOMOGRAFIA COMPUTORIZADA



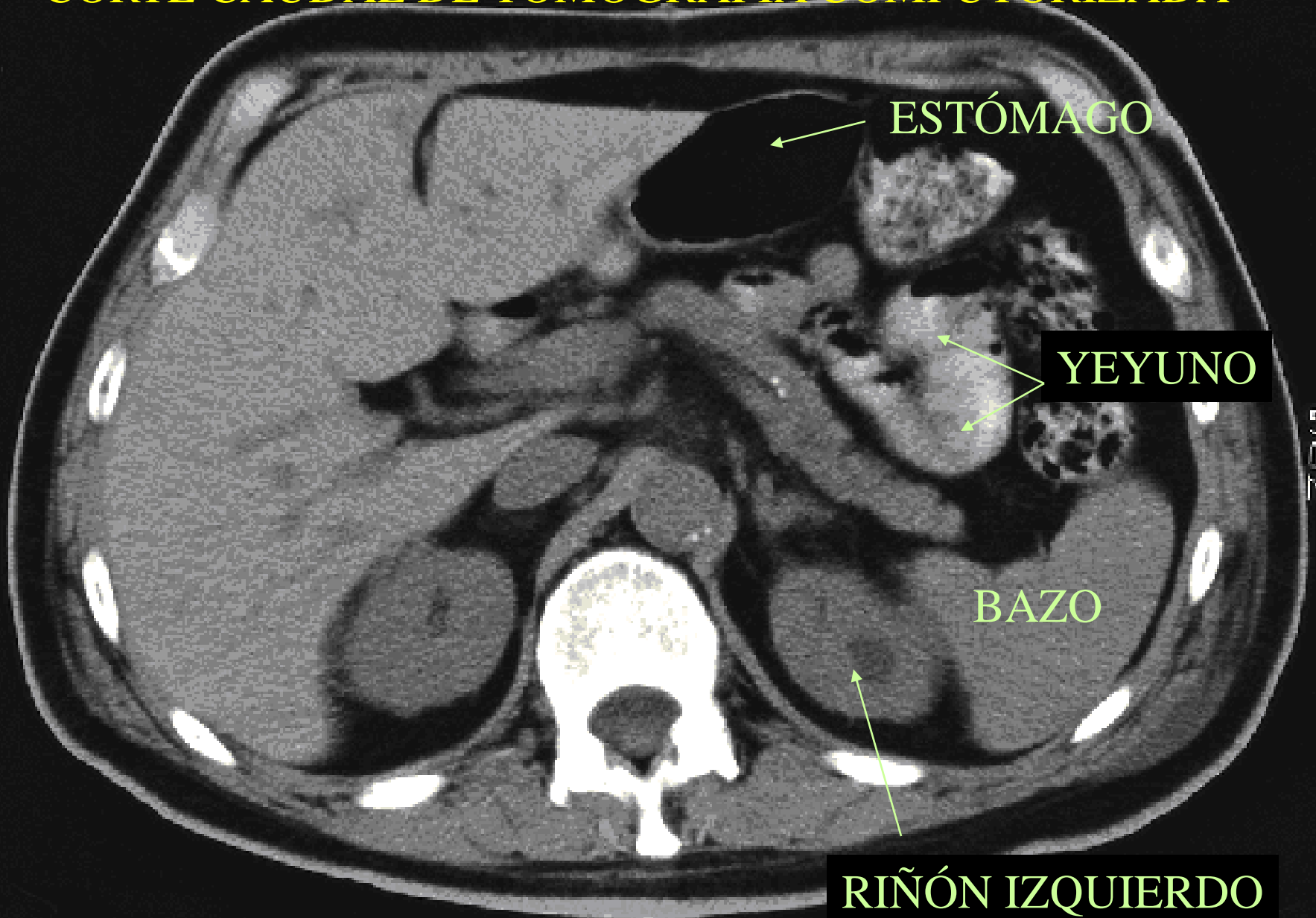
CORTE CAUDAL DE TOMOGRAFIA COMPUTORIZADA



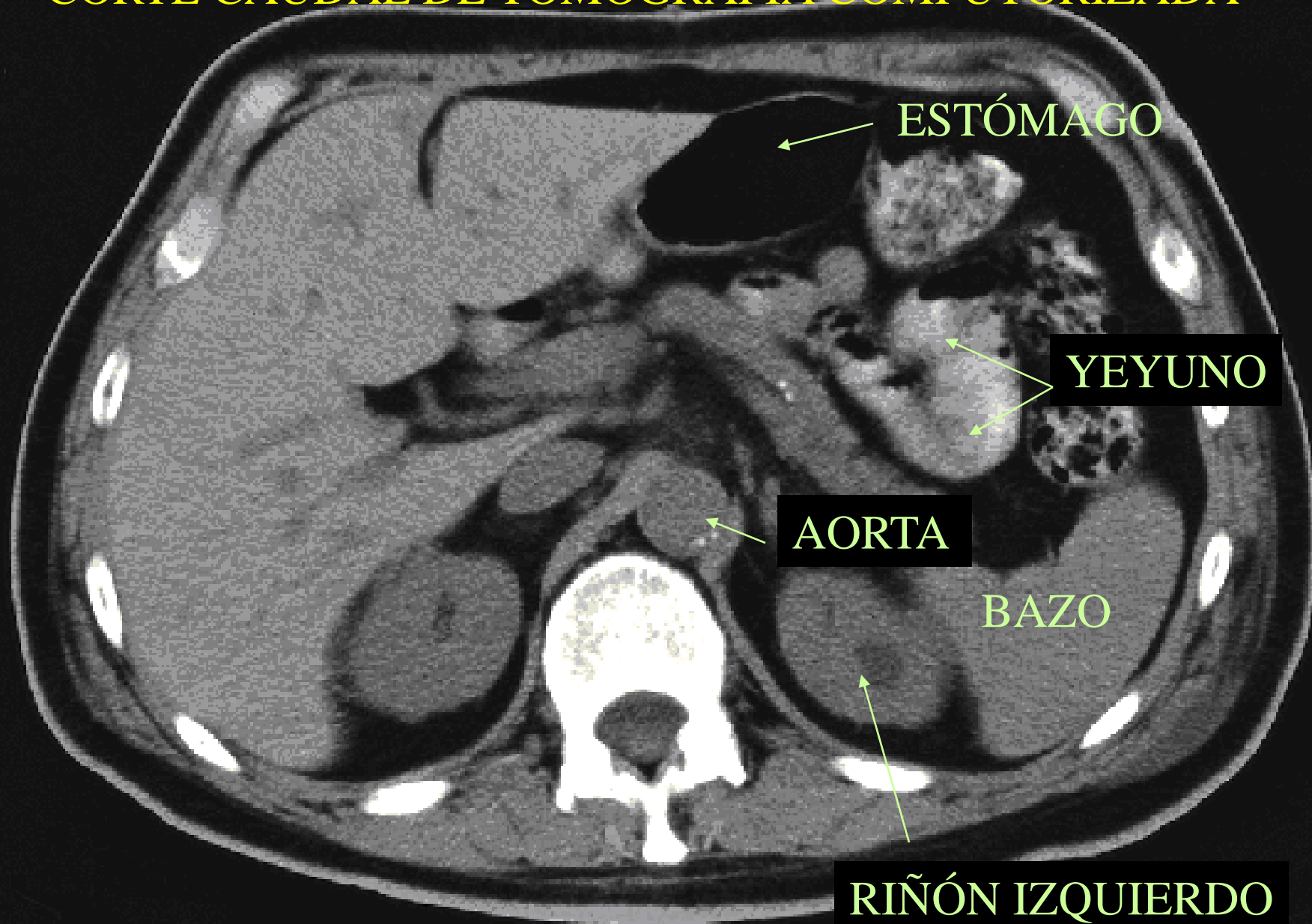
CORTE CAUDAL DE TOMOGRAFIA COMPUTORIZADA



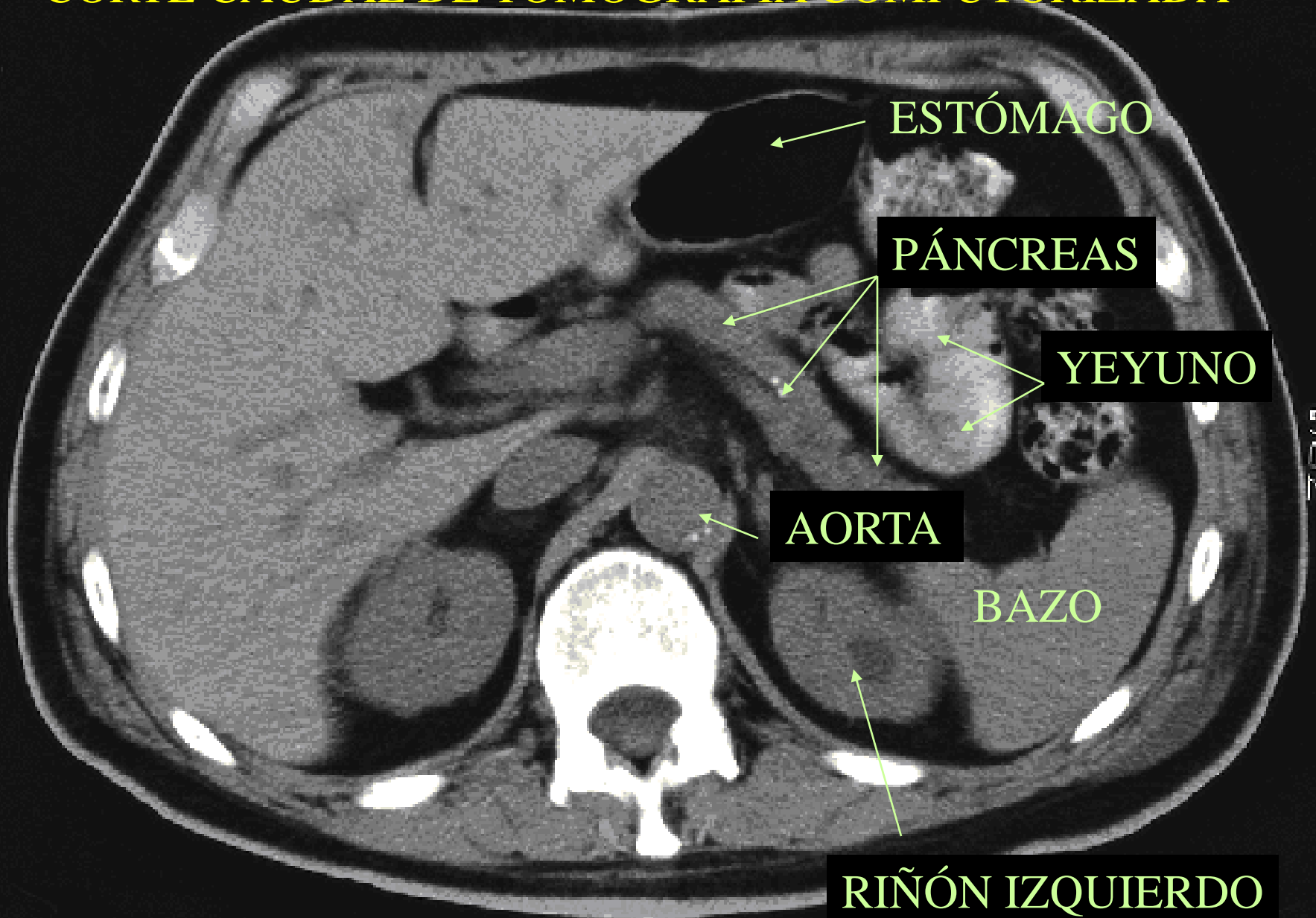
CORTE CAUDAL DE TOMOGRAFIA COMPUTORIZADA



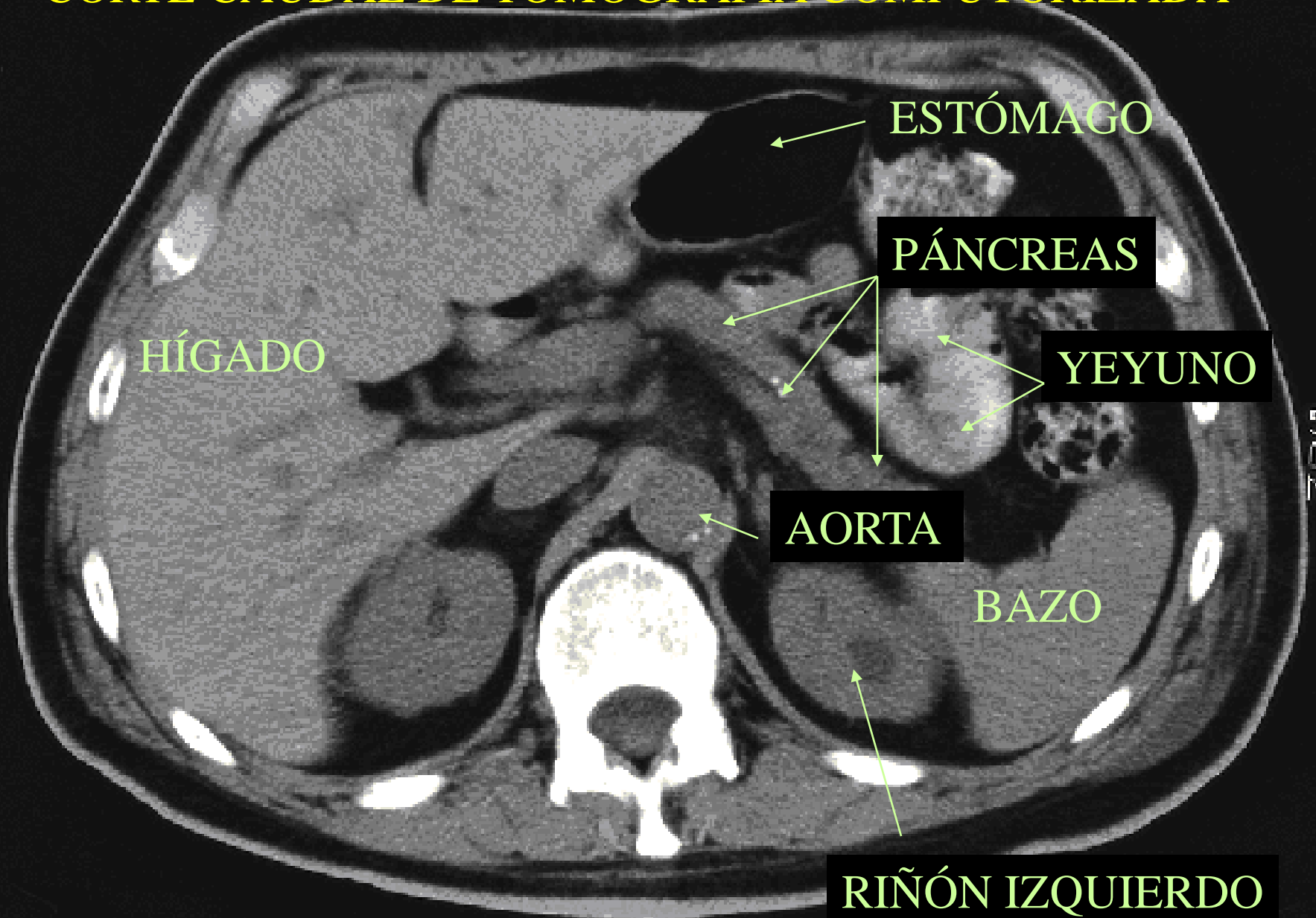
CORTE CAUDAL DE TOMOGRAFIA COMPUTORIZADA



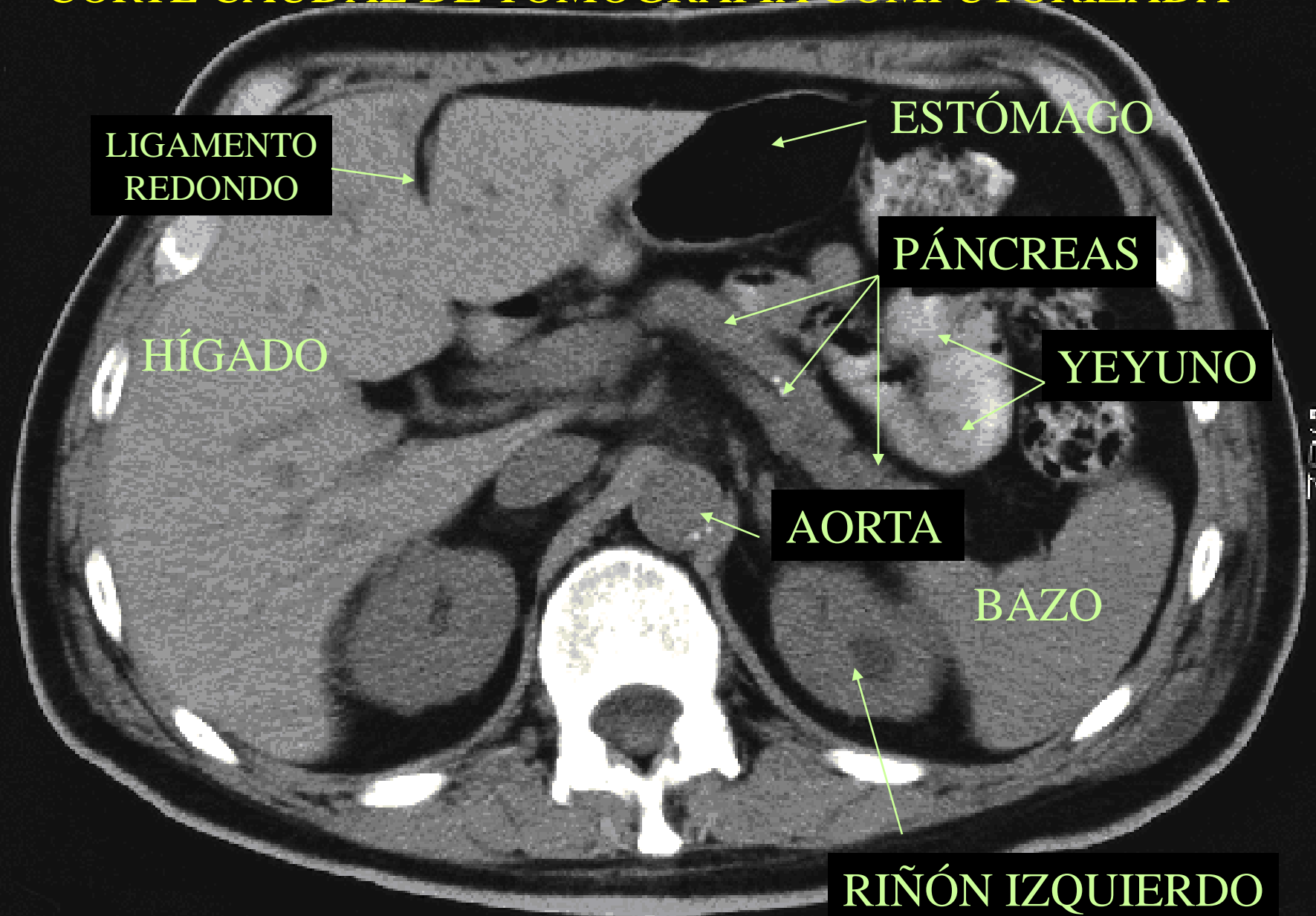
CORTE CAUDAL DE TOMOGRAFIA COMPUTORIZADA



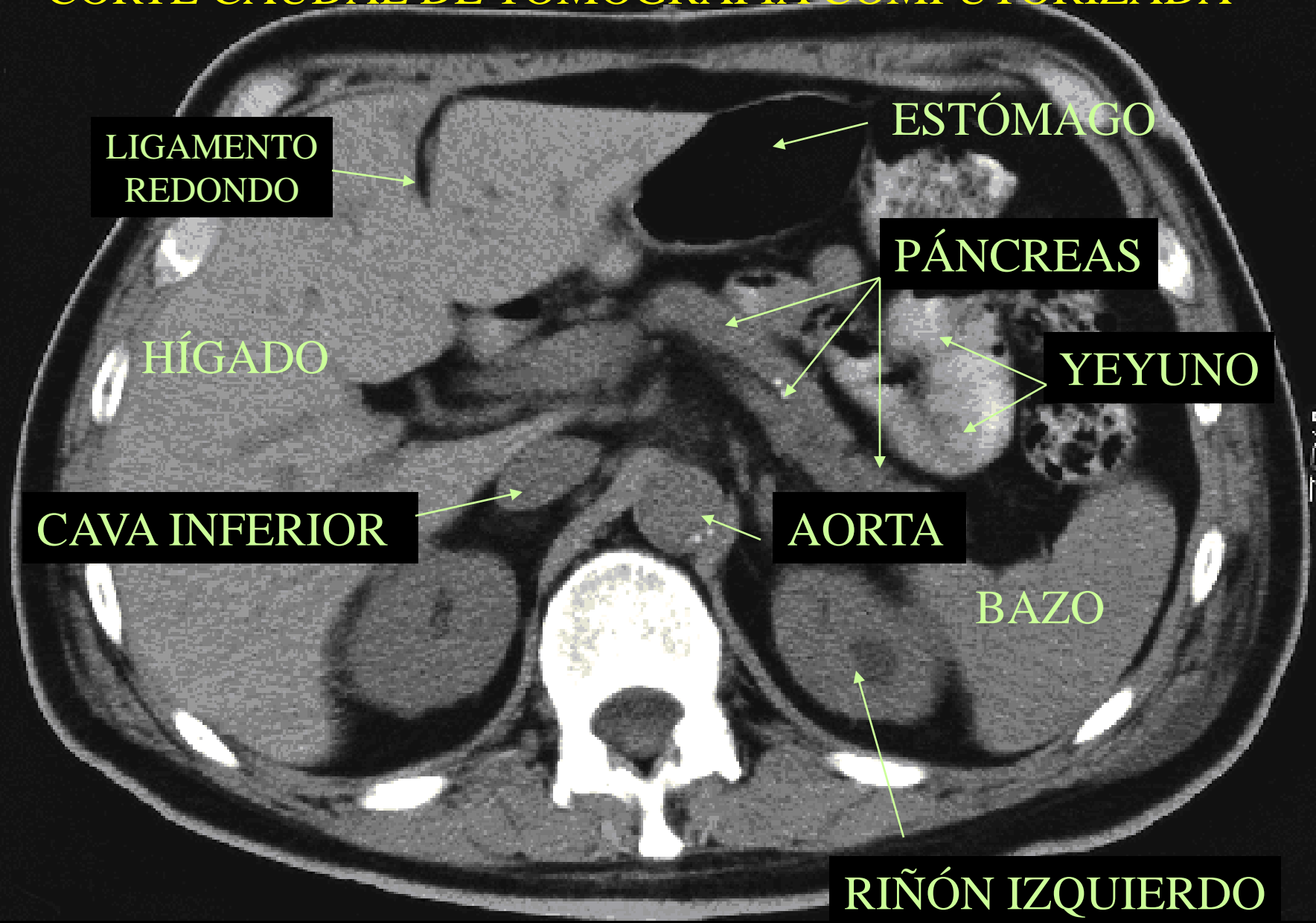
CORTE CAUDAL DE TOMOGRAFIA COMPUTORIZADA



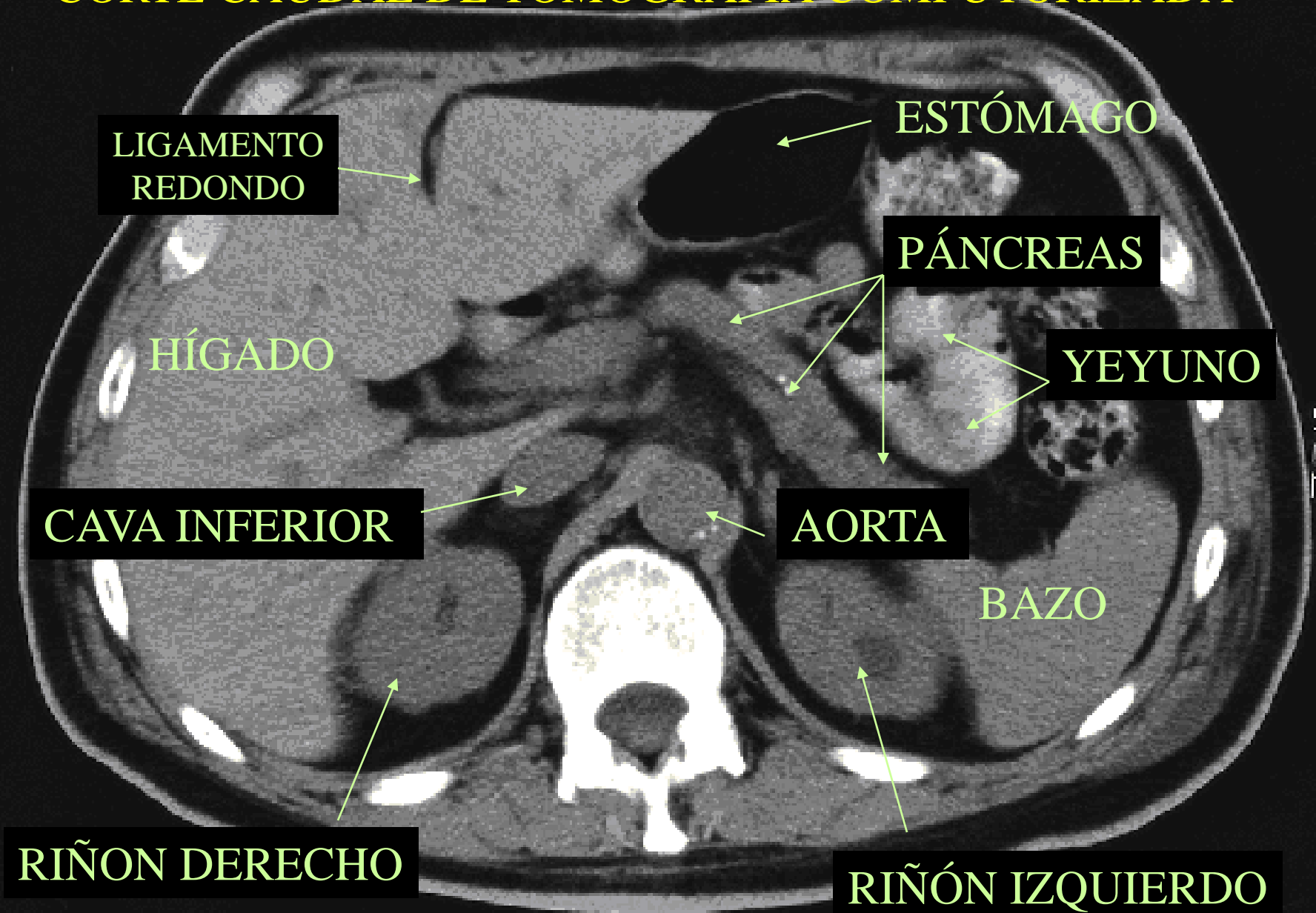
CORTE CAUDAL DE TOMOGRAFIA COMPUTORIZADA

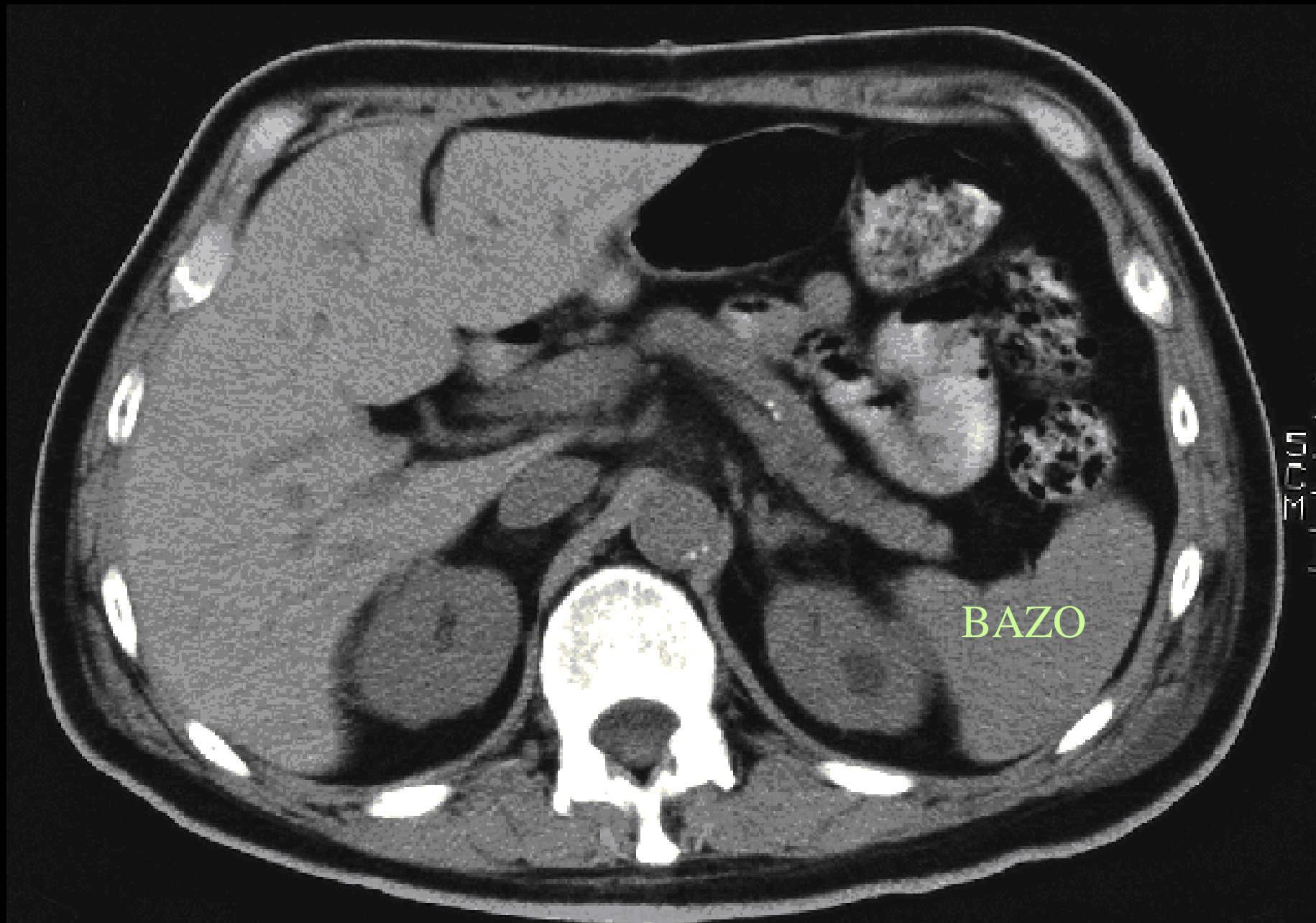


CORTE CAUDAL DE TOMOGRAFIA COMPUTORIZADA



CORTE CAUDAL DE TOMOGRAFIA COMPUTORIZADA

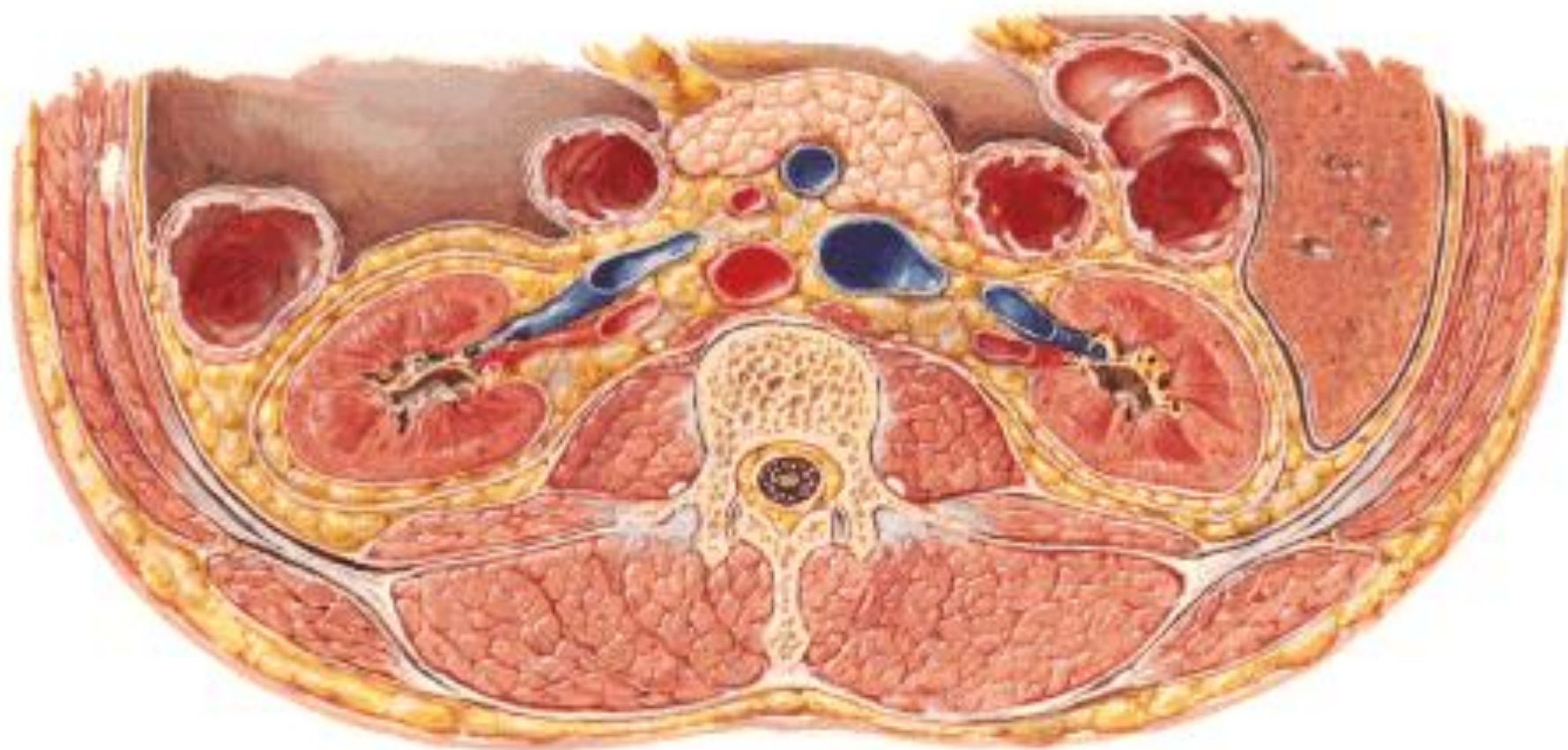




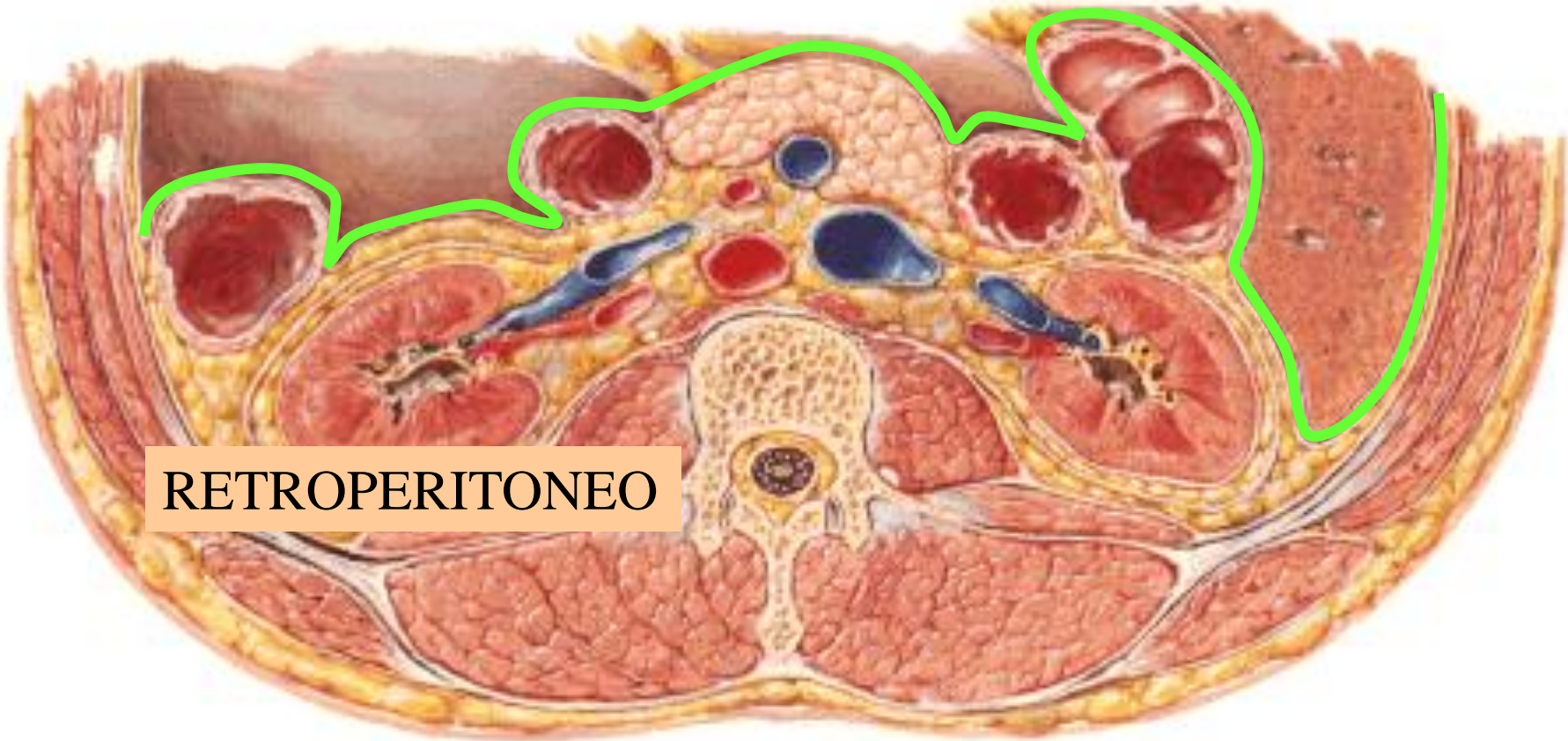
BAZO

0125

Corte transverso horizontal a nivel de la 2ª vértebra lumbar

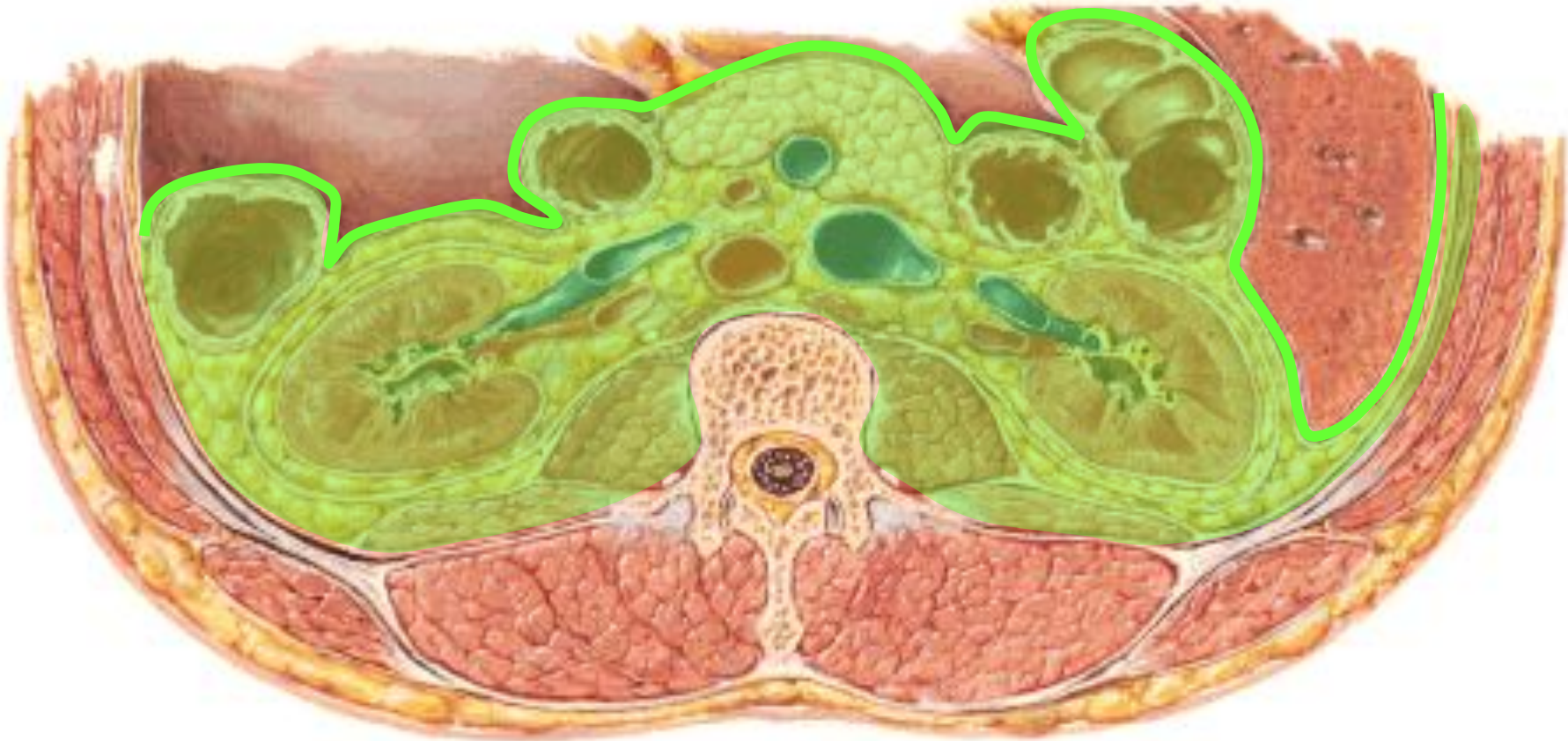


Corte craneal transverso horizontal a nivel de la 2ª vértebra lumbar

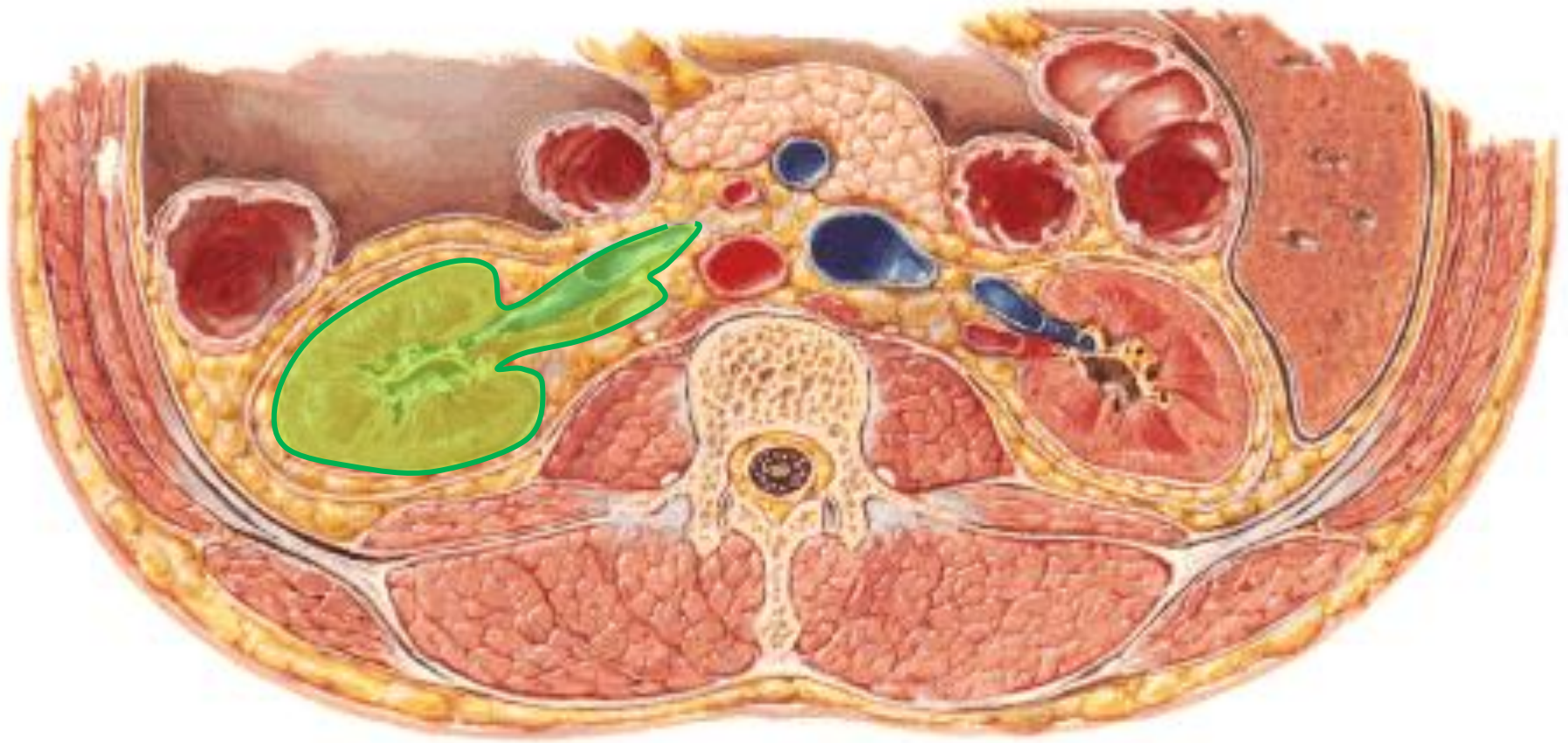


RETROPERITONEO

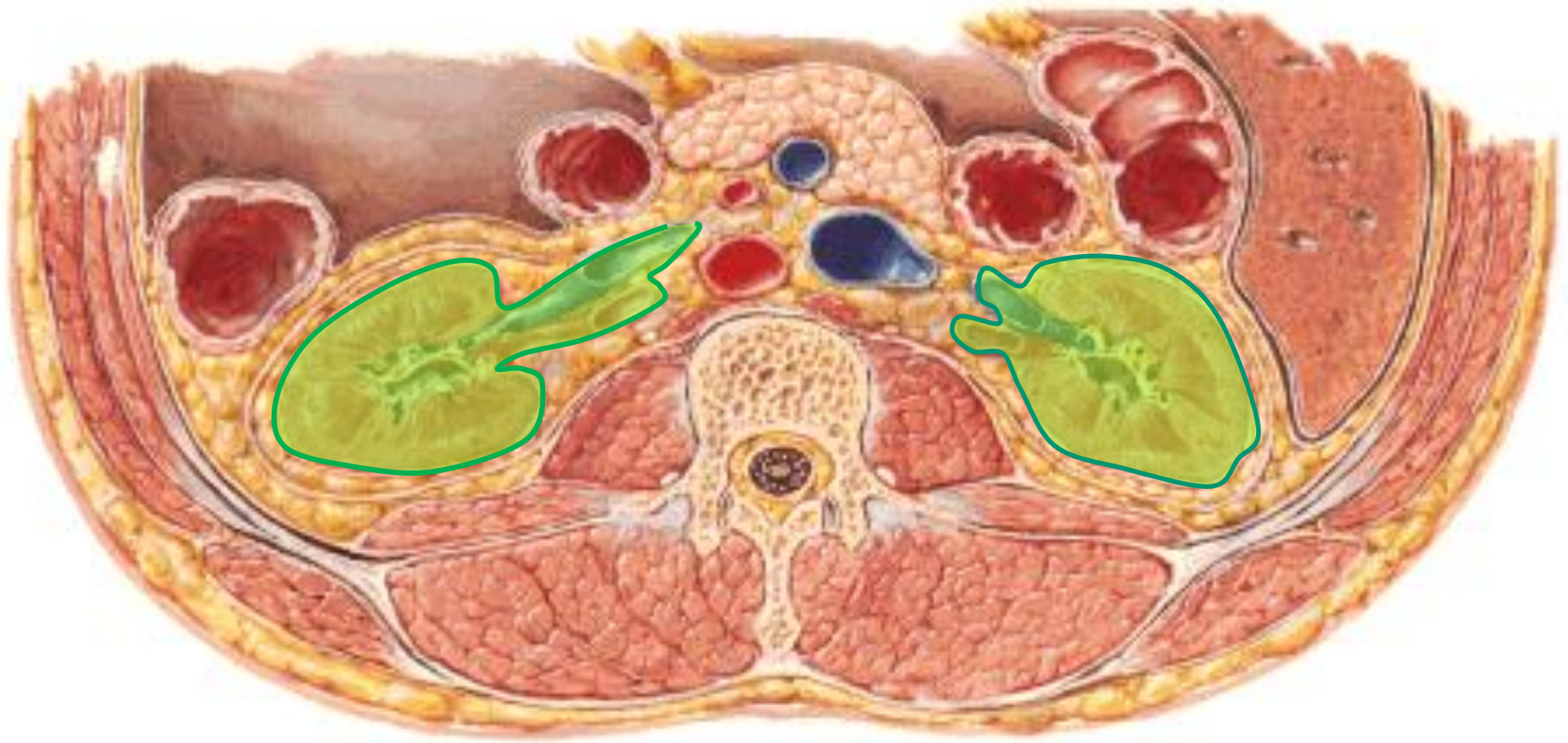
Corte craneal transverso horizontal a nivel de la 2ª vértebra lumbar



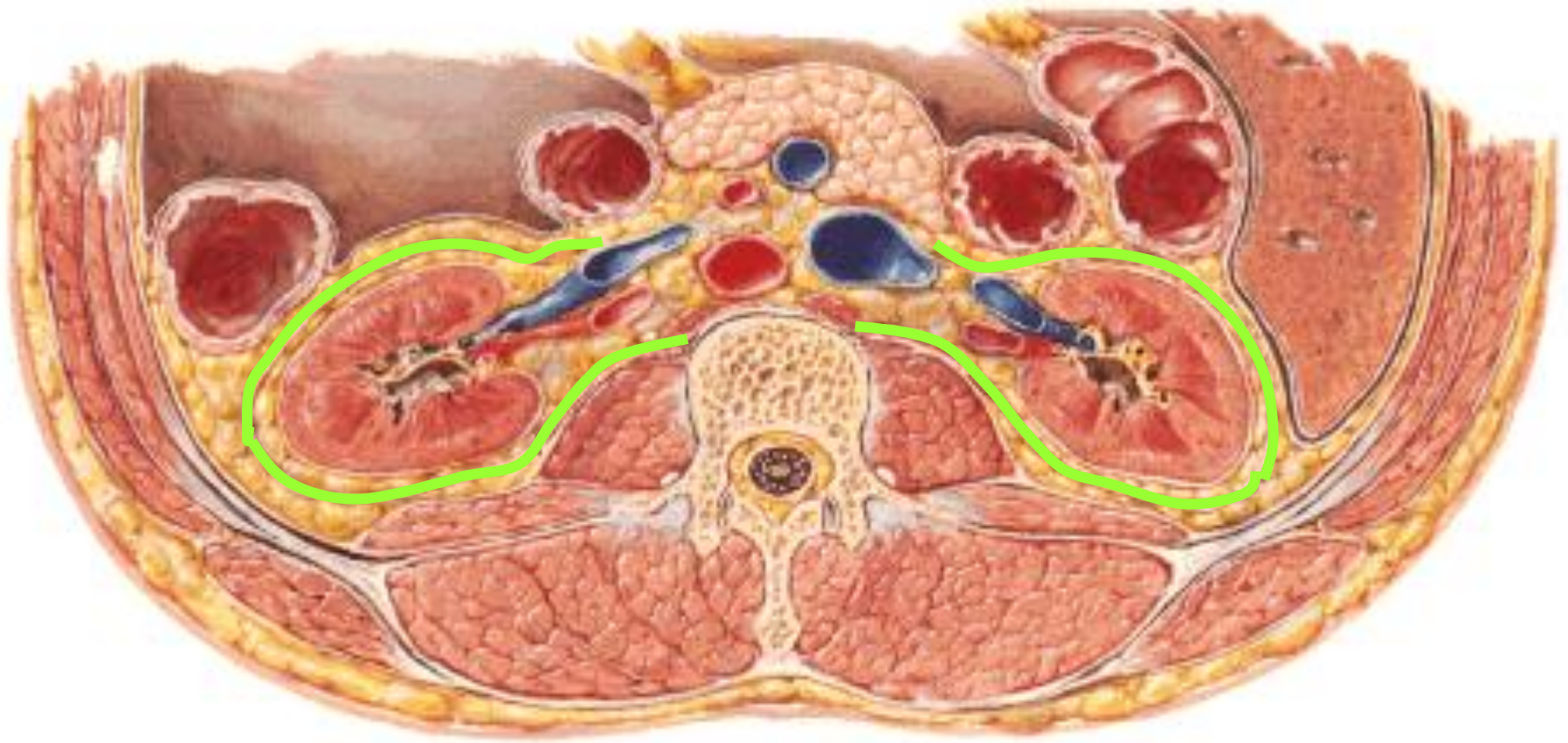
RIÑÓN IZQUIERDO



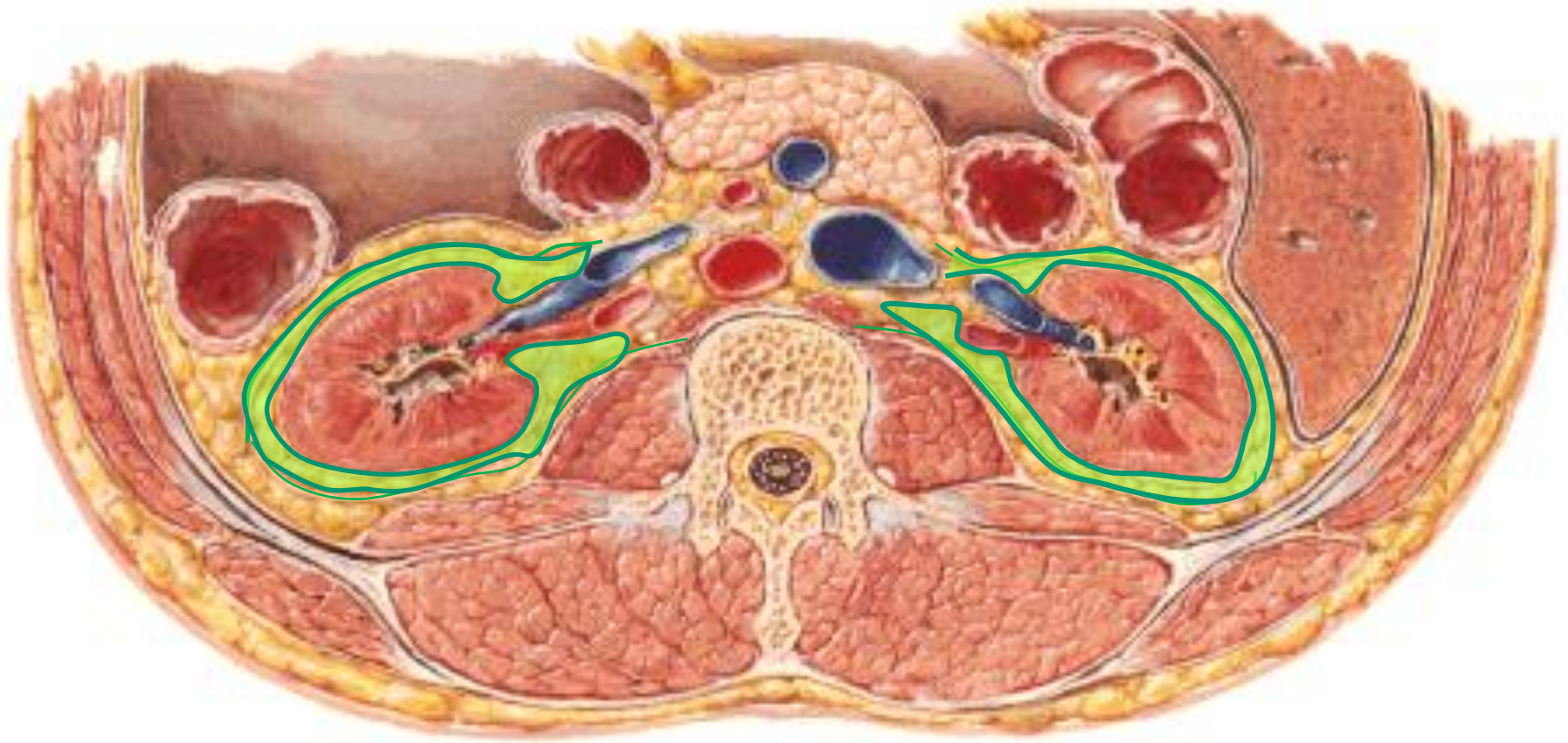
RIÑONES (ARTERIAS Y VENAS RENALES)



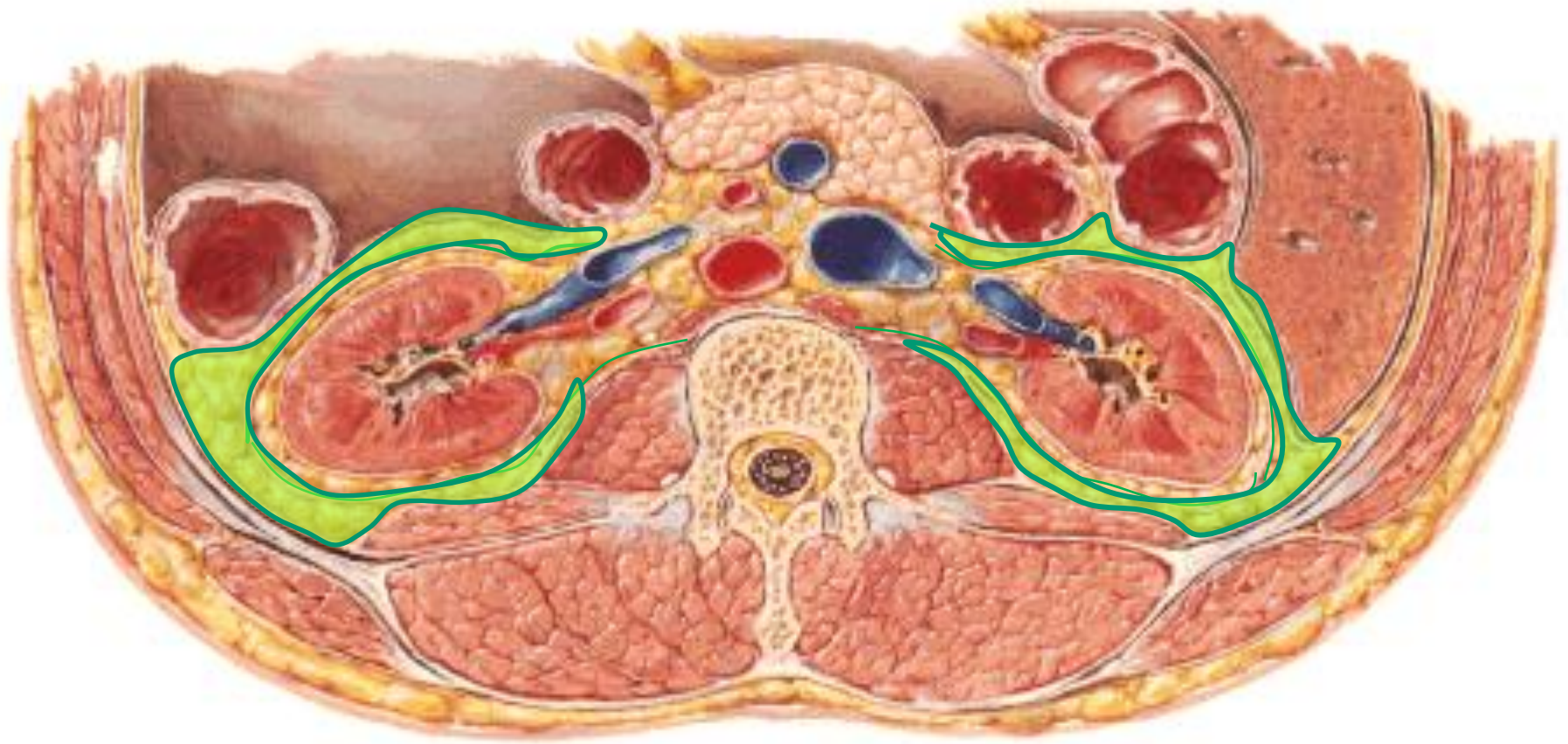
CELDA RENAL



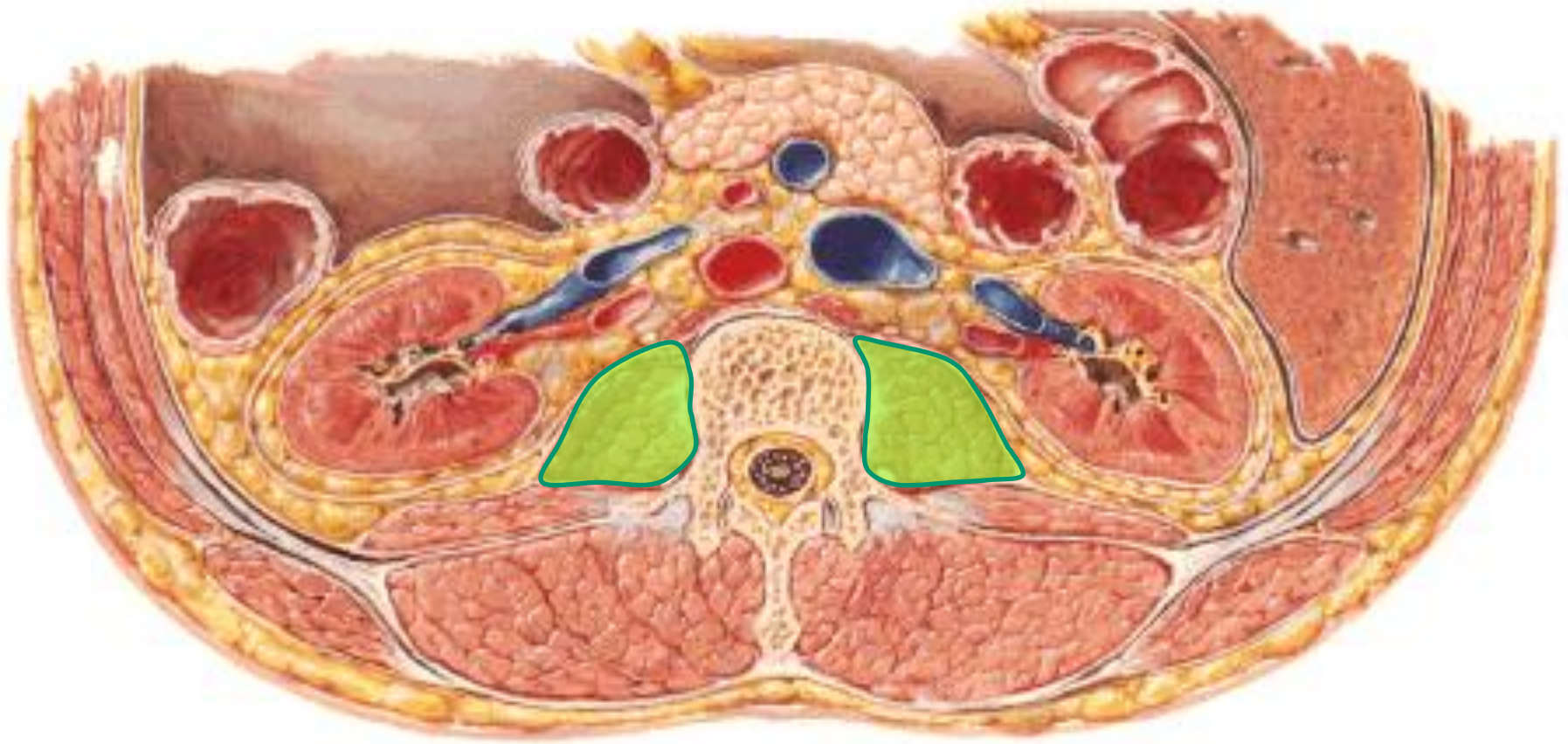
GRASA PERIRRENAL



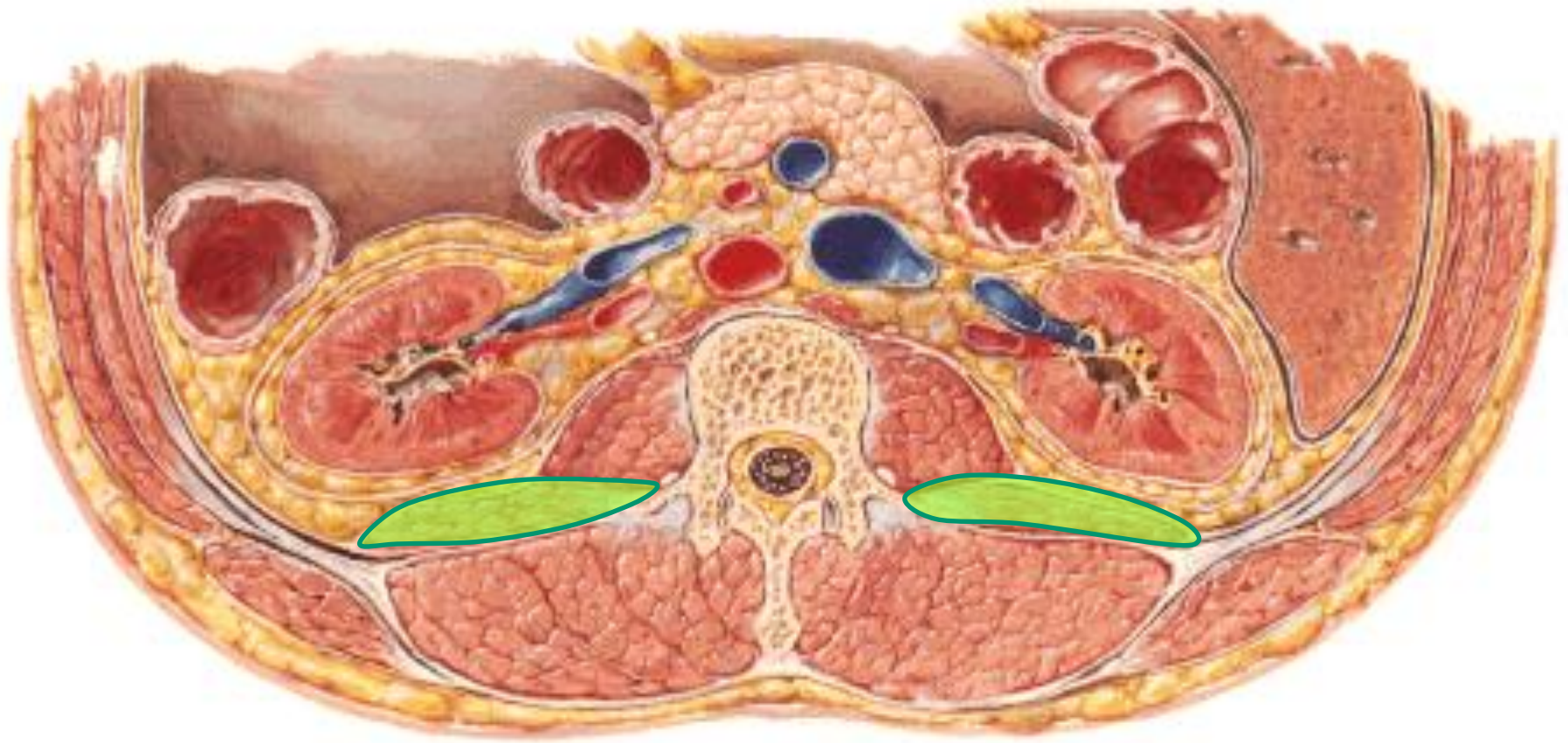
GRASA PARARRENAL



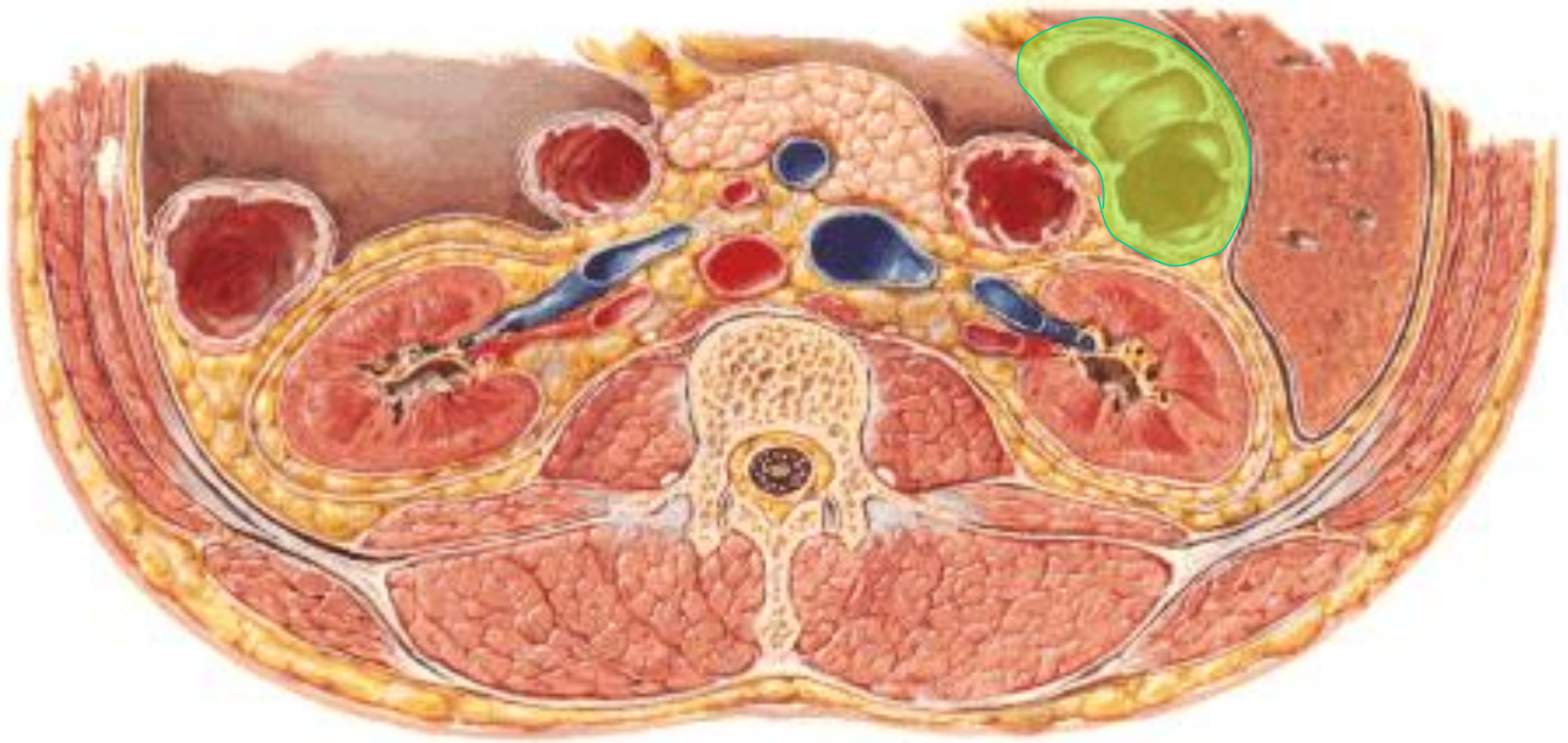
MÚSCULO PSOAS



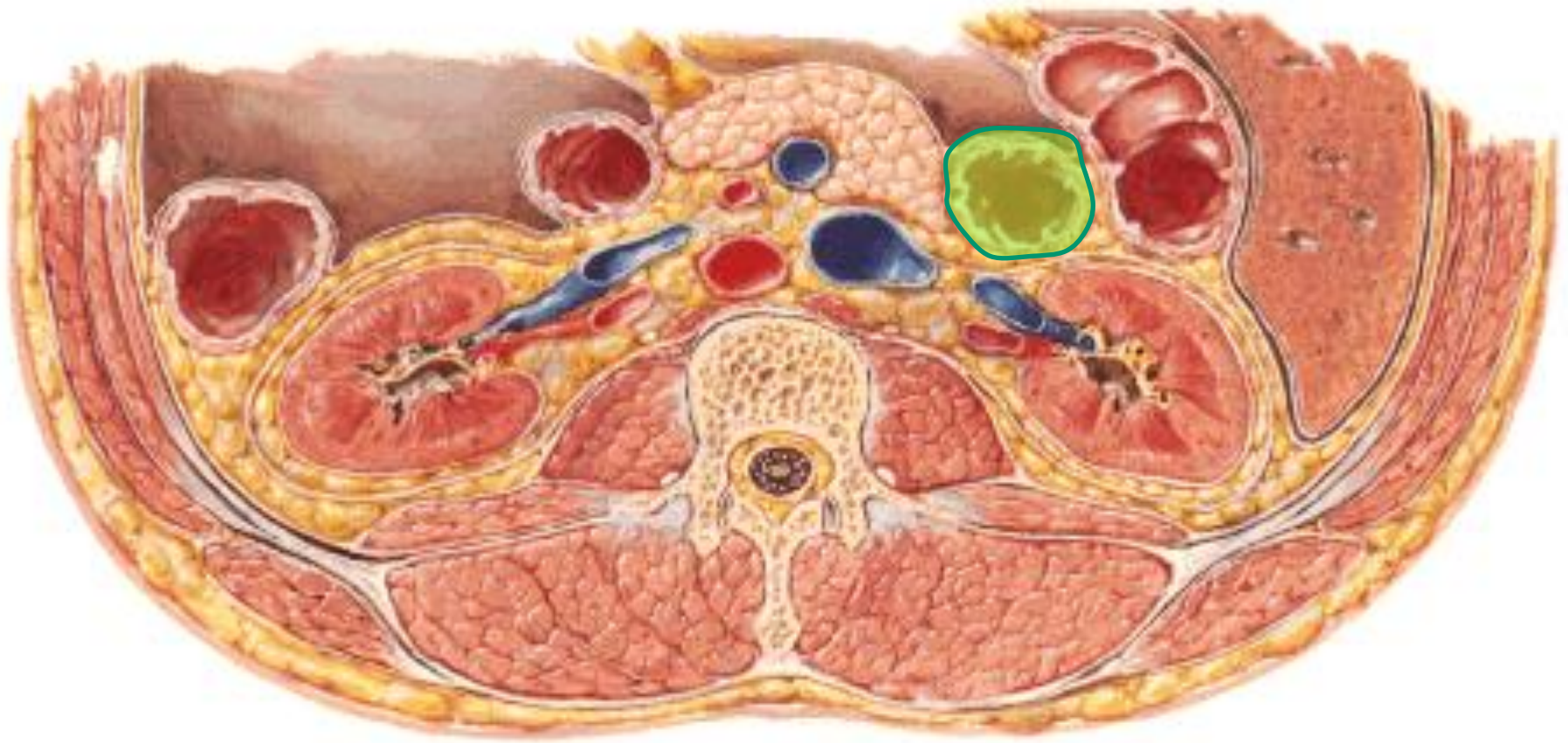
MÚSCULO CUADRADO LUMBAR



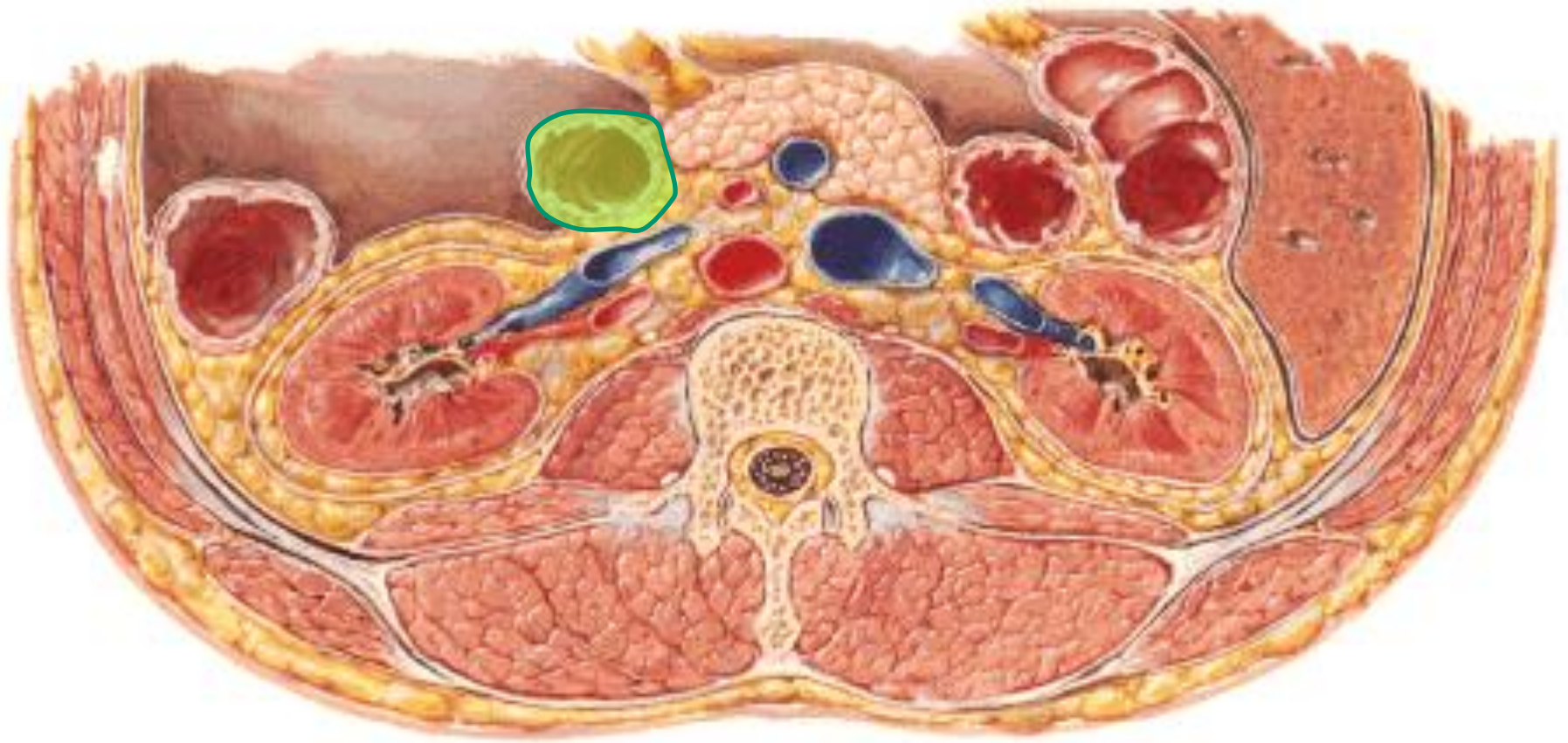
ÁNGULO HEPÁTICO DEL COLON



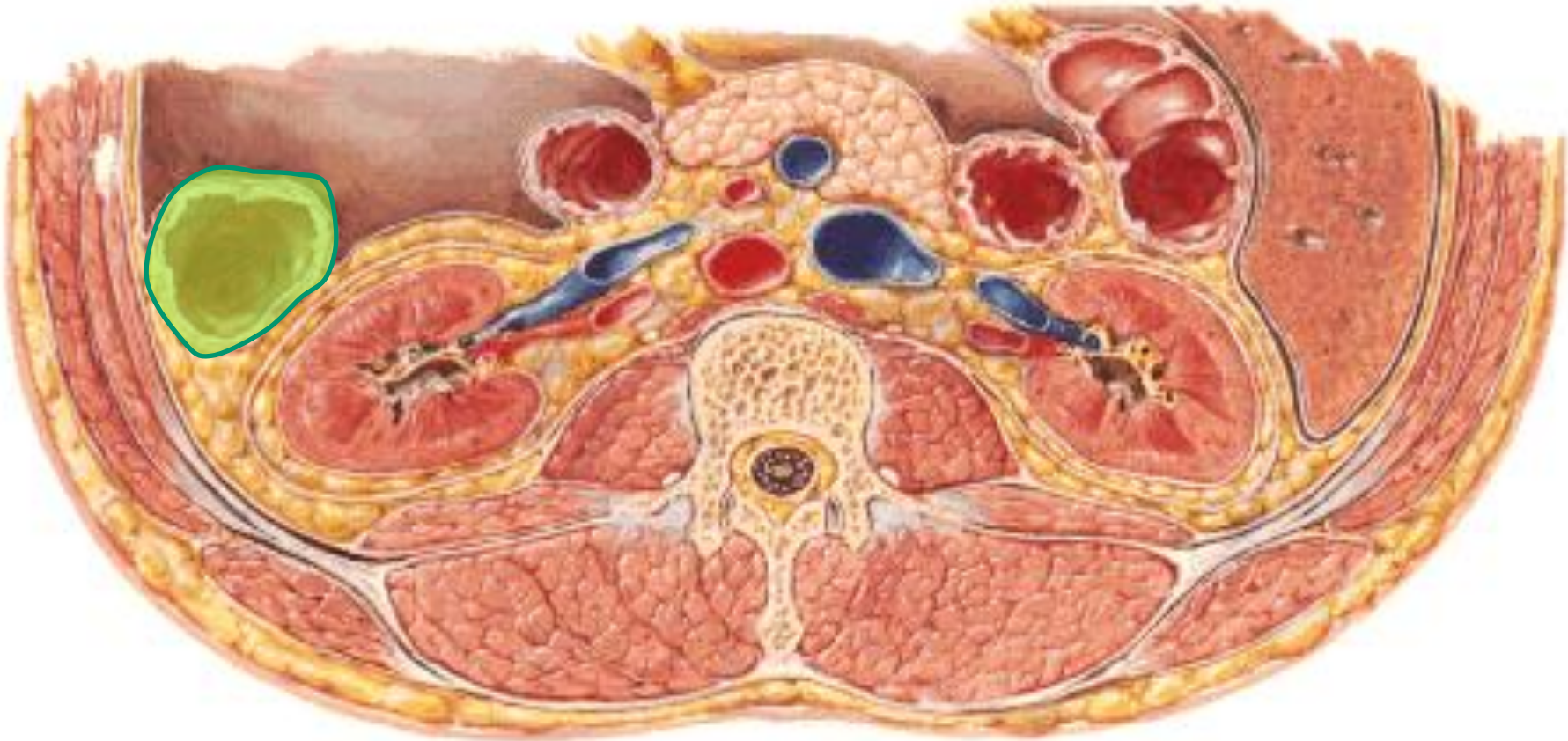
2ª PORCIÓN O PORCIÓN DESCENDENTE DEL DUODENO

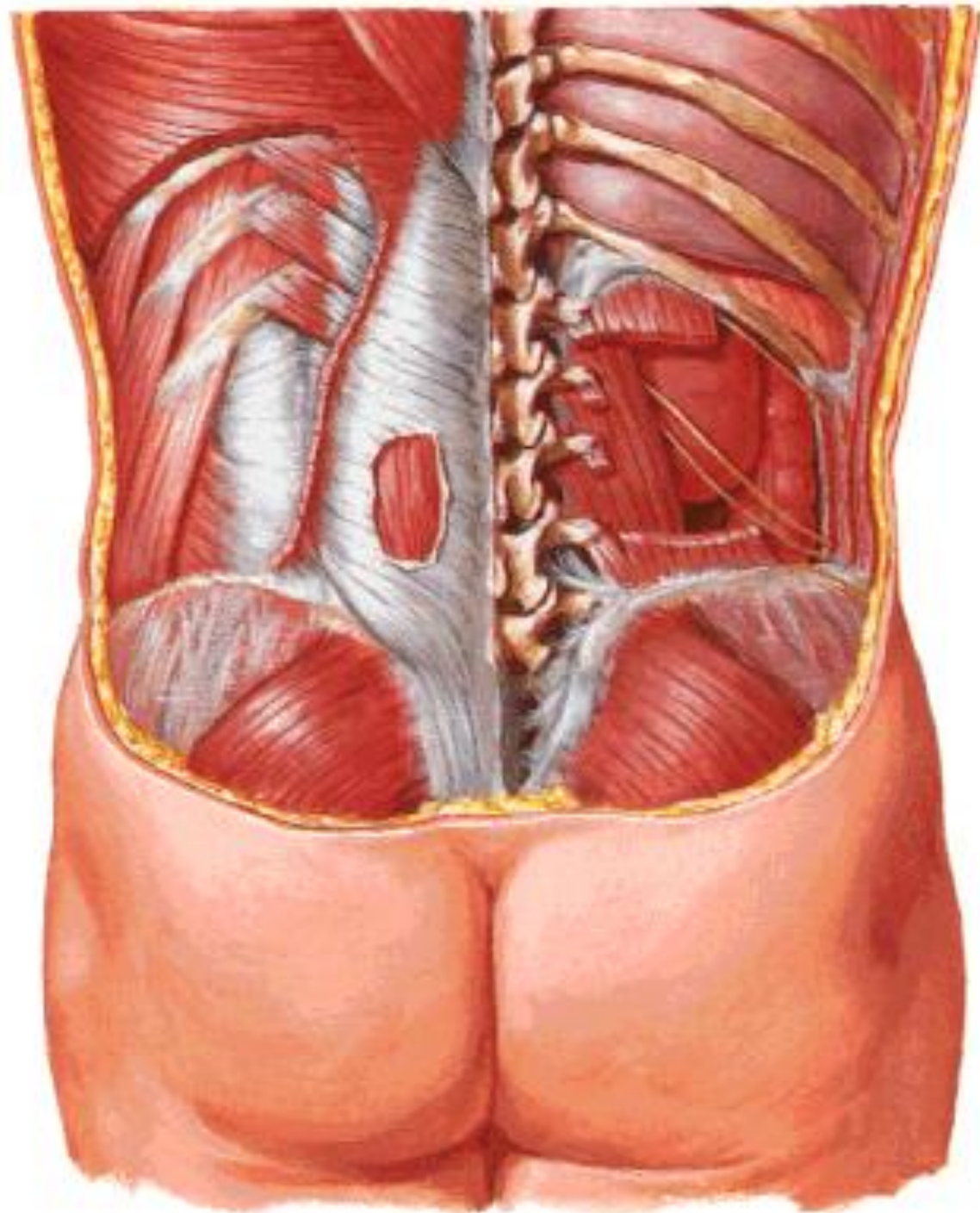


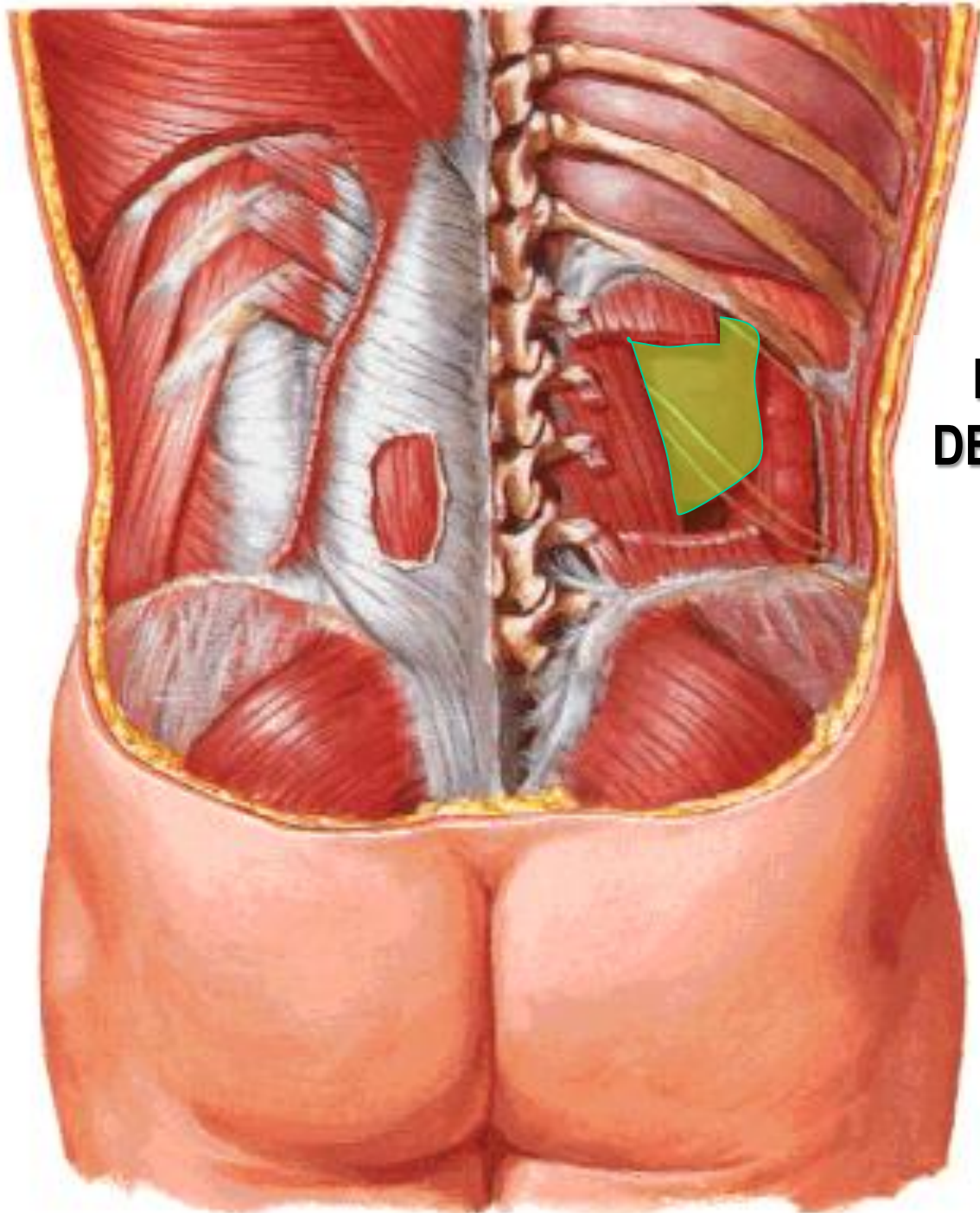
ÁNGULO DUODENOYEURYUNAL



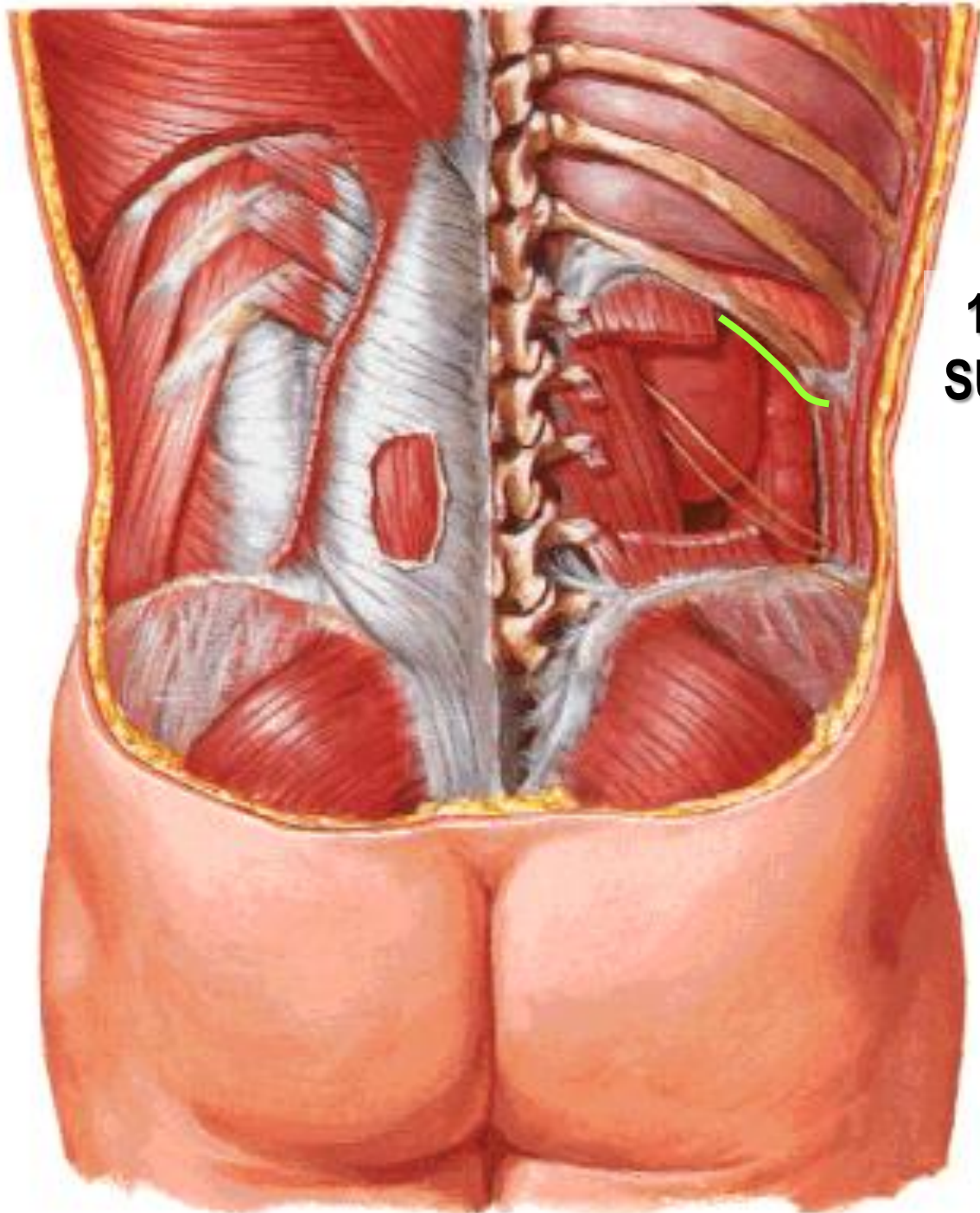
COLON DESCENDENTE





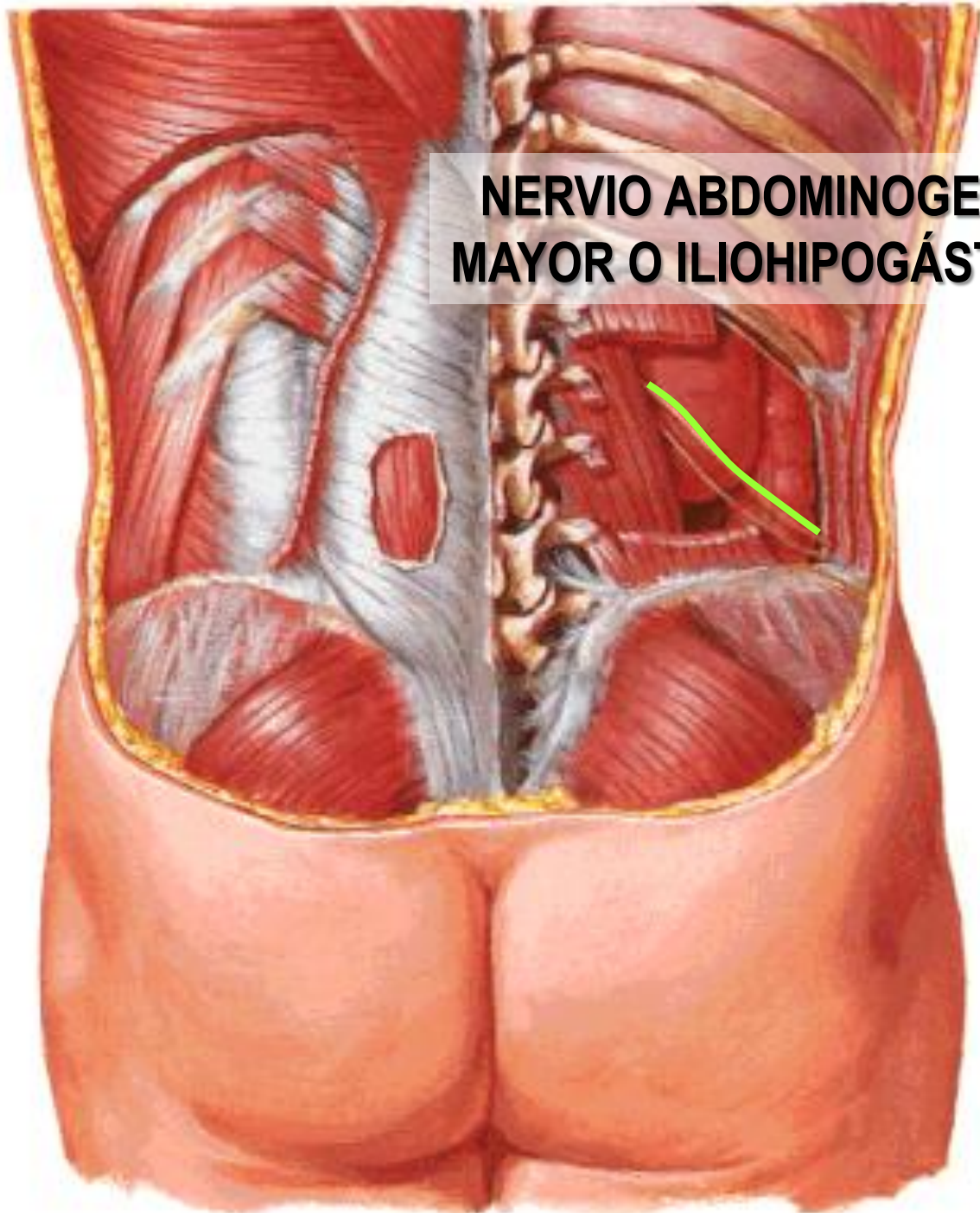


**RIÑÓN
DERECHO**

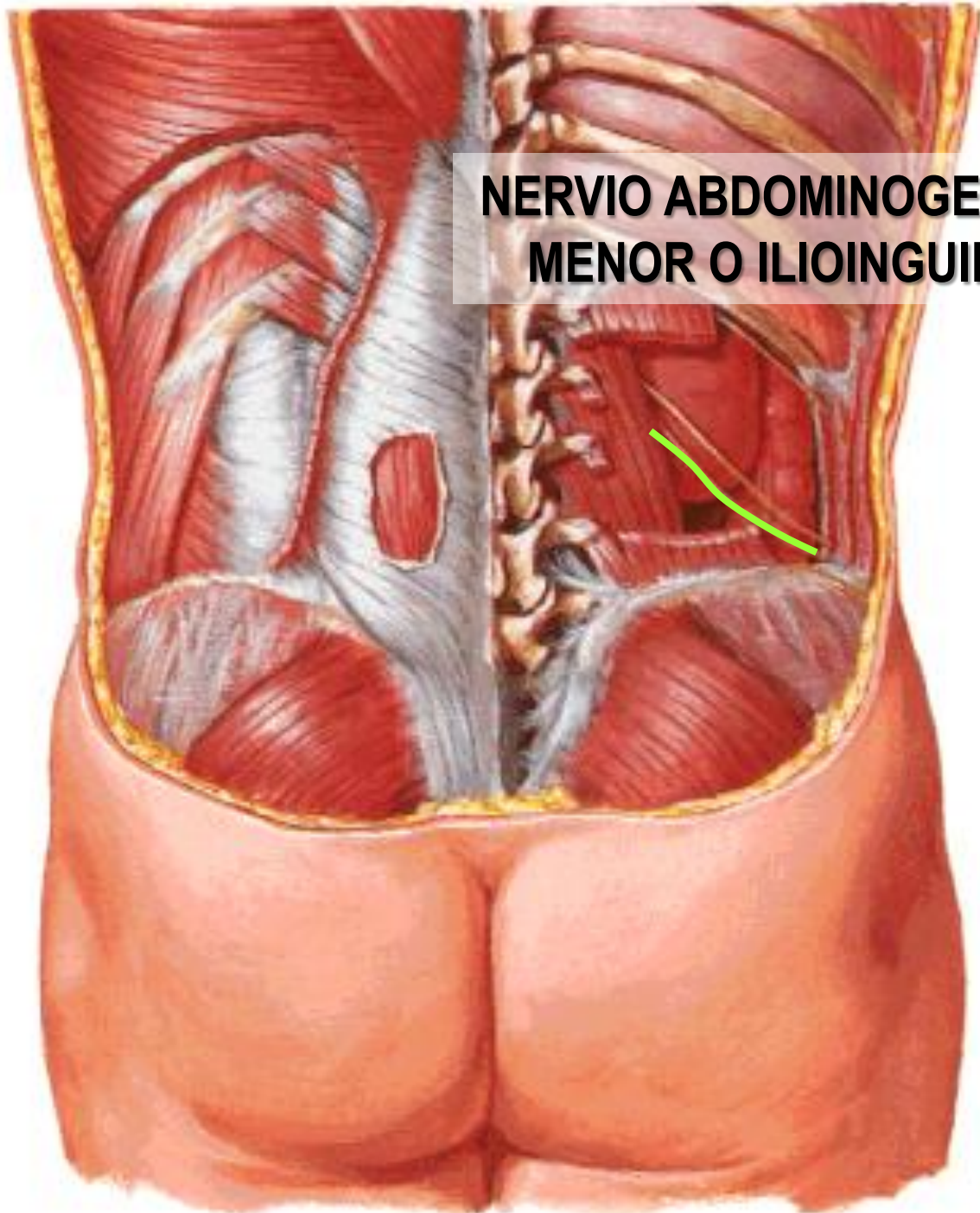


**12 NERVIO
SUBCOSTAL**

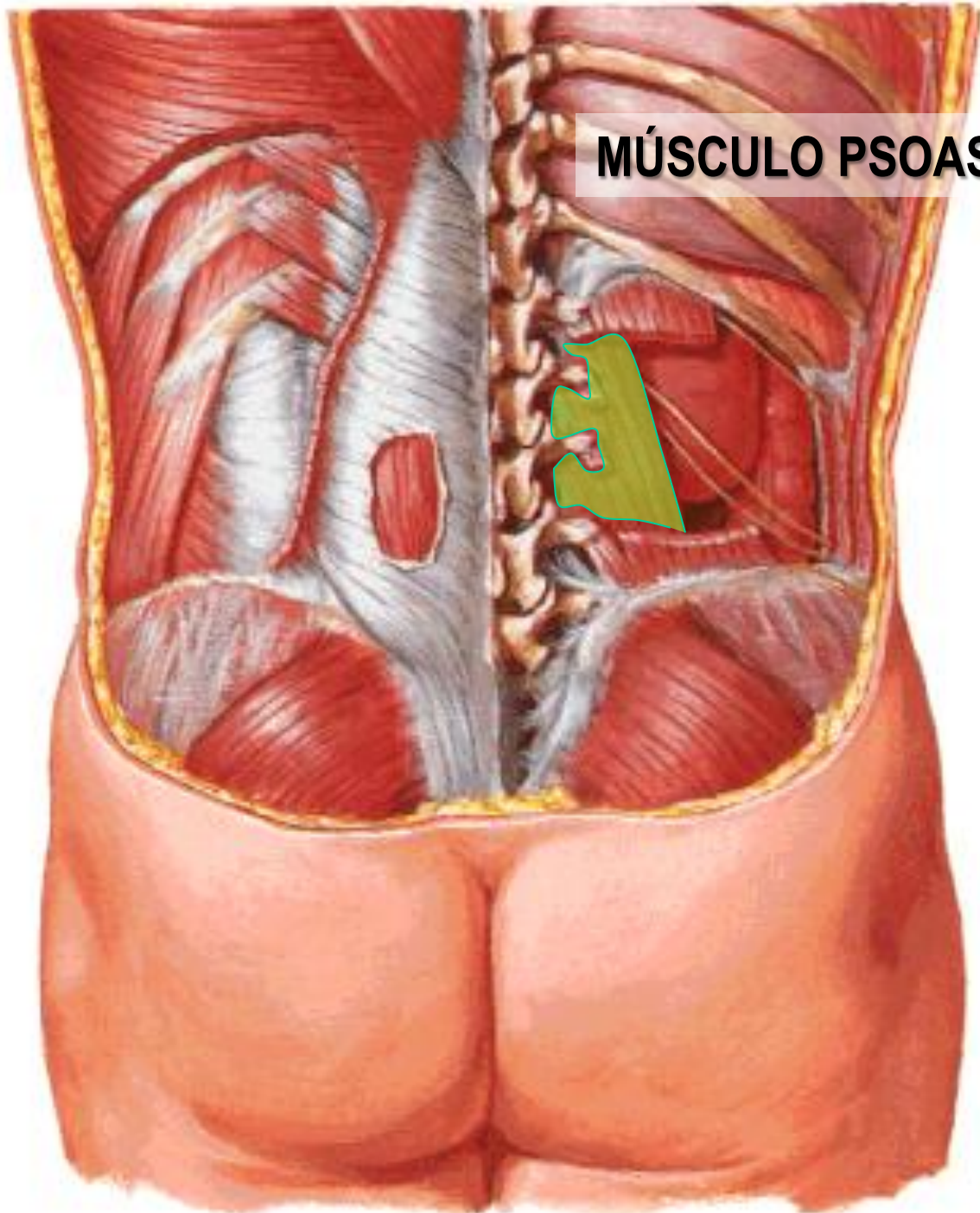
**NERVIO ABDOMINOGENITAL
MAYOR O ILIOHIPOGÁSTRICO**



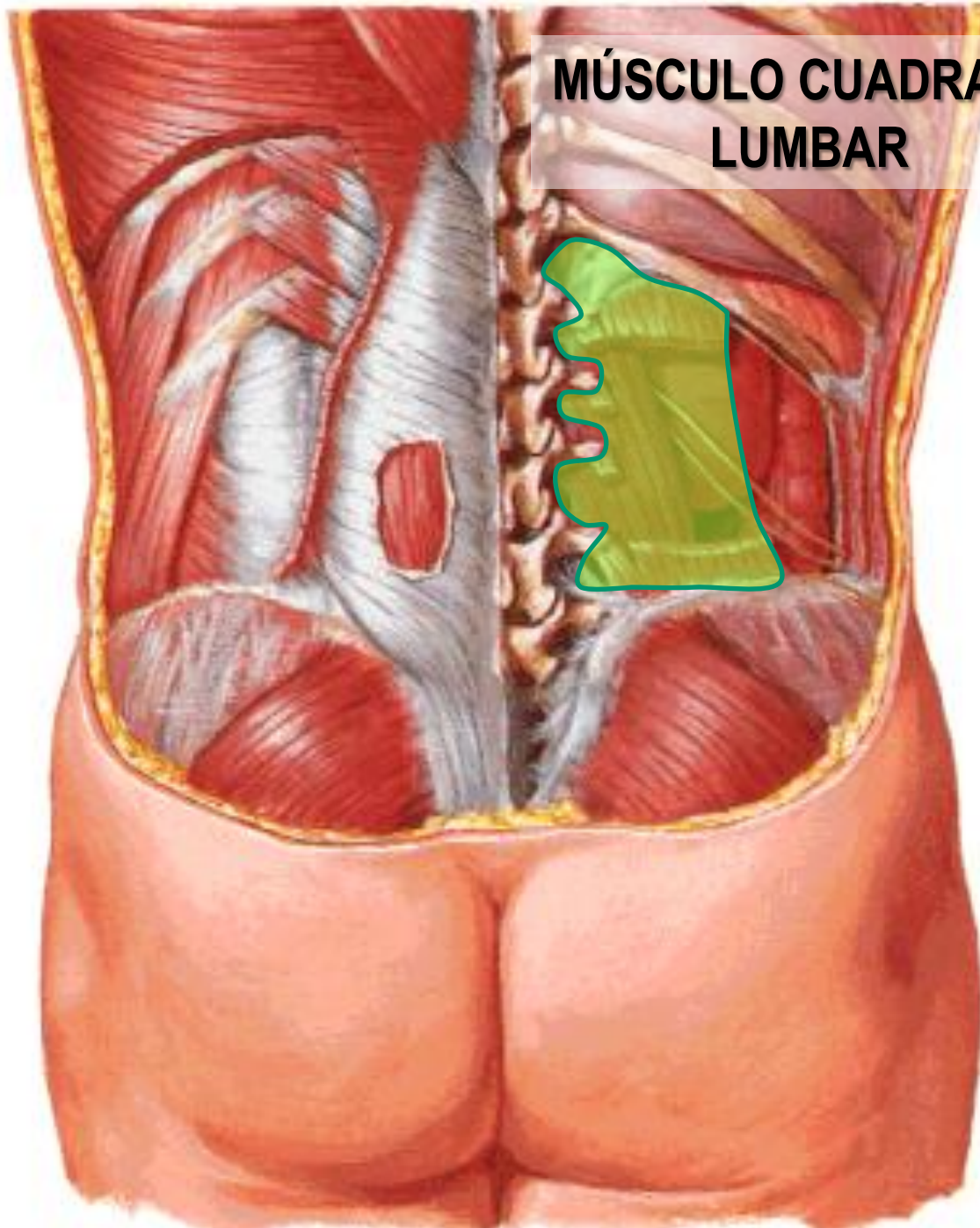
**NERVIO ABDOMINOGENITAL
MENOR O ILIOINGUINAL**



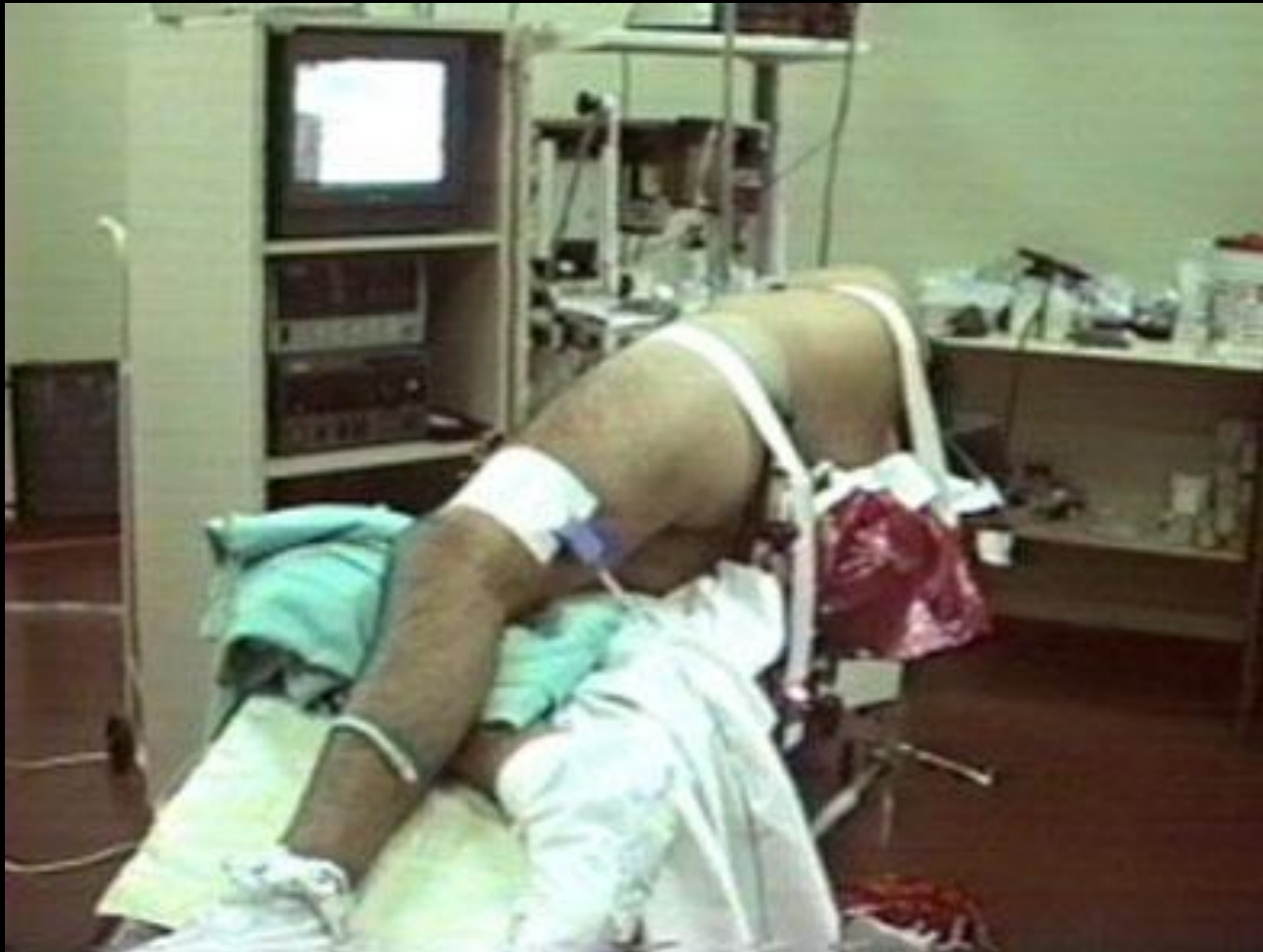MÚSCULO PSOAS



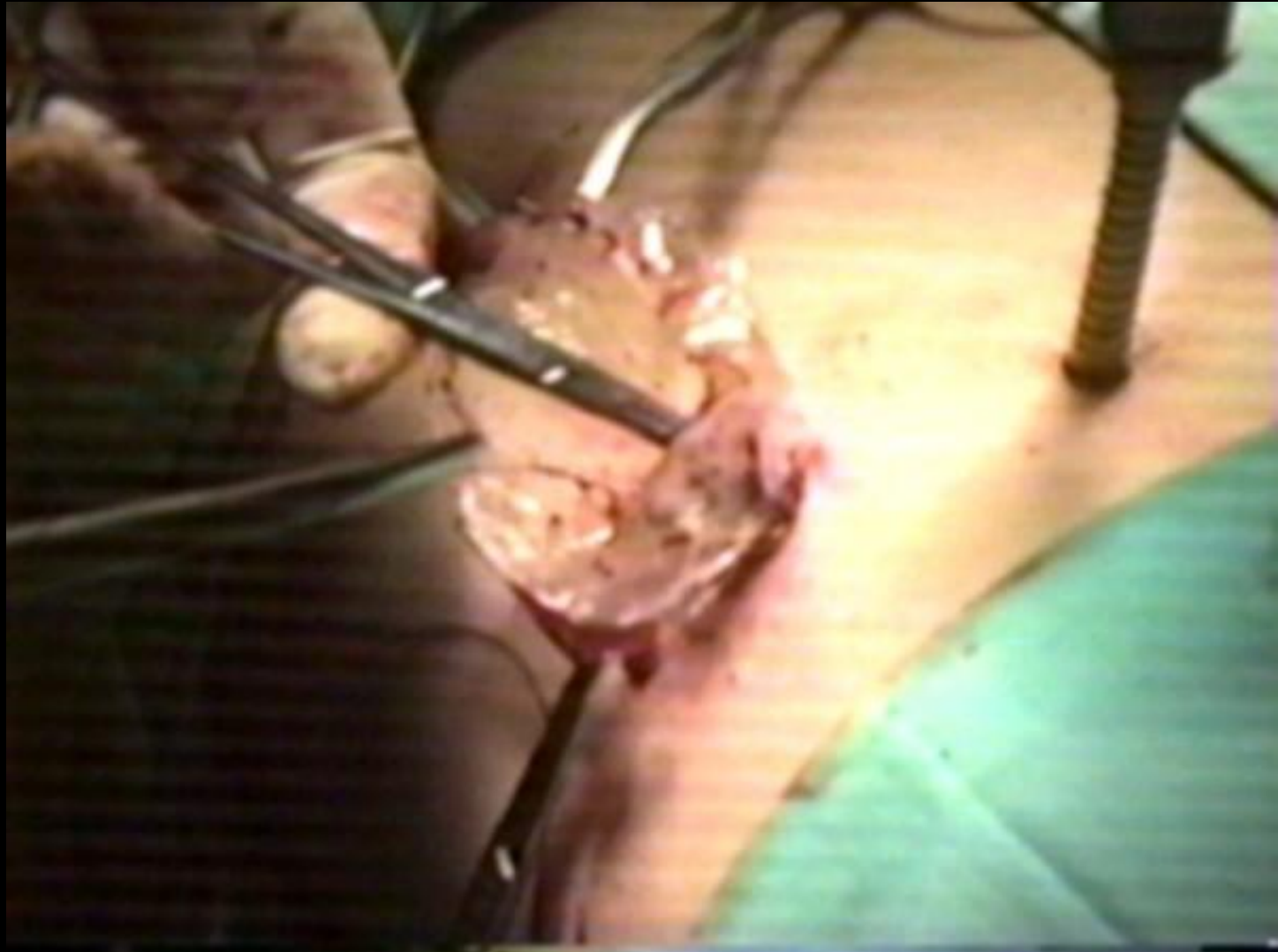
**MÚSCULO CUADRADO
LUMBAR**



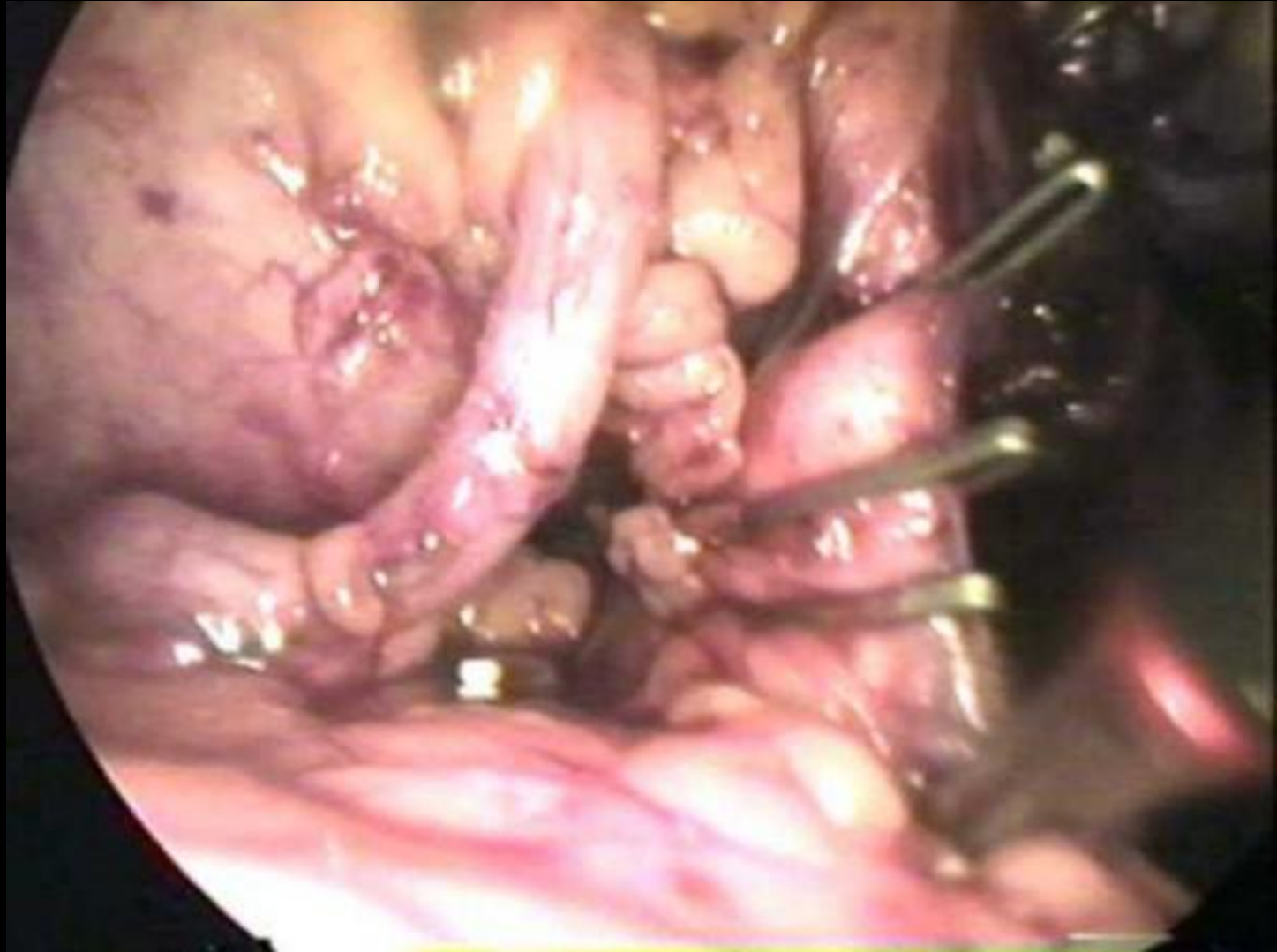NEFRECTOMIA POR LAPAROSCOPIA



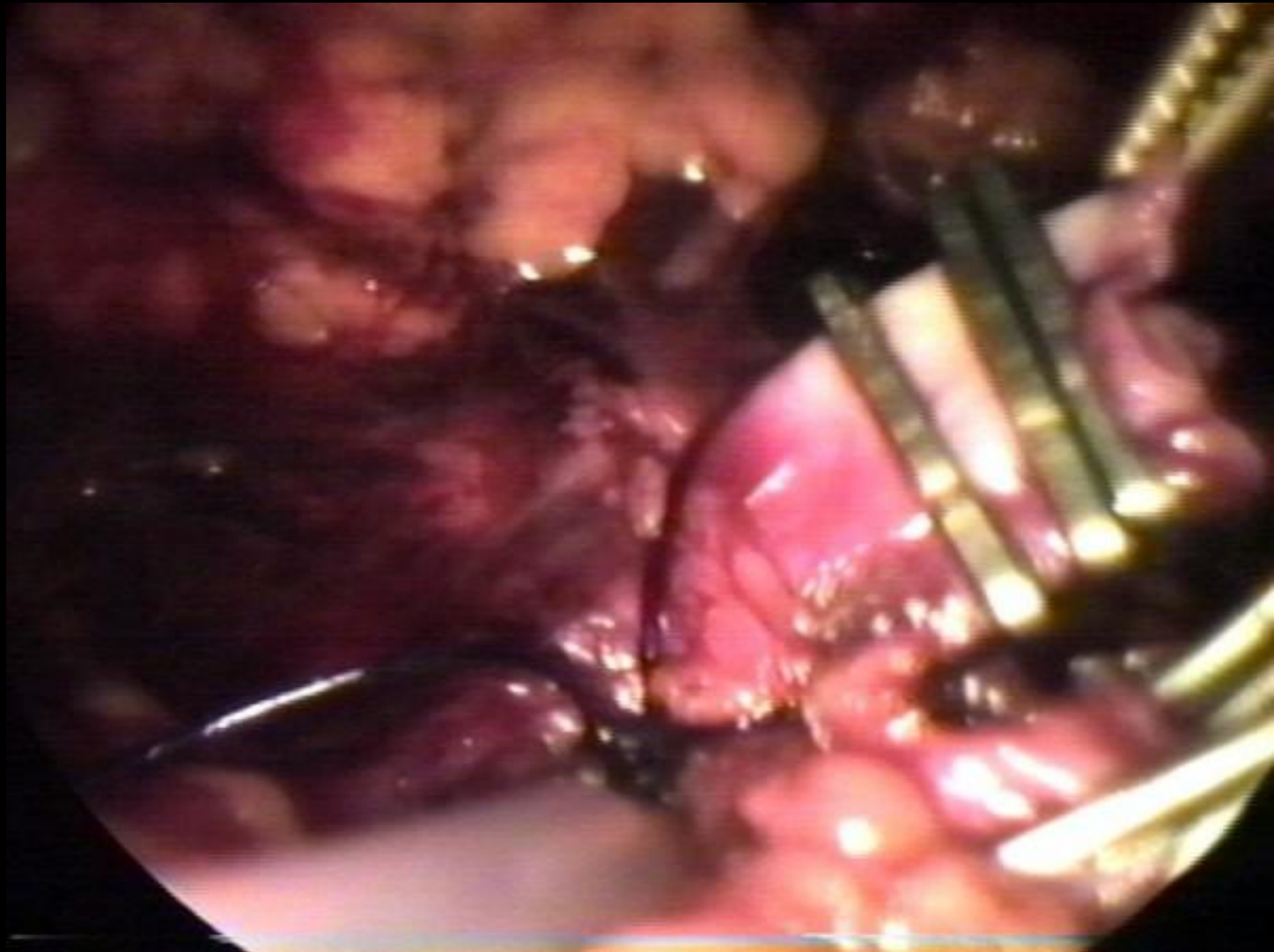
NEFRECTOMIA POR LAPAROSCOPIA



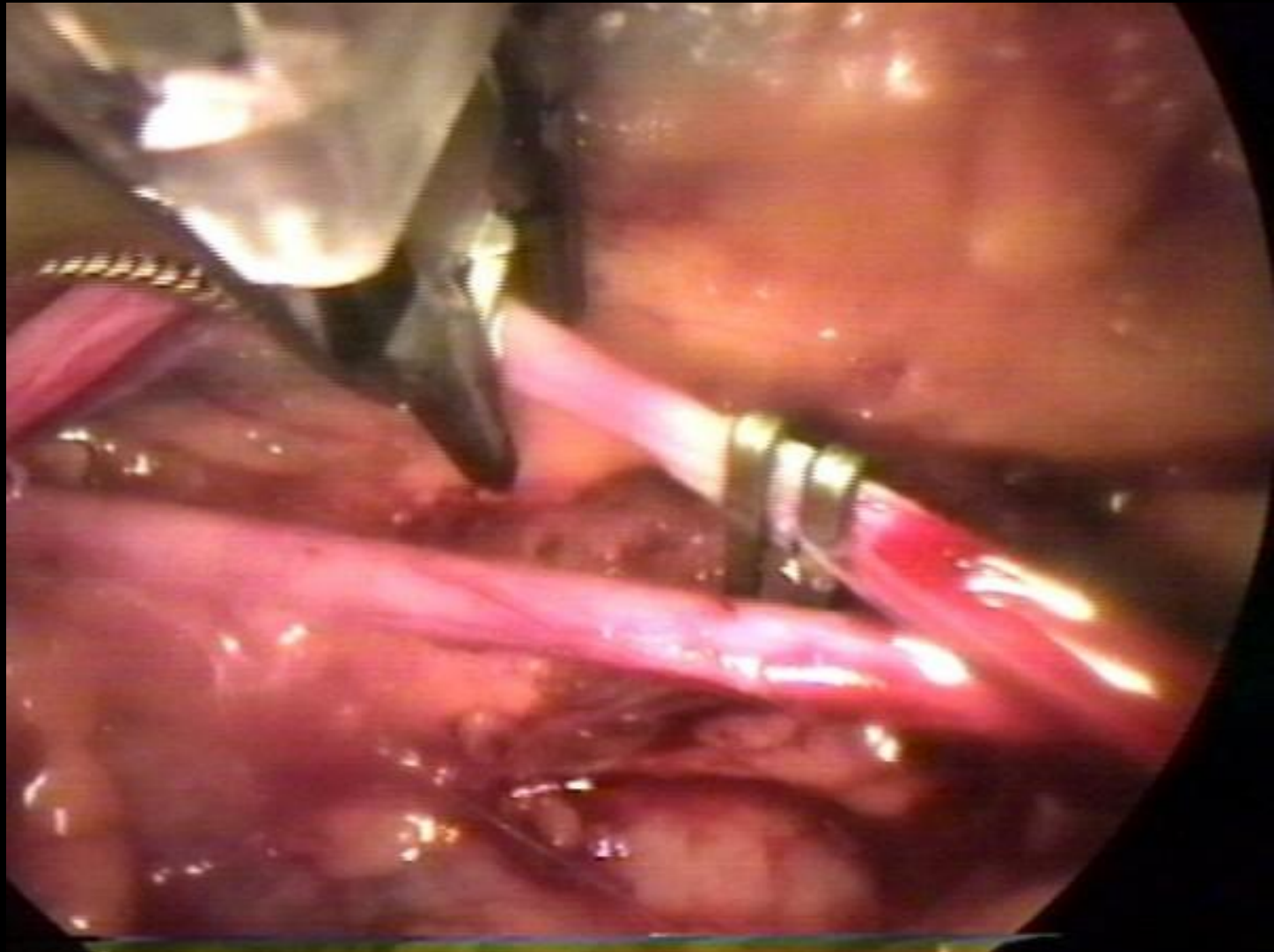
LIGADURA DE LA ARTERIA RENAL

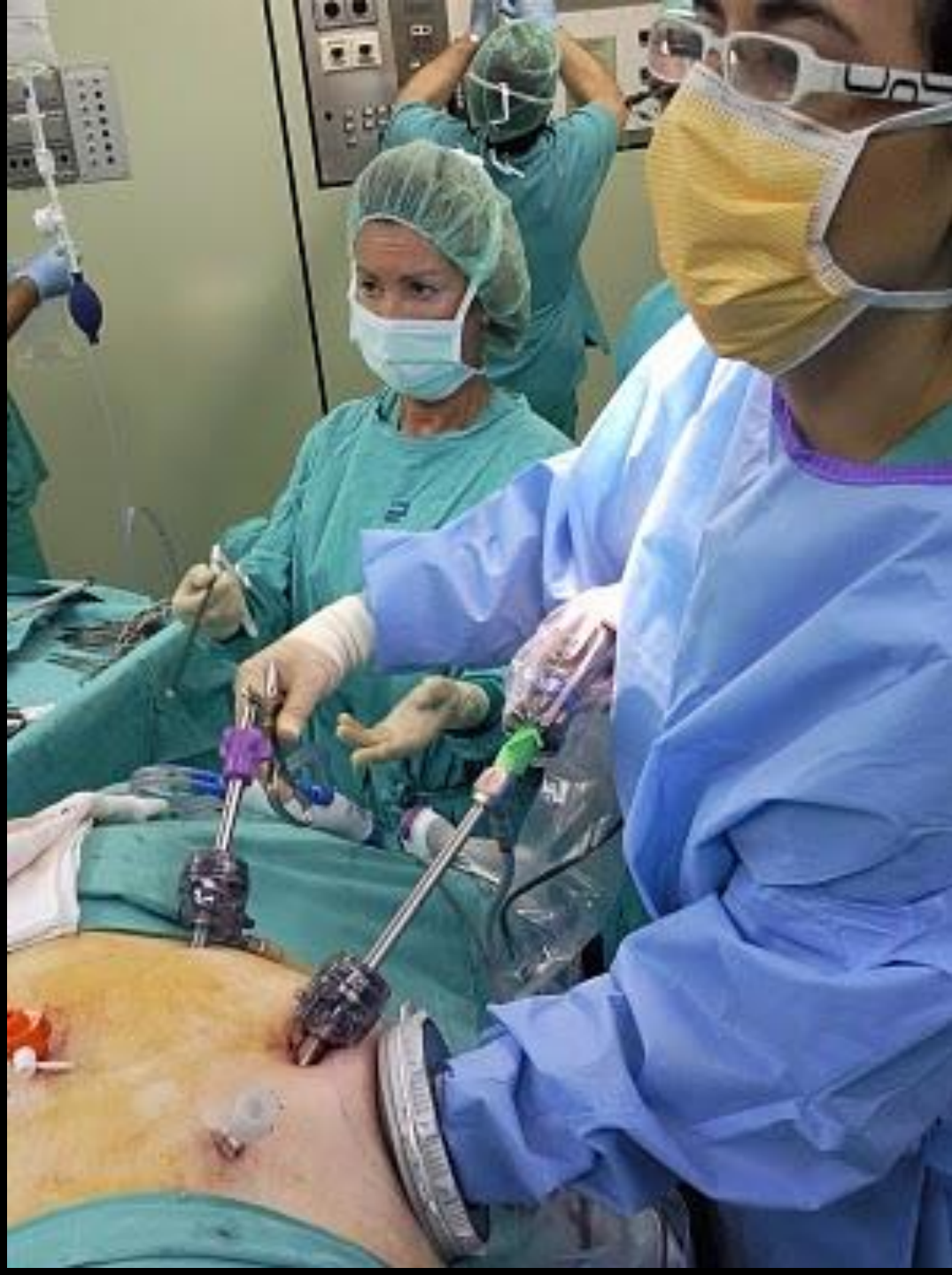

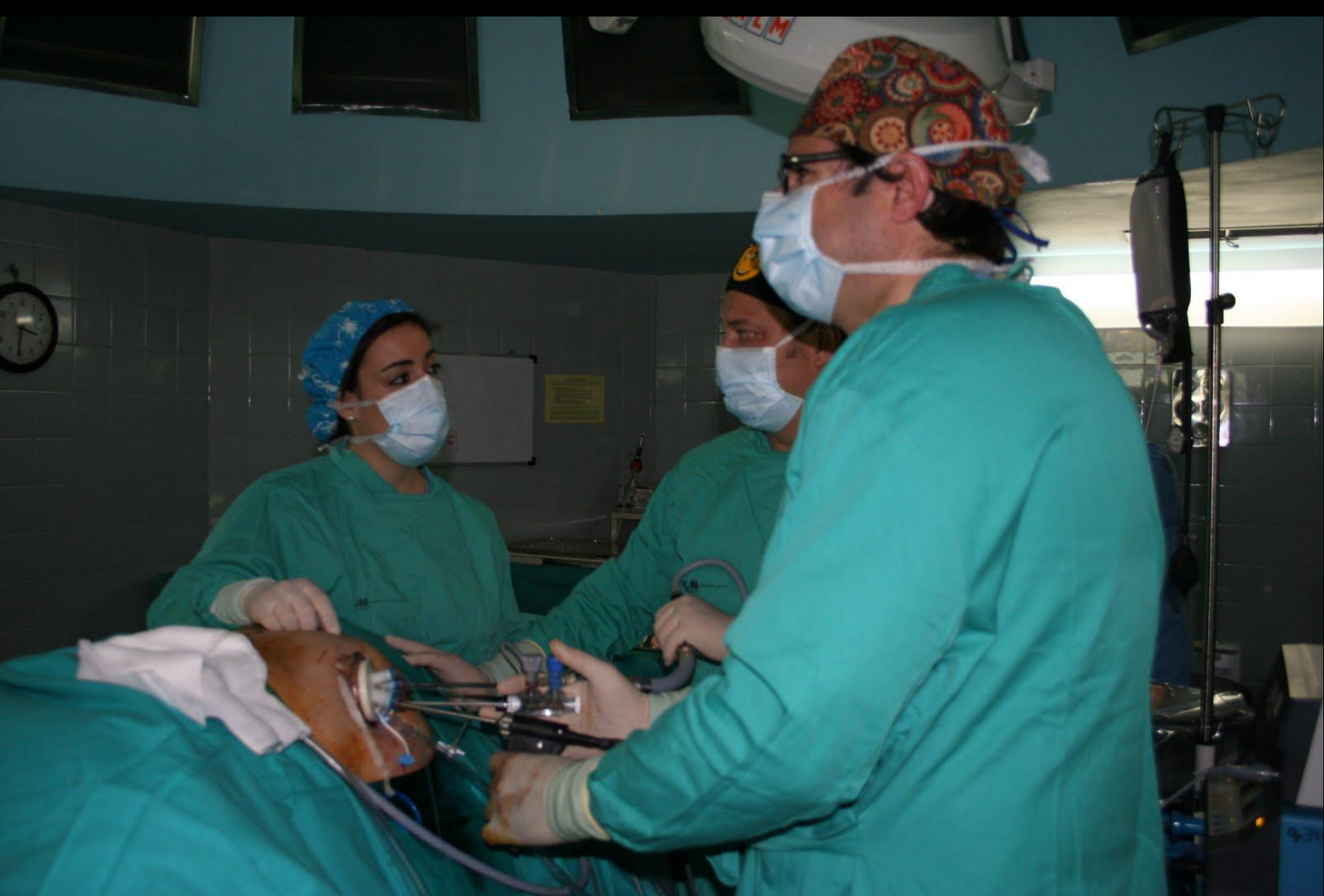LIGADURA DE LA VENA RENAL



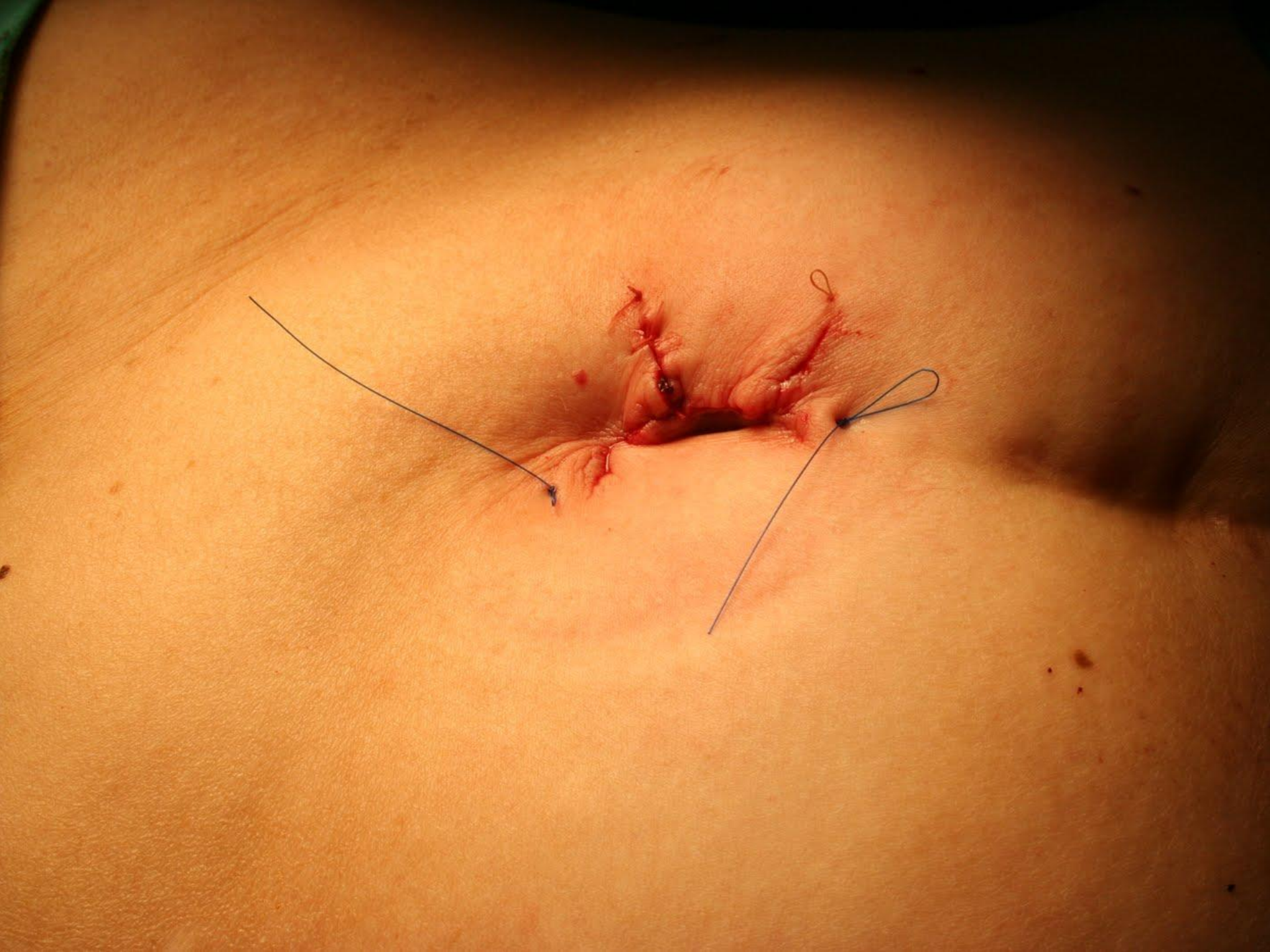LIGADURA DEL URETER

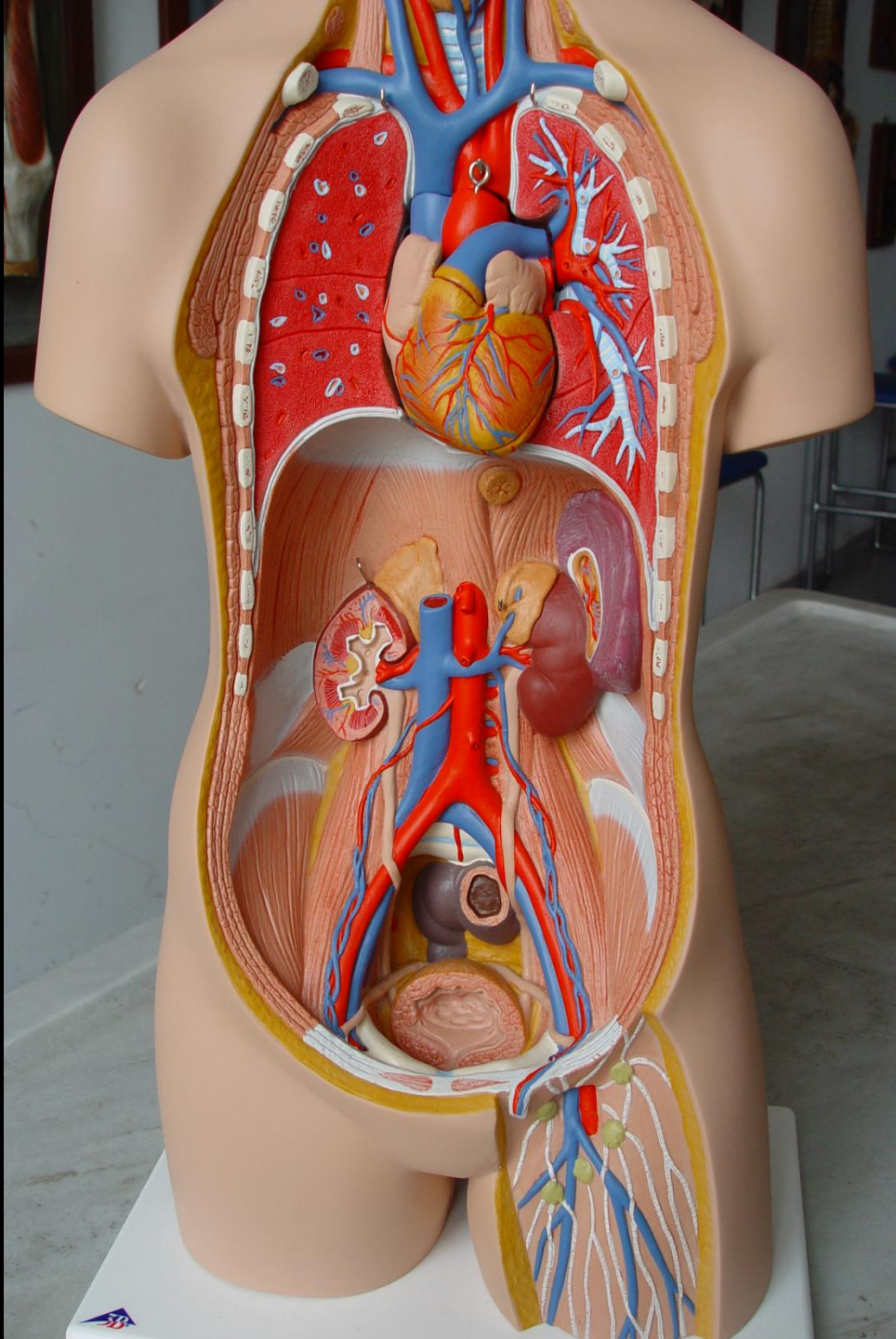






NEFRECTOMÍA RADICAL POR PUERTO UNICO

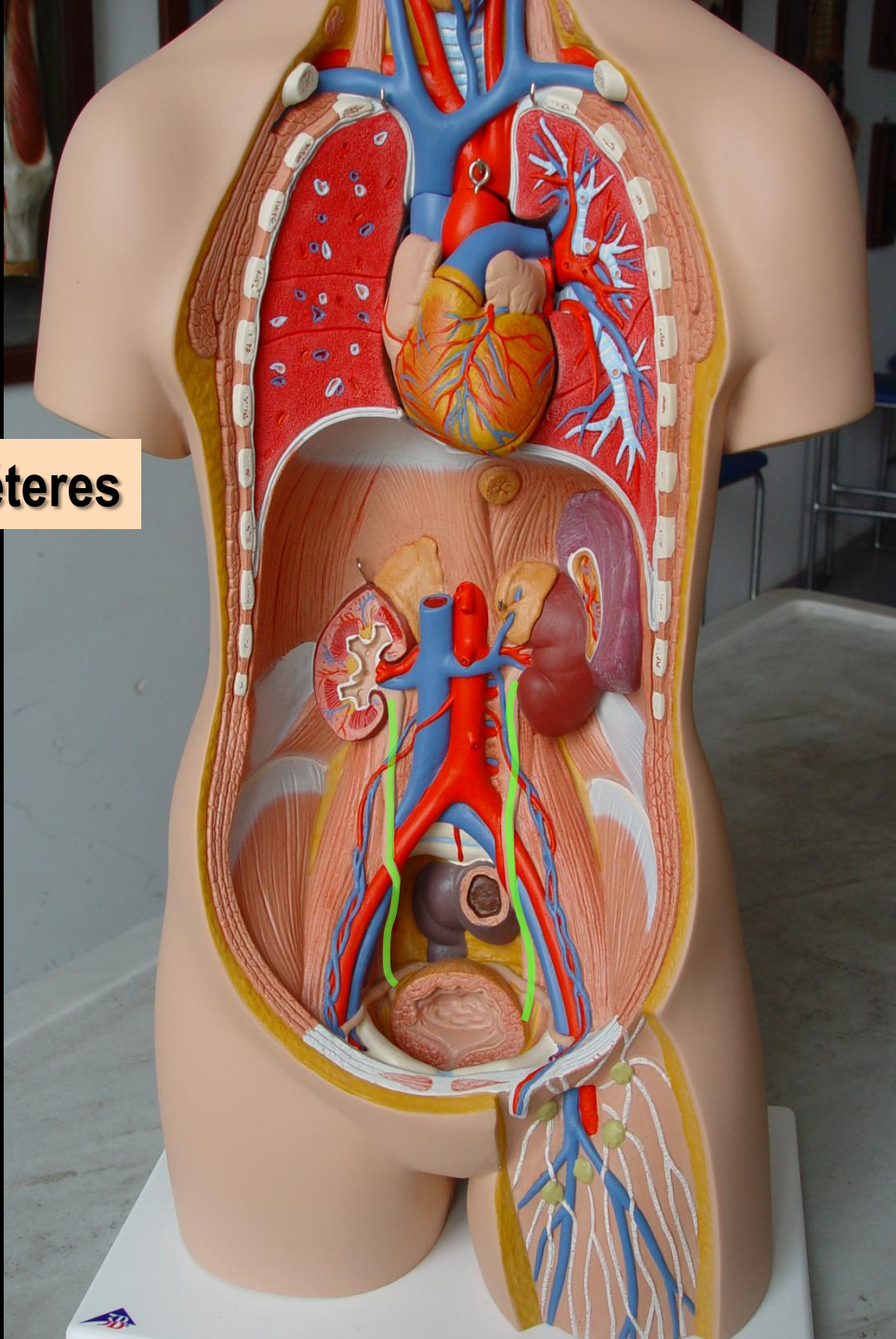




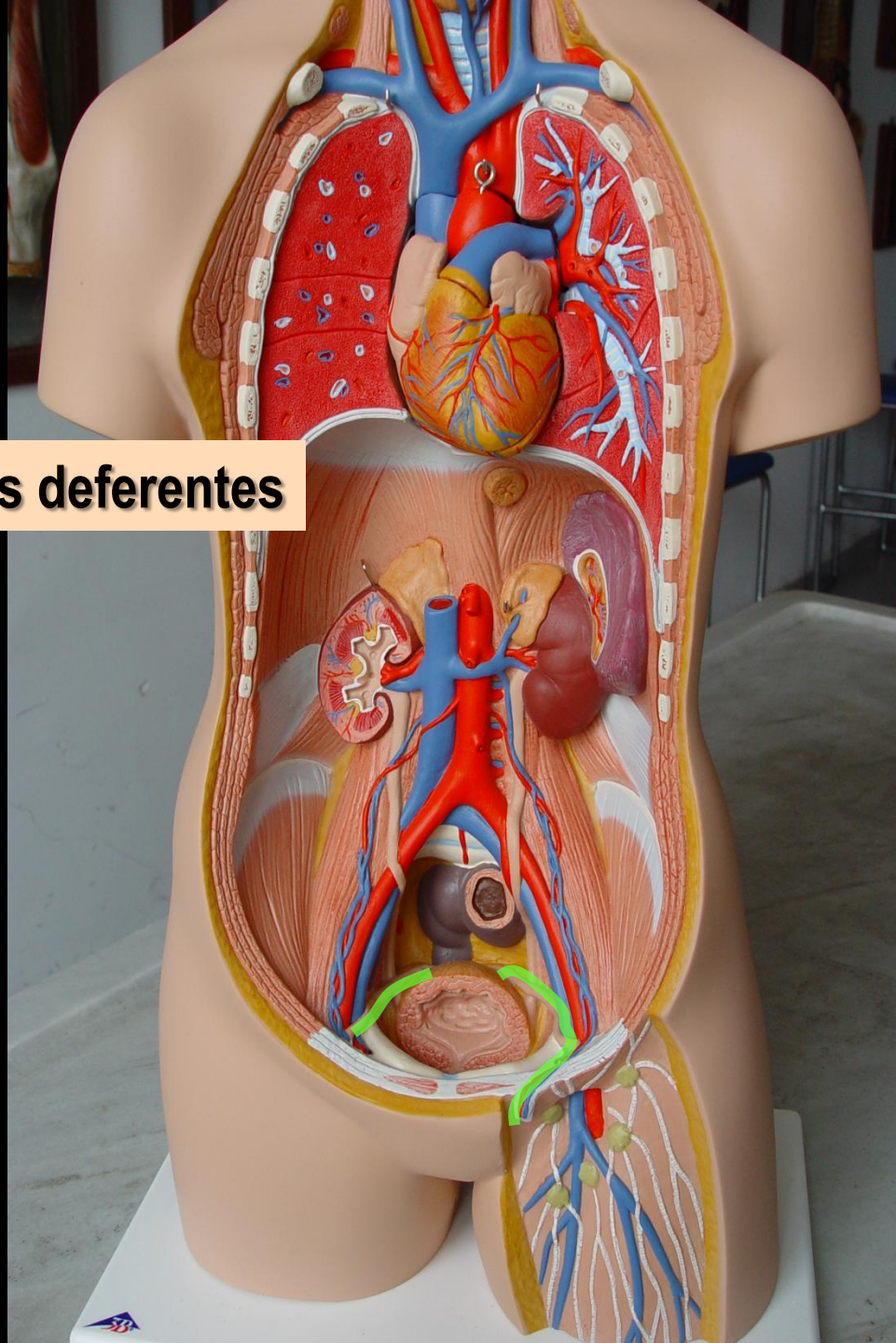
An anatomical model of the human torso, showing the internal organs and the primitive iliac arteries. The model is a light-colored, realistic-looking figure with a cutaway view of the torso. The internal organs, including the heart, lungs, liver, stomach, and intestines, are shown in various colors. The primitive iliac arteries are highlighted in red and blue, branching from the abdominal aorta and descending towards the pelvis. The model is mounted on a white base.

**Arterias iliaca
primitivas**

Uréteres



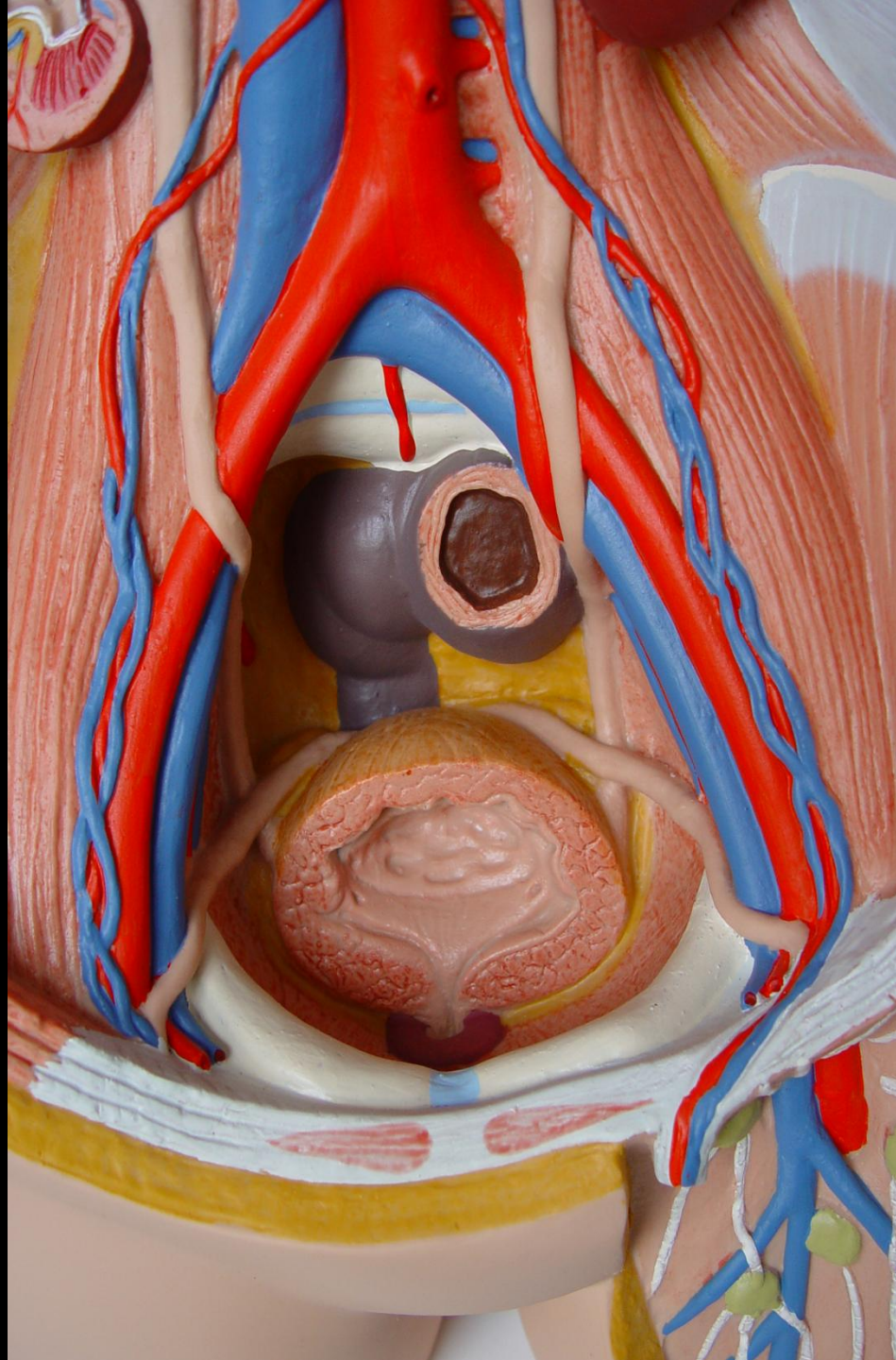
Conductos deferentes



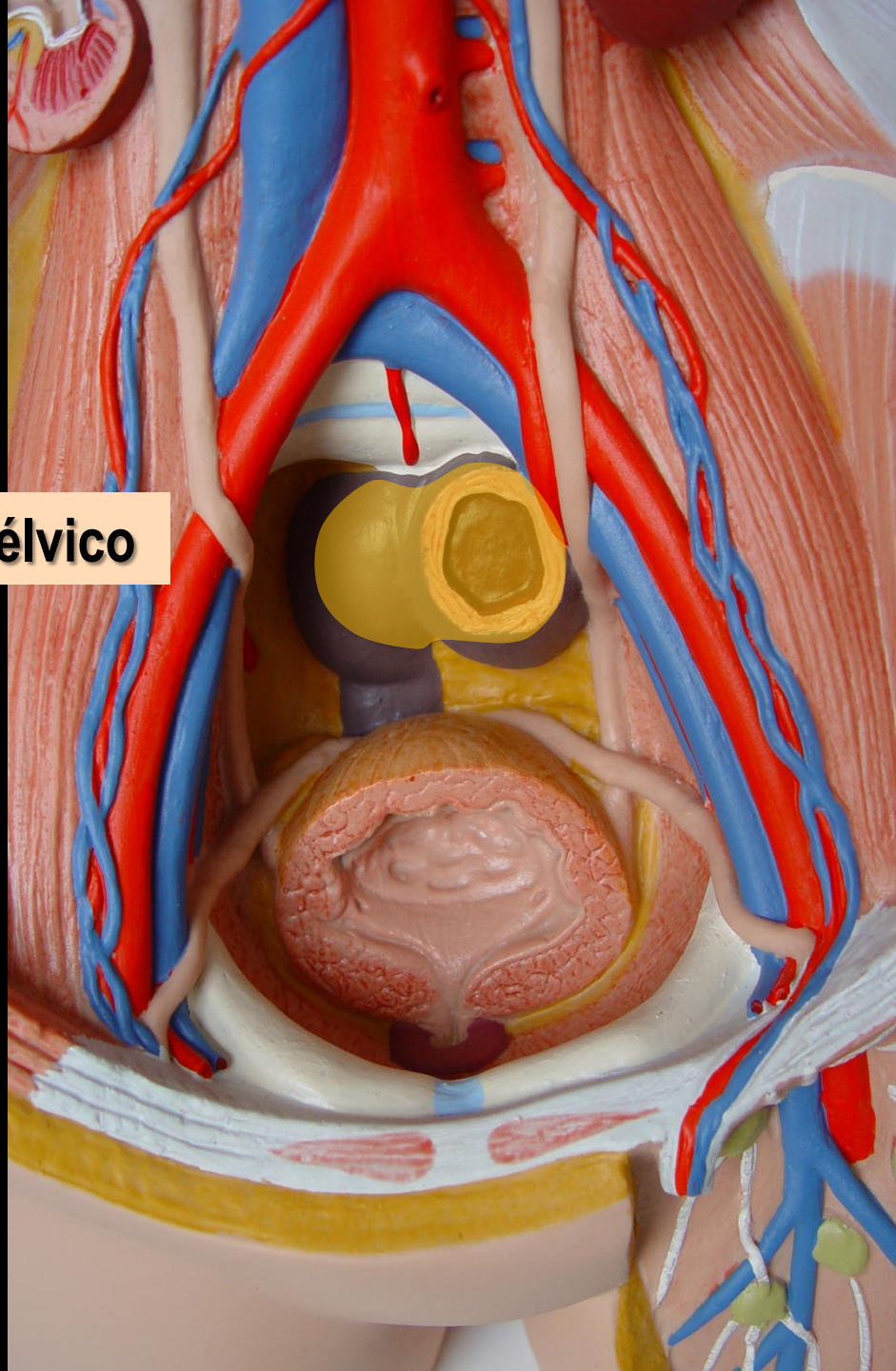
An anatomical model of the human torso, showing the internal organs and ducts. The model is cut open to reveal the abdominal cavity. The heart and lungs are visible in the upper part, and the stomach, liver, and pancreas are in the middle. The lower part shows the intestines and the reproductive system. The ducts are highlighted in green. The model is mounted on a white stand.

Conductos deferentes

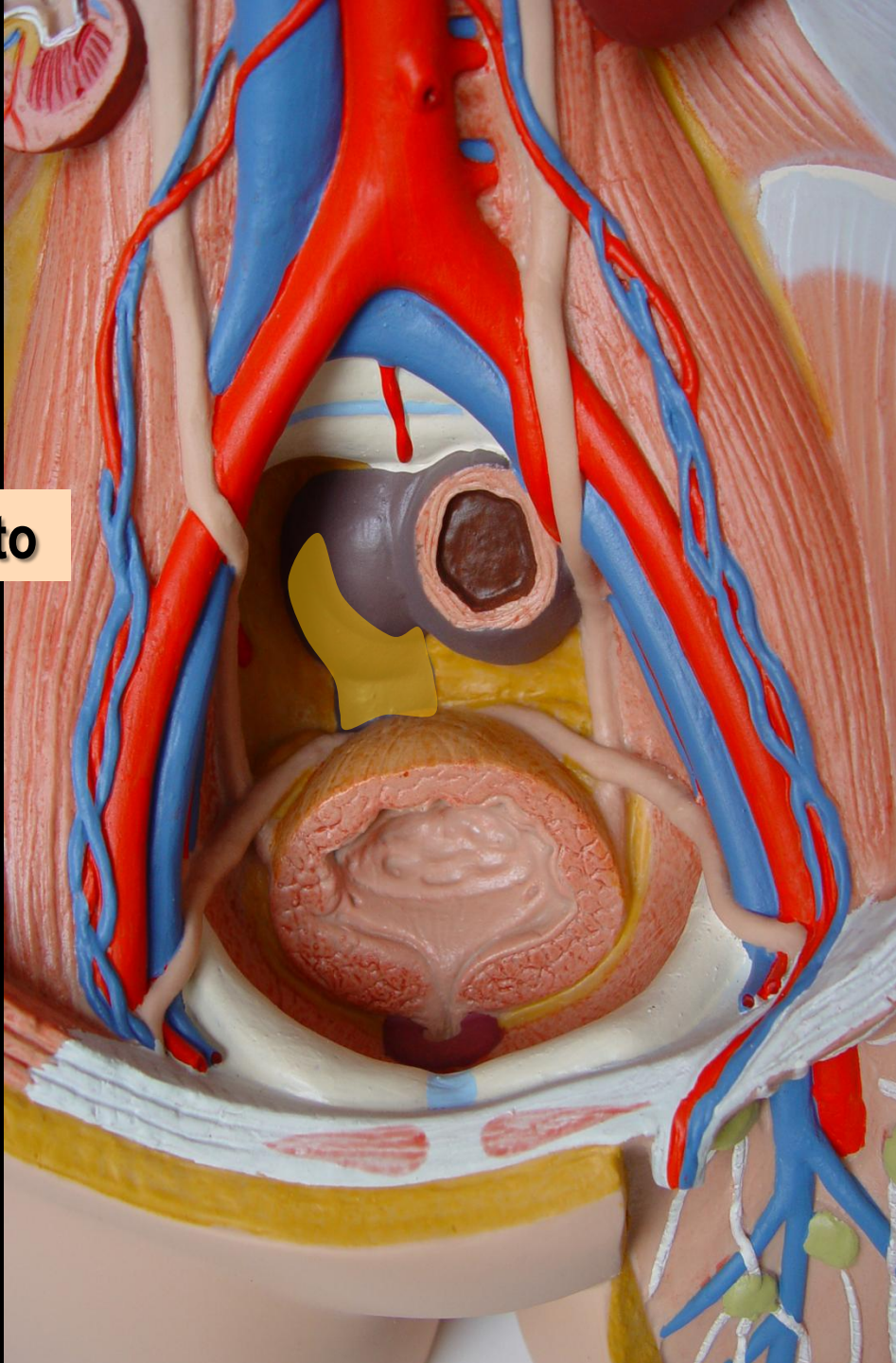
ÓRGANOS SUBPERITONEALES

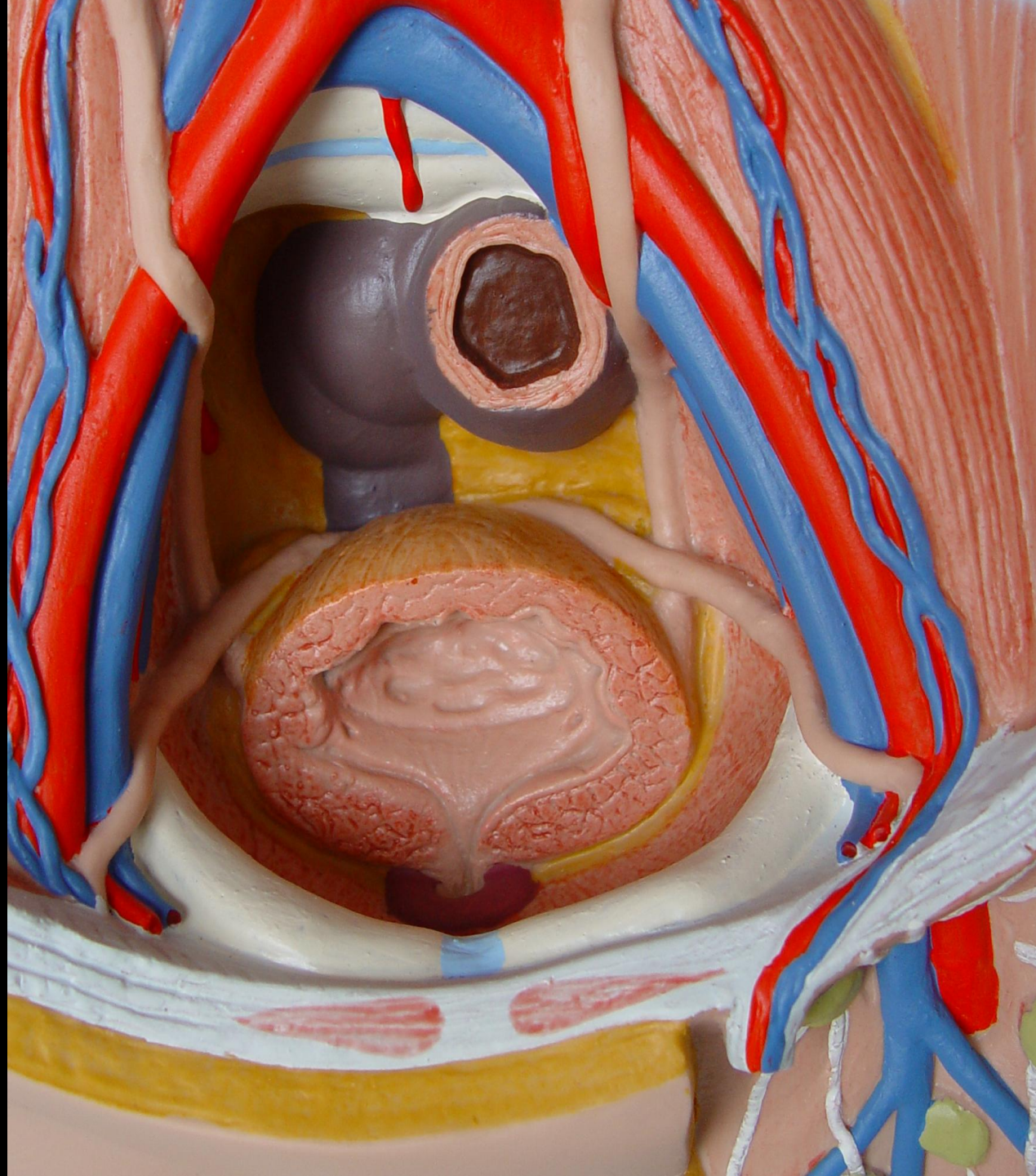


Colon pélvico

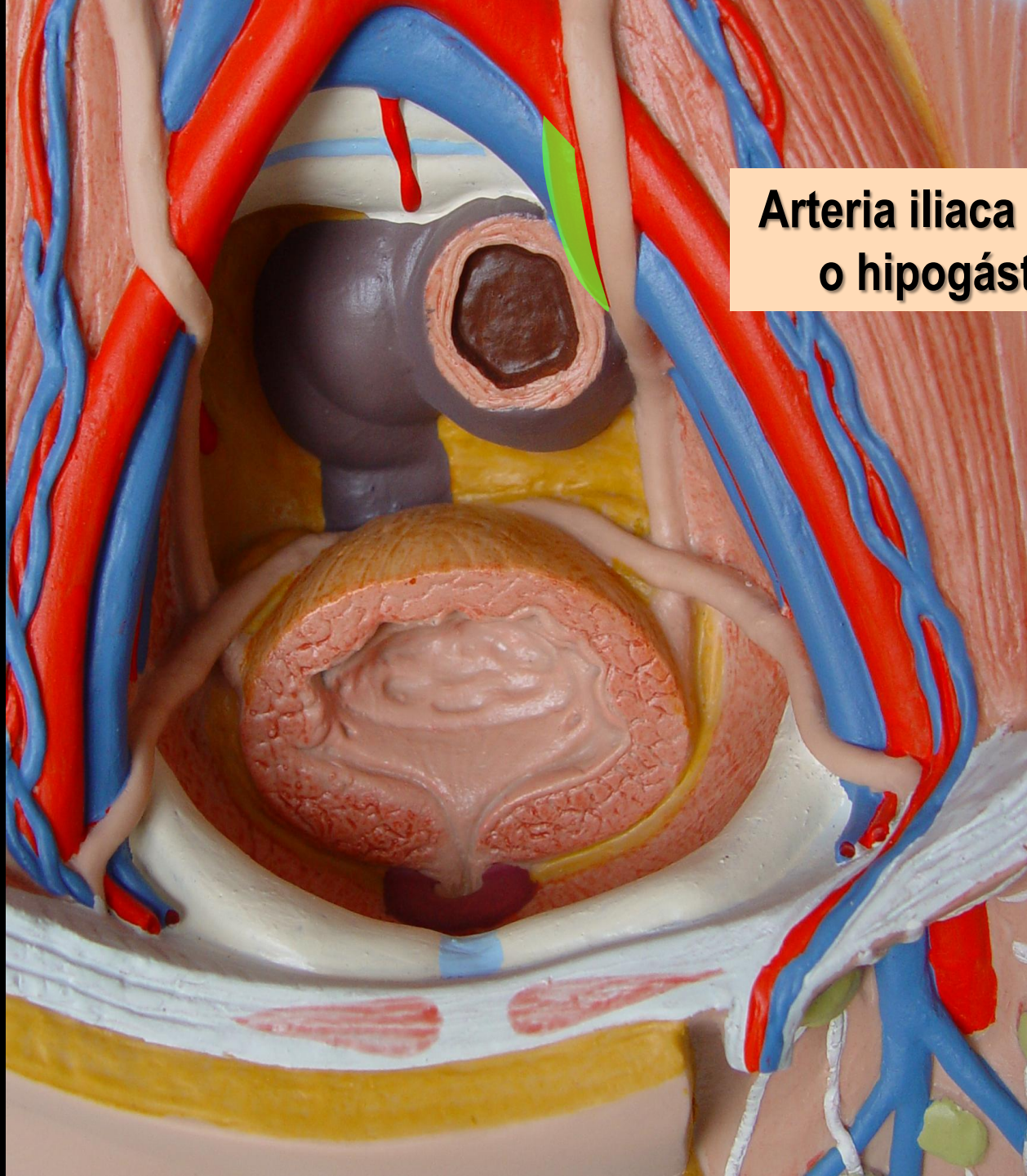

Recto

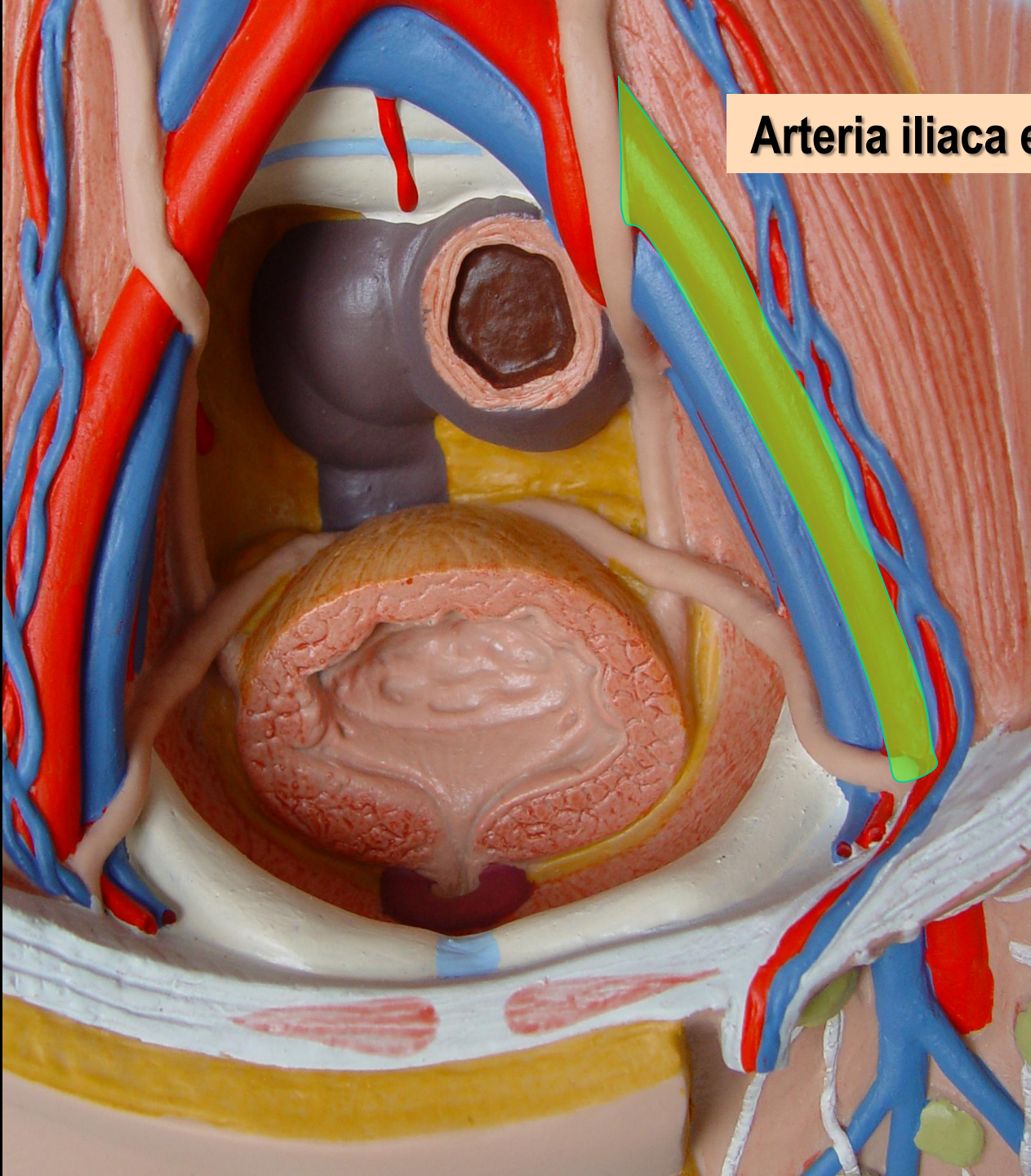


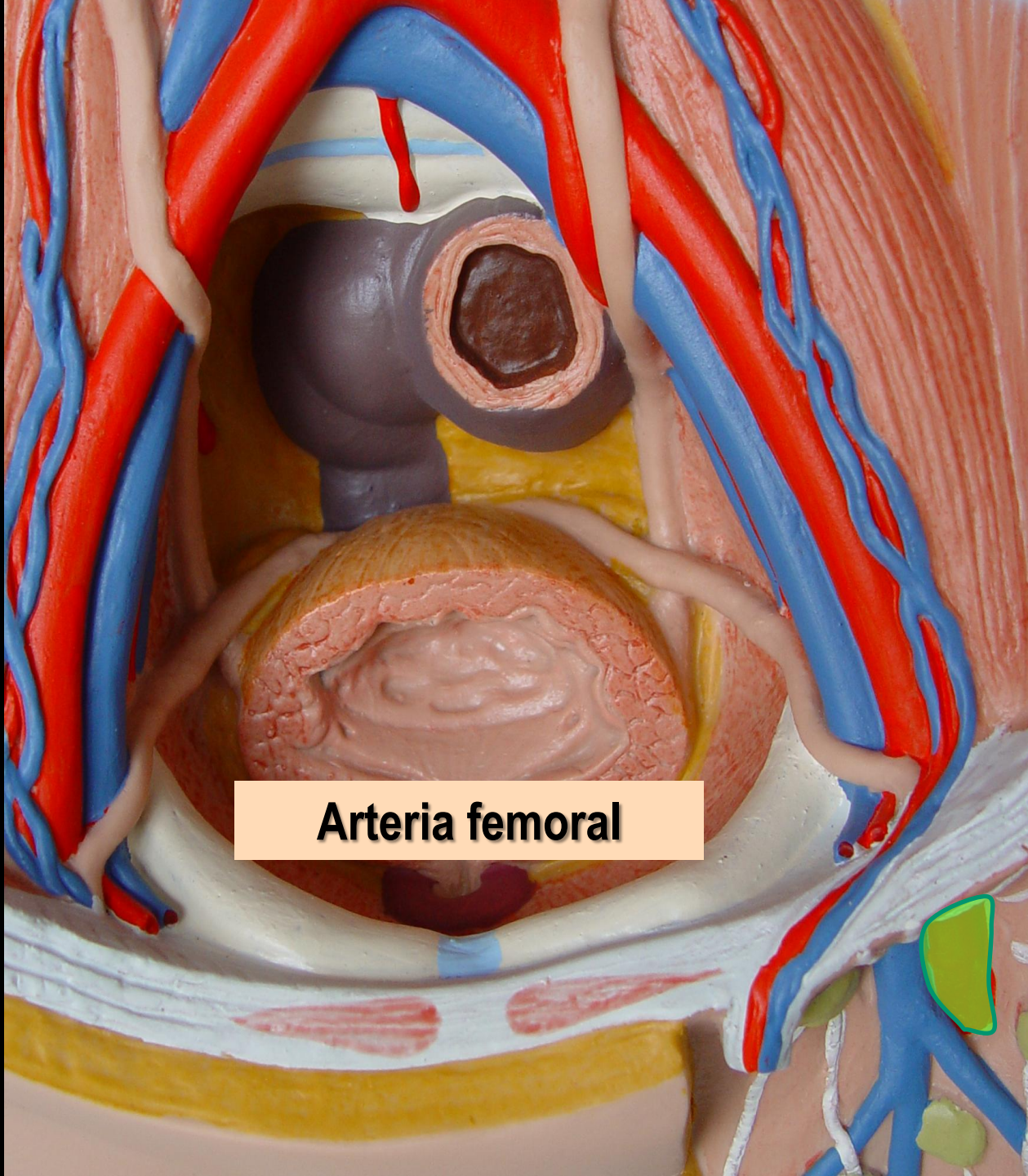


**Arteria iliaca interna
o hipogástrica**



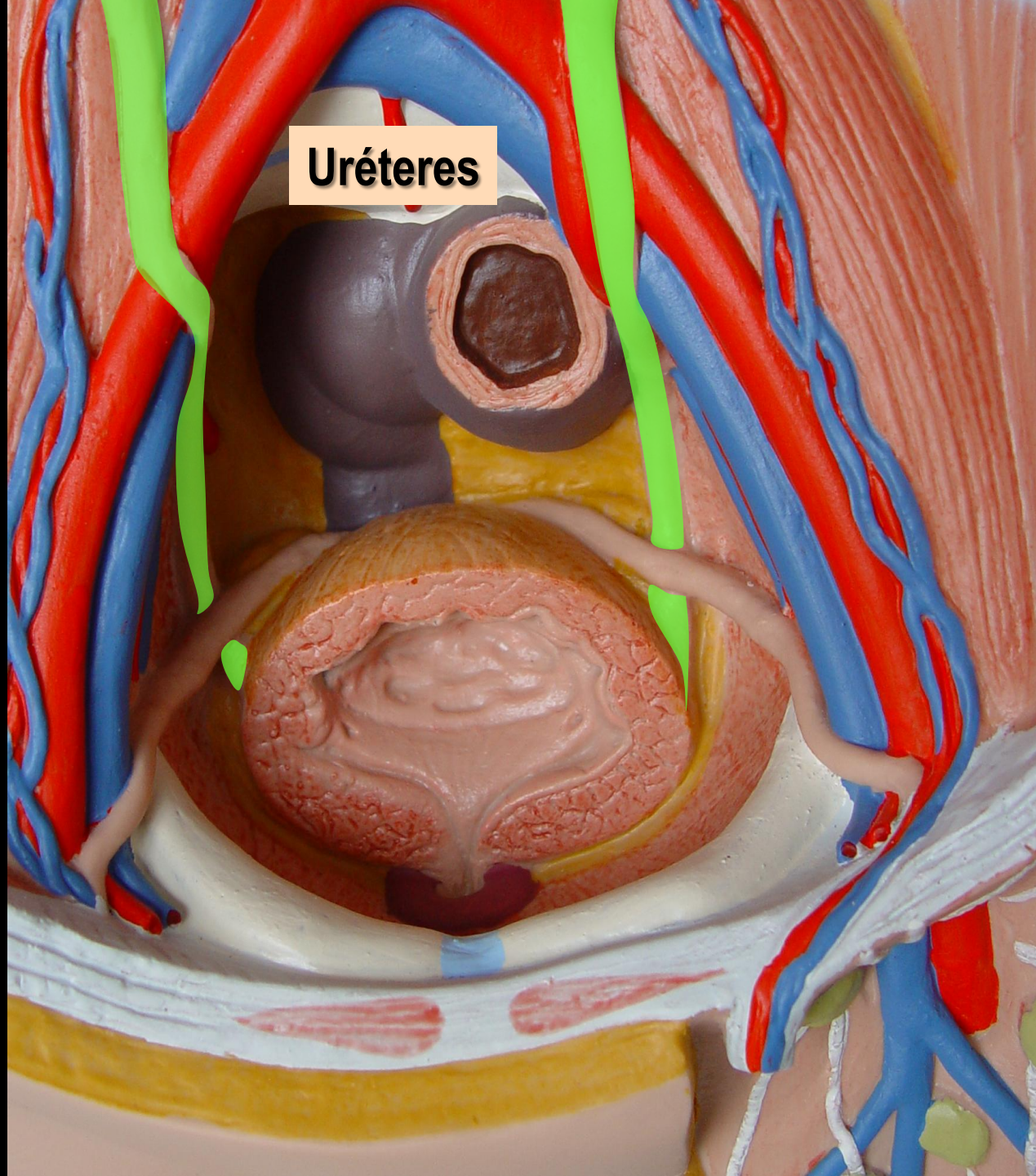
Arteria iliaca externa



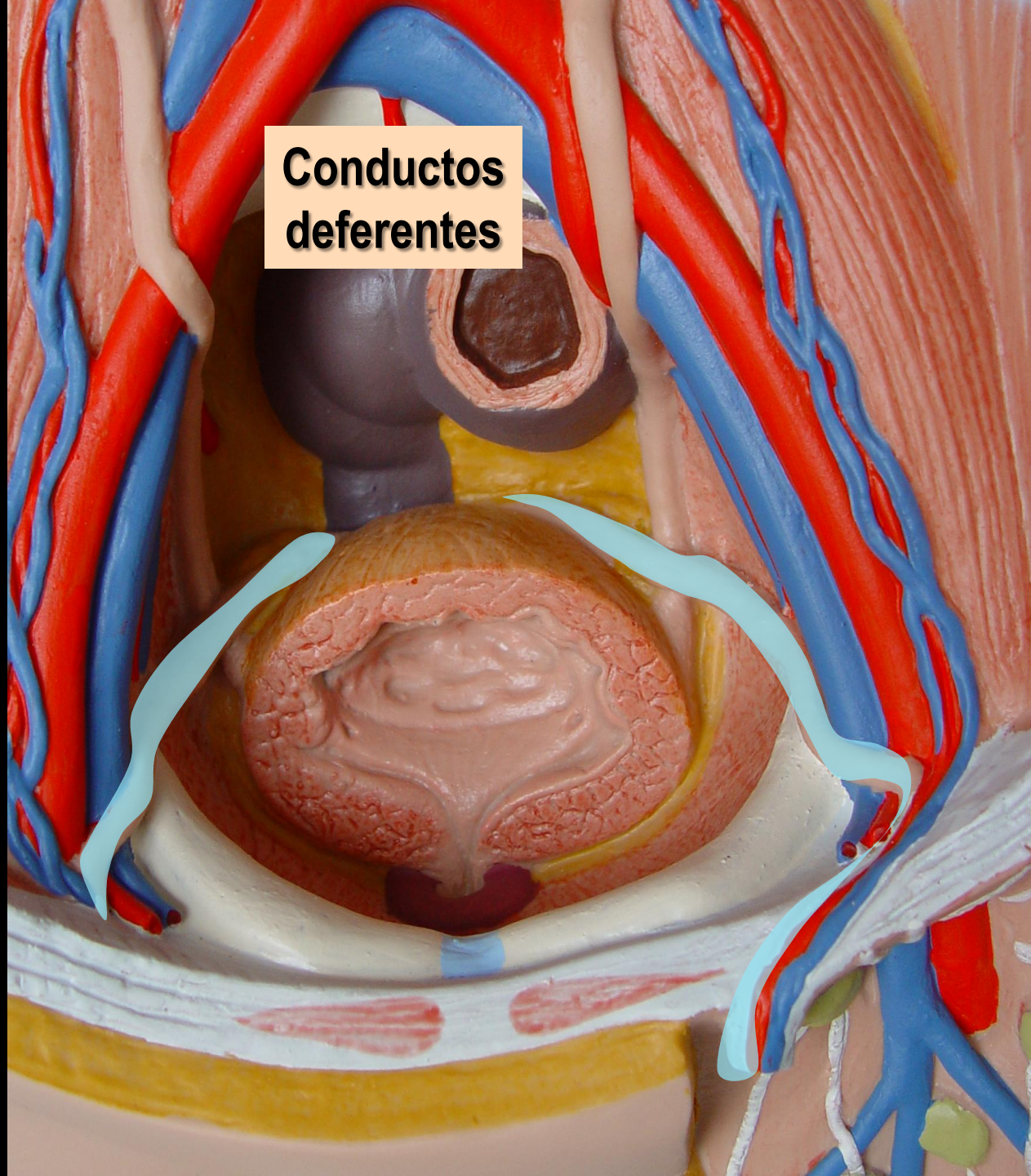


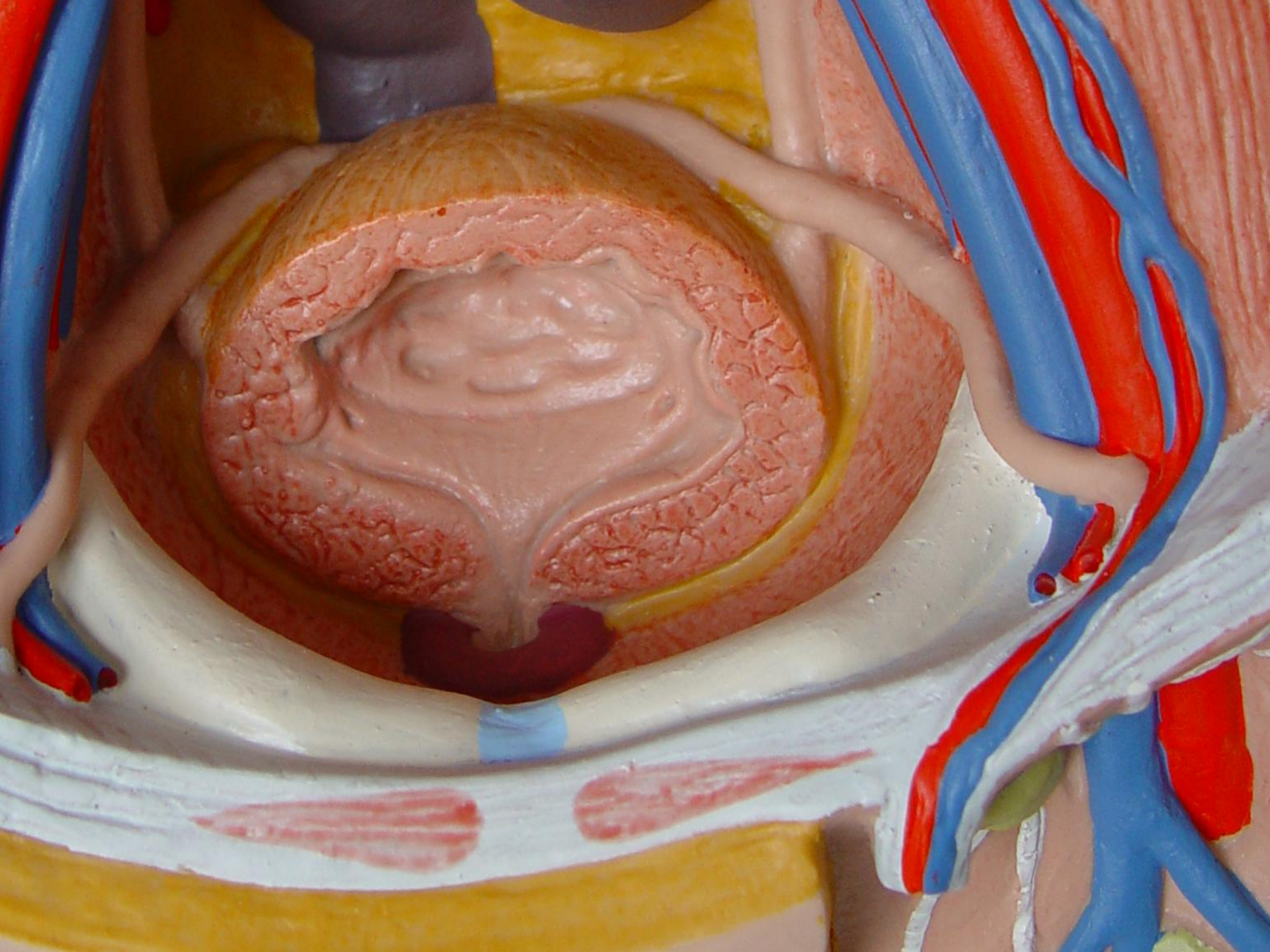
Arteria femoral

Uréteres



**Conductos
deferentes**

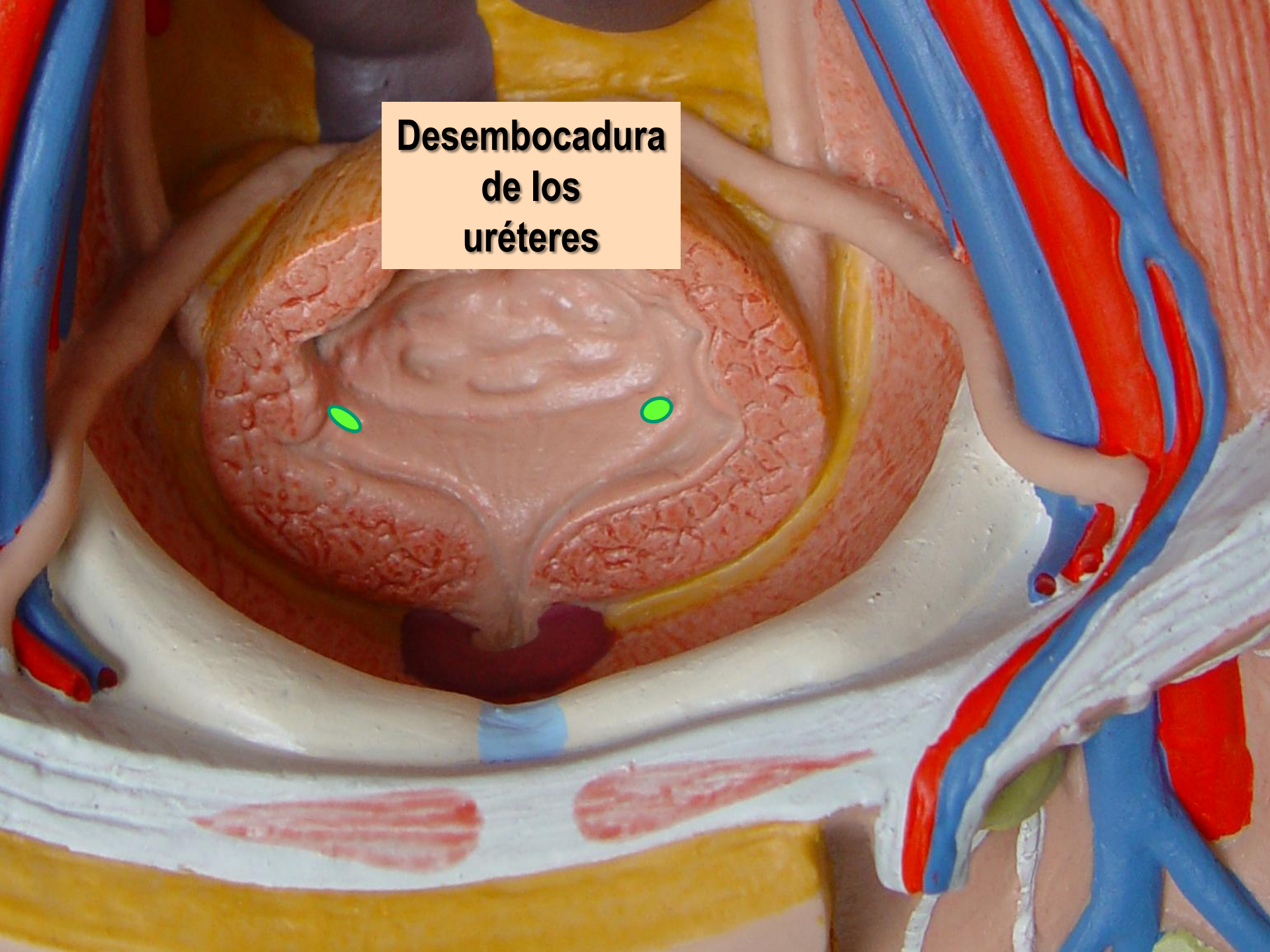




An anatomical model of the human bladder, showing its internal structure and surrounding vessels. The bladder is a large, yellow, sac-like organ with a wrinkled internal surface. It is surrounded by a network of blood vessels, including arteries (red) and veins (blue), and is situated within the pelvic cavity. The model is color-coded to distinguish between different tissues and structures.

Vejiga

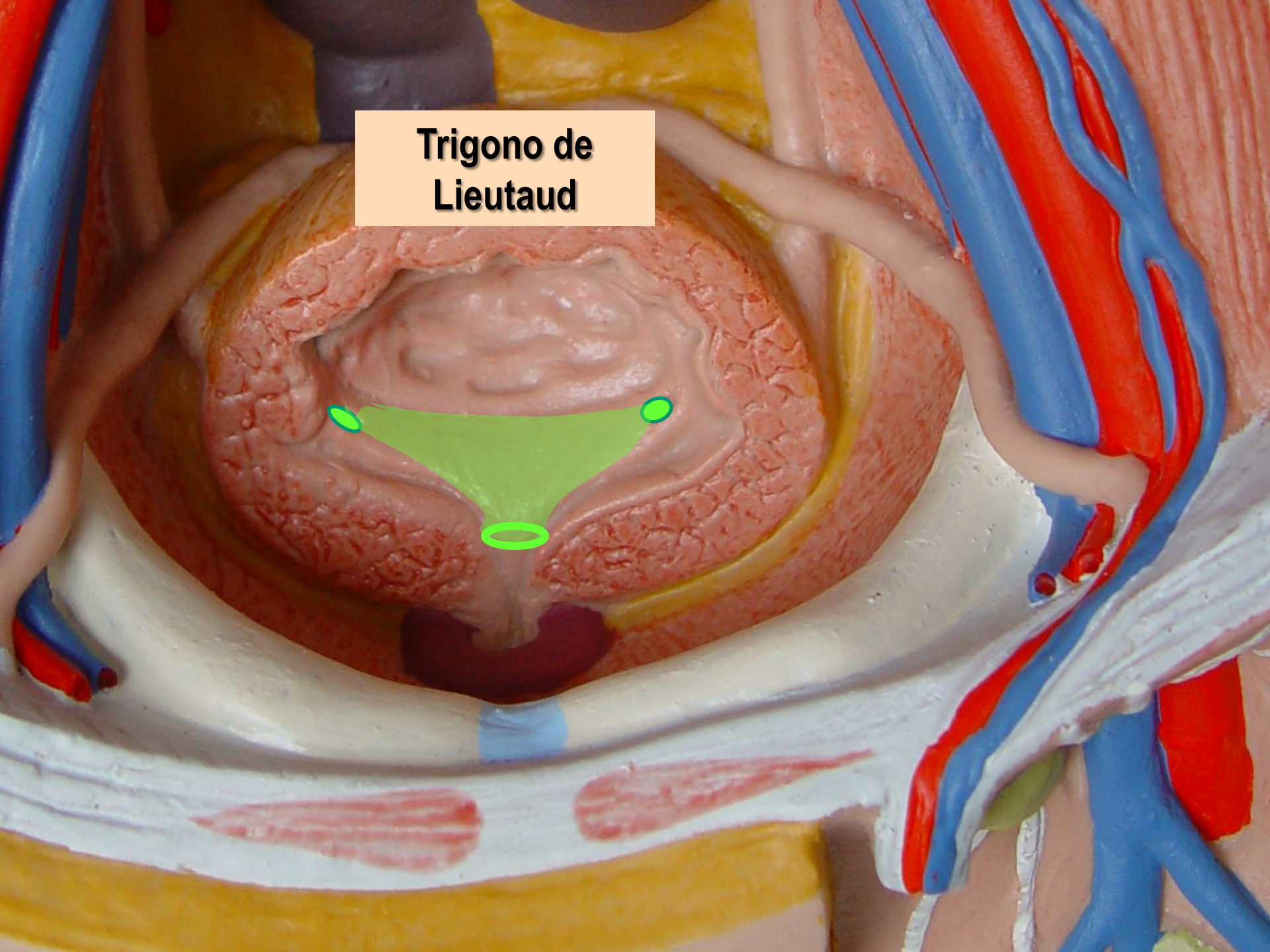
**Desembocadura
de los
uréteres**



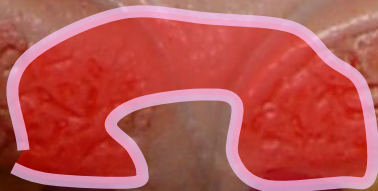
**Cuello de la vejiga urinaria
u orificio uretral interno**



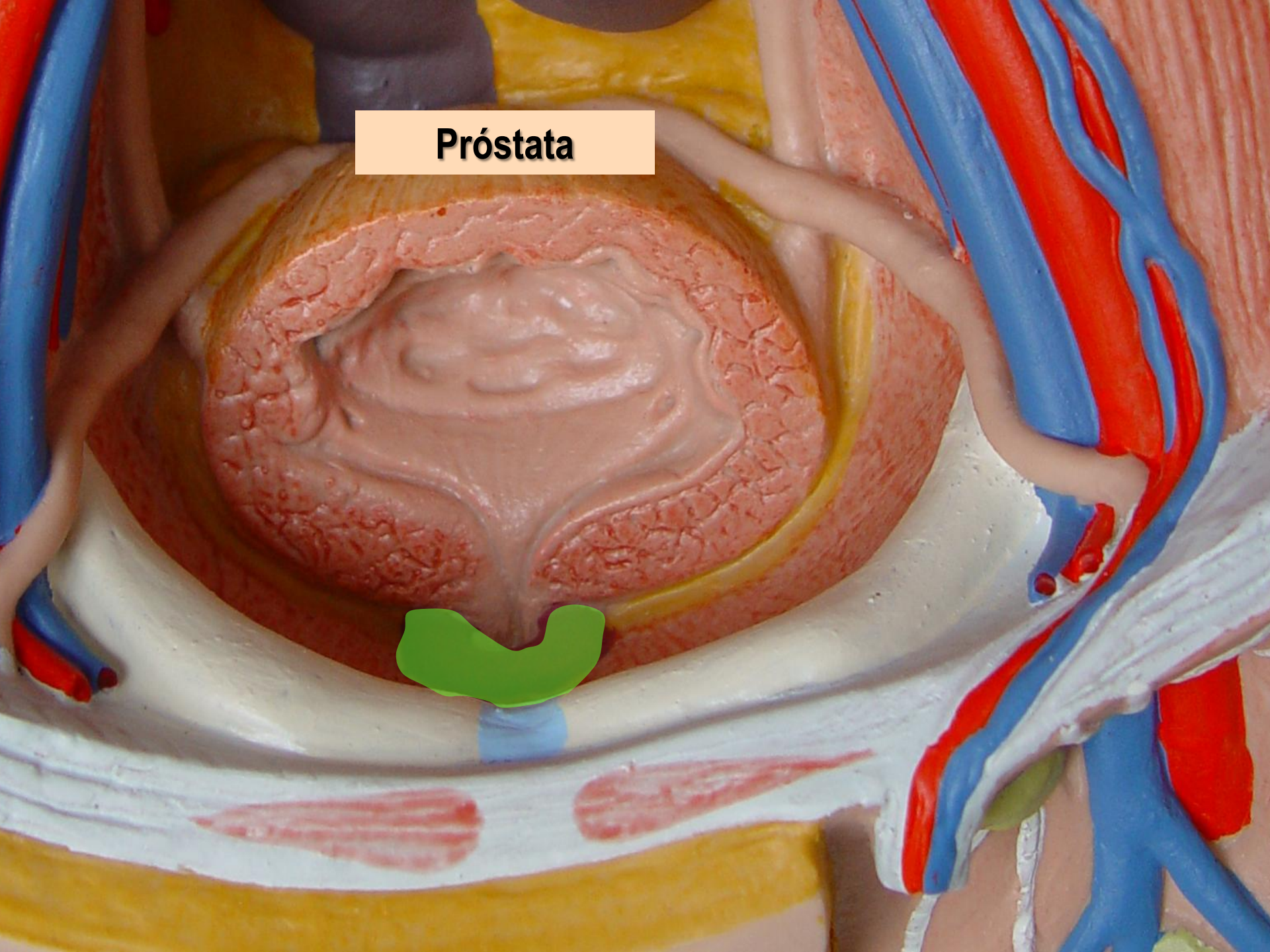
**Trigono de
Lieutaud**

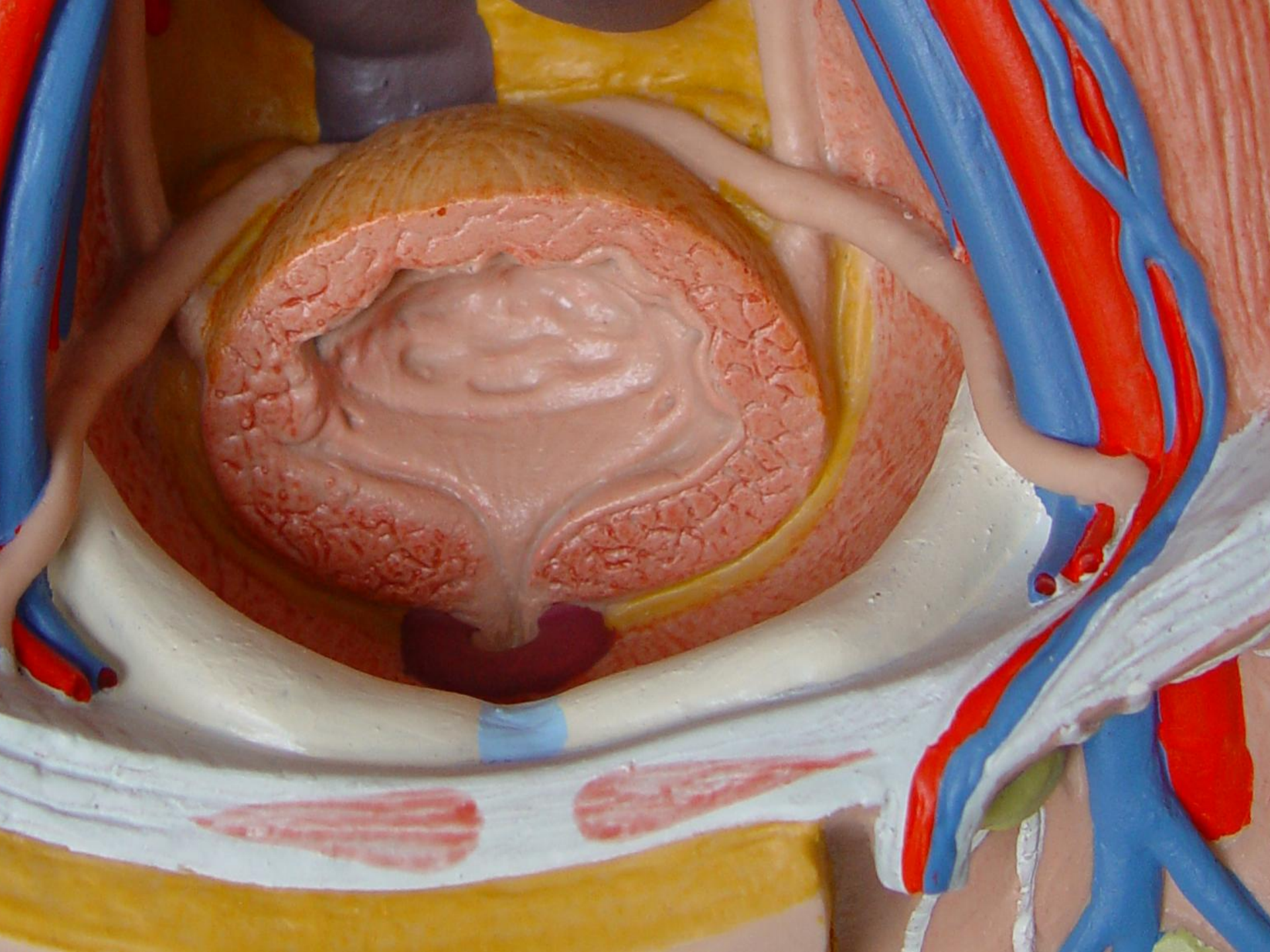


**Esfínter interno
de la uretra**



Próstata





Fin